



'08

SCIENTIFIC ABSTRACTS

HYBRID TREATMENT

*Chairmen:* Fabrizio Benedetti-Valentini, Paolo Biglioli, Tommaso Fiore

TRANS-APICAL AORTIC VALVE IMPLANTATION	Francesco Maisano Discussant: Ruggero De Paulis
ENDOVASCULAR CONTRIBUTIONS TO TREATMENT OF TYPE A AORTIC DISSECTION	Roy K. Greenberg Discussant: Francesco Siclari
CARDIAC PROTECTION IN MAJOR VASCULAR SURGERY	Luigi Tritapepe Discussant: Maria Grazia Calabrò
NEAR-INFRARED SPECTROSCOPY (NIRS) MONITORING IN AORTIC ARCH SURGERY	John M. Murkin Discussant: Luigi Beretta
HYBRID OPEN AND ENDOVASCULAR TREATMENT FOR AORTIC ARCH DISEASE	Yamume Tshomba Discussant: Maurizio Puttini
APPROACH TO RETROGRADE DISSECTION INTO THE AORTIC ARCH AND RESIDUAL DISSECTION AFTER OPEN TREATMENT OF TYPE A DISSECTION	Vicente Riambau Discussant: Guido Bajardi
ANOMALIES AND VARIANT ANATOMY OF THE AORTA AND SUPRA-AORTIC VESSELS: ADDITIONAL CHALLENGES MET BY HYBRID PROCEDURES	Carlo Setacci Discussant: Patrizio Castelli

**Francesco Maisano**

*San Raffaele Scientific Institute, Milano - Italy*

Aortic stenosis is the most frequent acquired heart valve lesion requiring hospitalization, according to Euroheart Survey. It usually occurs in the elderly and it is commonly caused by a degenerative, calcific pathology. Surgical valve replacement is the gold standard therapy for these patients, with more than five decades experience, as reflected in recent guidelines. However, in selected patients with comorbidities or advanced age, surgery remains at high risk of mortality and morbidity.

For these patients, a minimally invasive transcatheter valve implantation methodology has been developed in the last few years, to decrease the impact of open heart surgery and to eliminate the need for cardiopulmonary bypass.

Valved stents can be implanted inside a calcified aortic valve with basically three methods. The most commonly utilized is the retrograde transfemoral, followed by the antegrade transapical and the antegrade transeptal (recently abandoned).

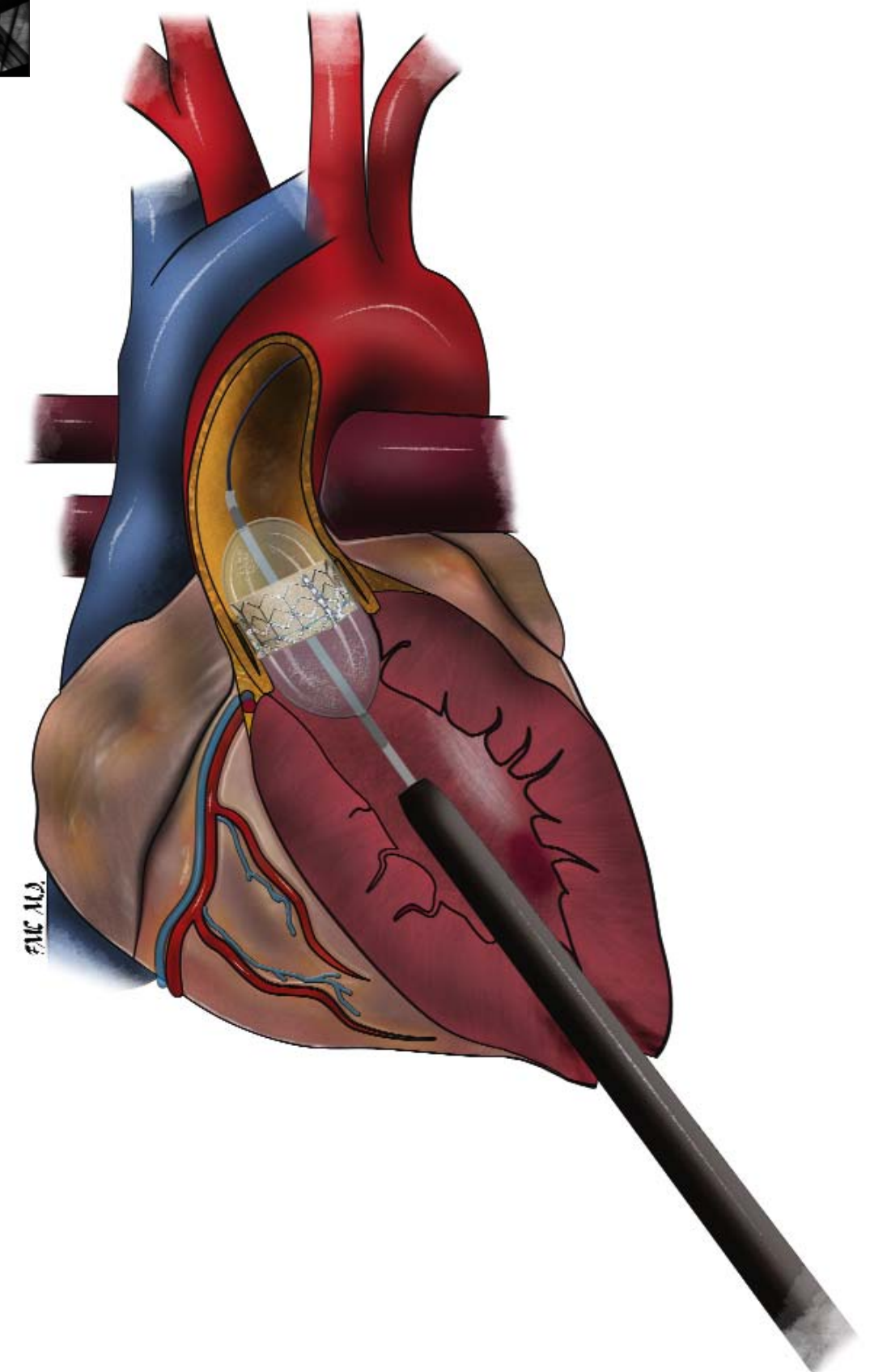
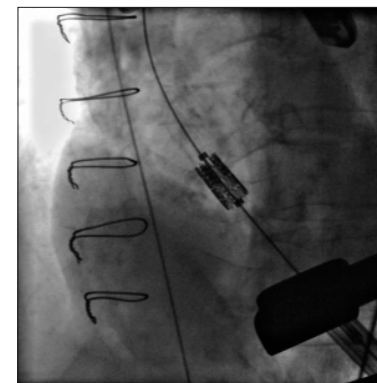
In cases with optimal iliac vessels and no atheromatous disease of the ascending aorta, the retrograde transfemoral approach offers the benefits of a truly minimally invasive procedure. However, since many elderly patients present with severe peripheral vascular disease and atheromatous disease of the ascending aorta, the antegrade transapical approach is used in about 40-50% of overall balloon expandable valve implants. The only to-date device available for transapical implant is the EDWARDS LIFESCIENCES SAPIENT THV (ASCENDRA) system, which is a stainless steel stent with a built in pericardial valve. The prosthesis is balloon expandable and is delivered using a dedicated delivery system.

The procedure is performed under general anesthesia, by a multidisciplinary team composed by the surgeon, the interventionalist, the anesthesiologist. A small anterior thoracotomy on the 5<sup>th</sup> intercostal space is performed and the apex of the heart is exposed. Femoral vessels are punctured and used for diagnostic angiograms and as a backup in case of need for percutaneous cannulae implantation is needed to establish CPB.

A purse string is confectioned in the apex, which is then punctured. The valve is easily crossed antegradely, and it is dilated with a balloon. The valve is then implanted using a dedicated delivery system during a brief period of rapid pacing to reduce the chance of valve embolization.

The position of the prosthesis is checked and the delivery system is removed. The apex is closed and the chest is closed as routine.

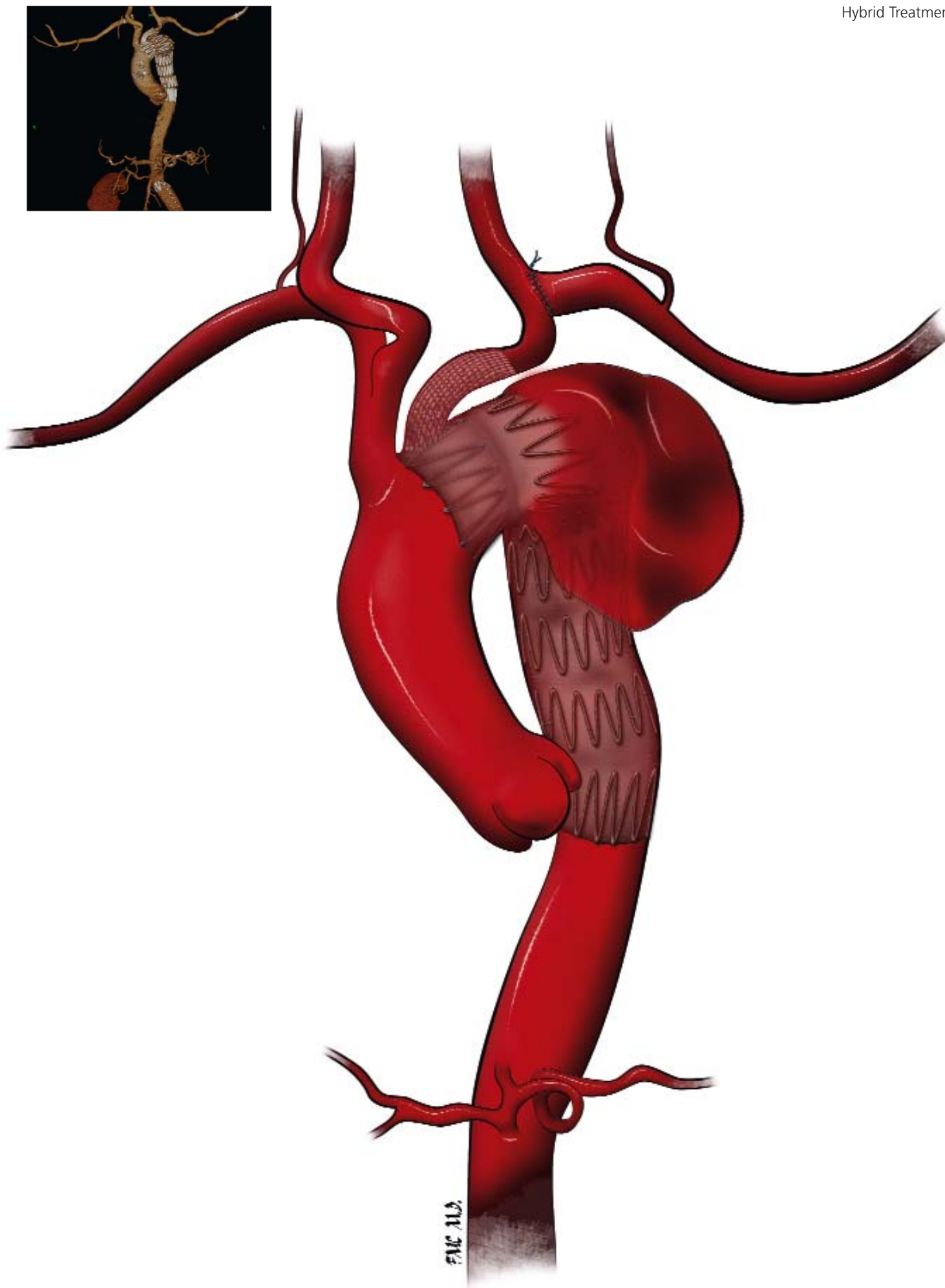
Usually the patient is weaned from mechanical ventilation on the table and transferred to the ward.



# ENDOVASCULAR CONTRIBUTIONS TO TREATMENT OF TYPE A AORTIC DISSECTION

**Roy K. Greenberg**  
*Cleveland Clinic Foundation - OH - USA*  
T.M. Mastracci, R.K. Greenberg

Endovascular treatment of the aortic arch has developed slowly because of the complex characteristics intrinsic to arch anatomy. These characteristics include the 270° curvature, variable rotational anatomy and diameter of the supra-aortic trunks, close proximity of the aortic valve and coronary ostia, and wide variability of etiologies that warrant intervention in this aortic segment. These characteristics will impact on design of useful devices, but also on the design of the delivery system, and the conduct, timing and indications of the intervention. Published endovascular series involving arch and ascending aortic pathology has largely involved hybrid procedures that are extraanatomic, or are staged and involve a preliminary invasive step. The published experience of pure endovascular repair for disease involving the arch is limited and experimental. Acute type A dissection is an indication for surgical intervention because of potential for deterioration after valvular involvement, coronary involvement, rupture or death, but the role of endovascular repair in both the acute and chronic setting has been limited by the inadequacy of current thoracic devices. The presence of concurrent descending thoracic or abdominal aortic involvement and the innovation of new devices that accommodate the ascending aorta and arch are 2 scenarios where the endovascular approach can be used and has been reported in type A dissection. It is becoming clear that any approach to the aorta requires a clear vision of potential future needs and a recognition of 'vulnerable aorta' that is prone to dilation in the future. This talk will review ascending aortic dissection and explore the evolving role of endovascular intervention in this territory.



Hybrid Treatment

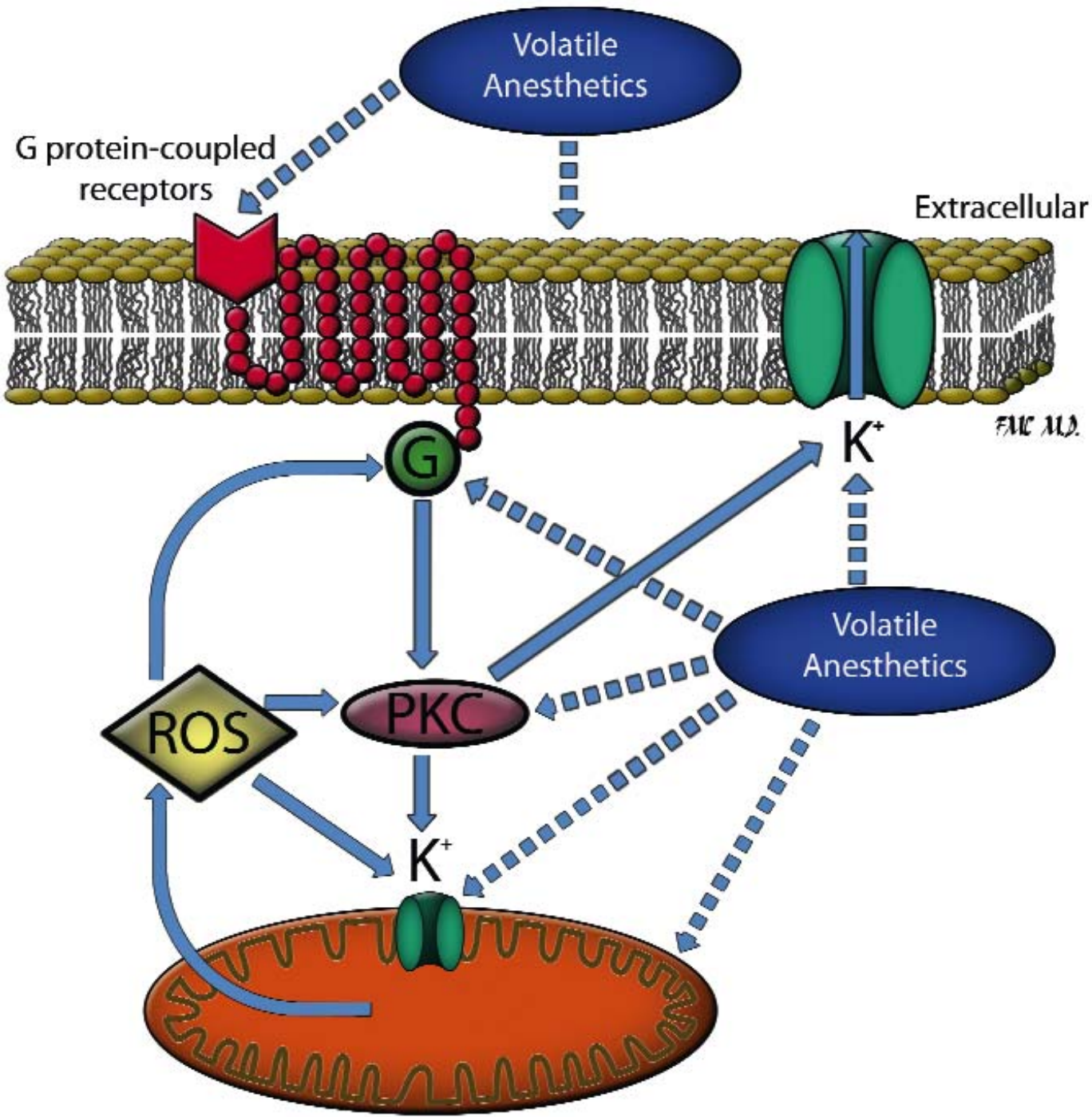


Luigi Tritapepe  
Università degli Studi di Roma "La Sapienza" - Italy

Several large surveys have demonstrated that perioperative cardiac morbidity is particularly concentrated among patients who undergo major thoracic, abdominal, or vascular surgery, especially when they are 70 years of age or older. Ashton et al prospectively studied the incidence of perioperative MI associated with thoracic, abdominal, urologic, orthopedic, and vascular surgery in a cohort of 1487 men older than 40 years. The highest MI rate (4.1%; OR 10.39, 95% CI: 2.3 to 47.5) occurred in the subset of patients with an established diagnosis of CAD. Nevertheless, independent significant risk factors for infarction also included age greater than 75 years (OR 4.77, 95% CI: 1.17 to 19.41) and the need for elective vascular surgery even in the absence of suspected CAD (adjusted OR 3.72, 95% CI: 1.12 to 12.37). Similar results were noted for the EVAR (EndoVascular Abdominal aortic aneurysm Repair) -1 trial conducted in the United Kingdom. Likewise, recent clinical trials support the notion that endovascular management of thoracic aneurysms dramatically reduces all-cause perioperative mortality and morbidity; however, the underlying cardiovascular disease may lead to similar long-term outcomes. Recent studies have shown that nitrous oxide (N2O) anesthesia may be associated with an increased risk of adverse cardiovascular outcomes. It is well-known that N2O inhibits vitamin B12-dependent enzymes and as a result increases plasma homocysteine concentrations. Homocysteine has been identified as risk factor for cardiovascular disease. Therefore elevations in homocysteine after N2O may be a causative factor in N2O toxicity. All inhaled volatile anesthetic agents have cardiovascular effects, including depression of myocardial contractility and afterload reduction. The similarities between the agents are greater than their differences. Early studies demonstrated that volatile anesthetic agents did not influence outcome compared with high-dose opioid techniques. However, randomized clinical trials in patients undergoing CABG surgery indicate that volatile anesthetics decrease troponin release and enhance LV function compared with propofol, midazolam, or balanced anesthesia techniques with opioids. These data can likely be generalized to patients with CAD who are undergoing noncardiac surgery. The use compared with the nonuse of volatile anesthetics was associated with a decrease in troponin release, preservation of early LV function, decreased ICU length of stay, and decreased late cardiac events in several trials. Although decreases in troponin levels reflect the cardioprotective actions of volatile anesthetics, none of the trials were powered to evaluate MI or death as an outcome. Volatile anesthetics have been shown in animal studies to precondition and postcondition the heart against infarction by activating specific intracellular signal transduction pathways. Decreased troponin levels in cardiac surgery patients receiving volatile anesthetics may reflect this preconditioning or postconditioning effect. De Hert et al demonstrated that sevoflurane administered throughout surgery decreased troponin and ICU length of stay compared with patients who received propofol, whereas no differences in troponin levels were observed in patients receiving sevoflurane when this volatile anesthetic was administered solely as either a preconditioning or postconditioning agent.

References

1. Badner NH, Beattie WS, Freeman D, Spence JD. Anesth Analg. 2000 Nov;91(5):1073-9.
2. Myles PS, Chan MT, Leslie K, Peyton P, Paech M, Forbes A. Br J Anaesth. 2008 Jun;100(6):780-6.





# NEAR-INFRARED SPECTROSCOPY (NIRS) MONITORING IN AORTIC ARCH SURGERY

John M. Murkin  
The University of Western Ontario, London - ON - Canada

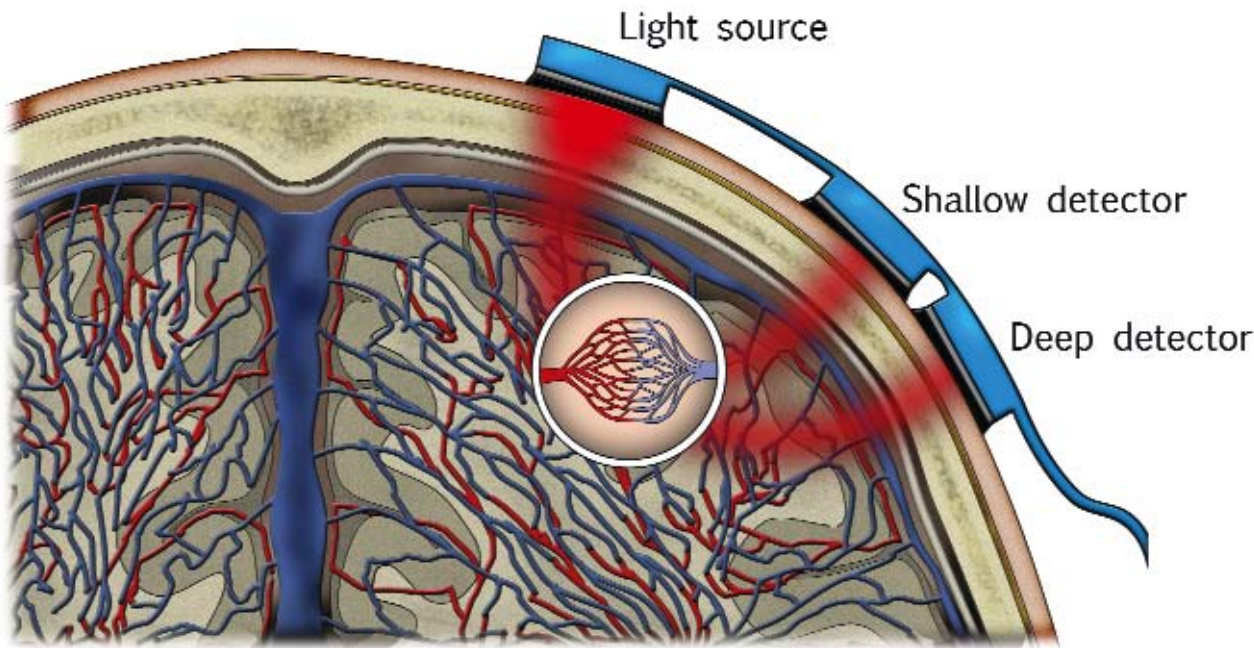
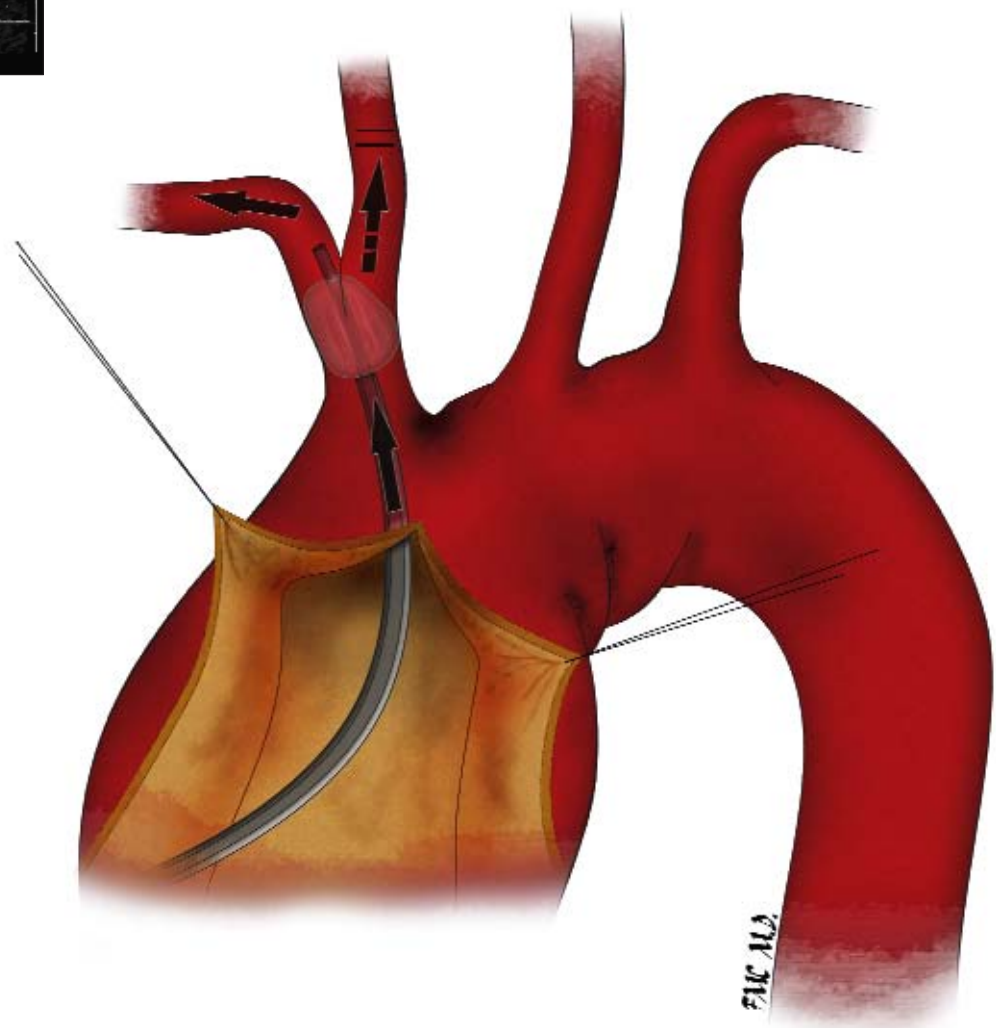
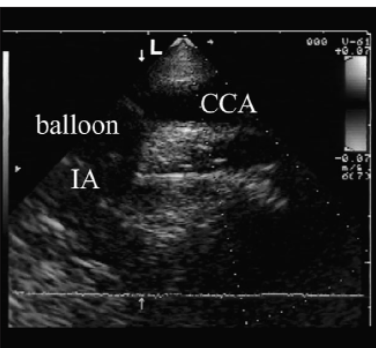
A variety of central nervous system (CNS) complications are manifest in patients following aortic arch surgery. In one series of 42 patients the in-hospital mortality was (7.1%), stroke rate was 4.8% and there were 6 episodes of transient neurological deficit (14.3%).[1] Cerebral hypoperfusion contributes to such CNS complications thus cerebral NIRS has been advocated as a means of monitoring and detecting onset of cerebral ischemia during deep hypothermic cardiac arrest (DHCA).[2,3]

In a study of 46 consecutive aortic arch surgery patients in whom SACP was established by perfusion of the right subclavian artery or by separate concomitant perfusion of the innominate and the left carotid arteries, bilateral regional cerebral tissue oxygen saturation index was monitored using INVOS 4100 NIRS and the study utilized stroke as the primary clinical end point.[4] Six patients died in hospital, and 6 patients (13%) experienced a perioperative stroke in whom NIRS values were significantly lower during SACP and also tended to be lower in the affected hemisphere. During SACP NIRS decreasing to between 76% and 86% of baseline had a sensitivity of up to 83% and a specificity of up to 94% in identifying individuals with stroke with the conclusion that using NIRS during SACP allows detection of clinically important cerebral desaturations and can help predict perioperative neurologic sequelae.[4] In another study of 59 DHCA patients managed with SACP it was reported that a sustained drop in cerebral rSO<sub>2</sub> below 55% correlated with transient neurologic events, but that NIRS was limited for detection of embolic events or hypoperfusion in the basilar region.[5]

In adult patients during aortic arch surgery, cerebral malperfusion can occur as a consequence of ascending aortic dissection with occlusion of carotid lumen,[6,7] or due to kinking or obstruction of the perfusion cannula during selective cerebral perfusion for circulatory arrest procedures – an event which has been documented during slightly more than 10% of such procedures.[8] Most recently, acute thrombosis of carotid artery graft was detected with NIRS during SACP leading to thrombectomy and restoration of flow.[9] An incomplete circle of Willis has been estimated to be a factor in cerebral malperfusion in approximately 15% of patients.[10,11] Therefore the ability of INVOS cerebral oximetry to detect onset of critical levels of cerebral hypoperfusion is well attested and may be expected to play a critical role in up to 10% to 15% of such patients.

References

1. Harrington DK, Walker AS, Kaukuntla H et al. Selective antegrade cerebral perfusion attenuates brain metabolic deficit in aortic arch surgery: a prospective randomized trial. *Circulation*. 2004 Sep 14;110(11 Suppl 1):II231-6
2. Kurth CD, Steven JM, Nicolson SC. Cerebral oxygenation during pediatric cardiac surgery using deep hypothermic circulatory arrest. *Anesthesiology*. 1995;82(1):74-82.
3. Kurth CD, Steven JM, Nicolson SC et al. Kinetics of cerebral deoxygenation during deep hypothermic circulatory arrest in neonates. *Anesthesiology*. 1992;77(4):656-61.
4. Olsson C, Thelin S. Regional cerebral saturation monitoring with near-infrared spectroscopy during selective antegrade cerebral perfusion: diagnostic performance and relationship to postoperative stroke. *J Thorac Cardiovasc Surg*. 2006 Feb;131(2):371-9.
5. Orihashi K, Sueda T, Okada K et al. Near-infrared spectroscopy for monitoring cerebral ischemia during selective cerebral perfusion. *Eur J Cardiothorac Surg*. 2004 Nov;26(5):907-11.
6. Janelle GM, Mnookin S, Gravenstein N et al. Unilateral cerebral oxygen desaturations during emergent repair of DeBakey type 1 aortic dissection: potential aversion of a major catastrophe. *Anesthesiology* 2002;96:1263-5.
7. Sakaguchi G, Komiya T, Tamura N, et al. Cerebral malperfusion in acute type A dissection: direct innominate artery cannulation. *J Thorac Cardiovasc Surg* 2005;129:1190-1.
8. Santo KC, Bonser RS, et al. Near-infrared spectroscopy . An important monitoring tool during hybrid aortic arch replacement. *Anesth Analg* (in press) 2008
9. Orihashi K, Sueda T, Okada K et al. Malposition of selective cerebral perfusion catheter is not a rare event. *Eur J Cardiothorac Surg*. 2005 Apr;27(4):644-8
10. Hoksbergen AW, Legemate DA, Csiba L, et al. Absent collateral function of the circle of Willis as risk factor for ischemic stroke. *Cerebrovasc Dis* 2003;16:191-8.
11. Merkkola P, Tulla H, Ronkainen A, et al. Incomplete circle of Willis and right axillary artery perfusion. *Ann Thorac Surg* 2006;82:74-9.



Yamume Tshomba

Vita-Salute San Raffaele University, Milano - Italy

Y. Tshomba, L. Bertoglio, E. Civilini, E. M. Marone, G. Melissano, R. Chiesa

After a decade of endograft treatment for a variety of thoracic aortic diseases, either in acute or chronic settings, clear indications for patient selection are still not finalized, ideal devices are not available, and the surgical technique is not standardized. Thoracic endovascular aortic repair, however, has modified radically the way most surgeons approach aortic arch pathology<sup>1-6</sup>.

In this study we analyze and compare the technical and clinical success recorded in the different anatomical settings of endografting for aortic arch disease.

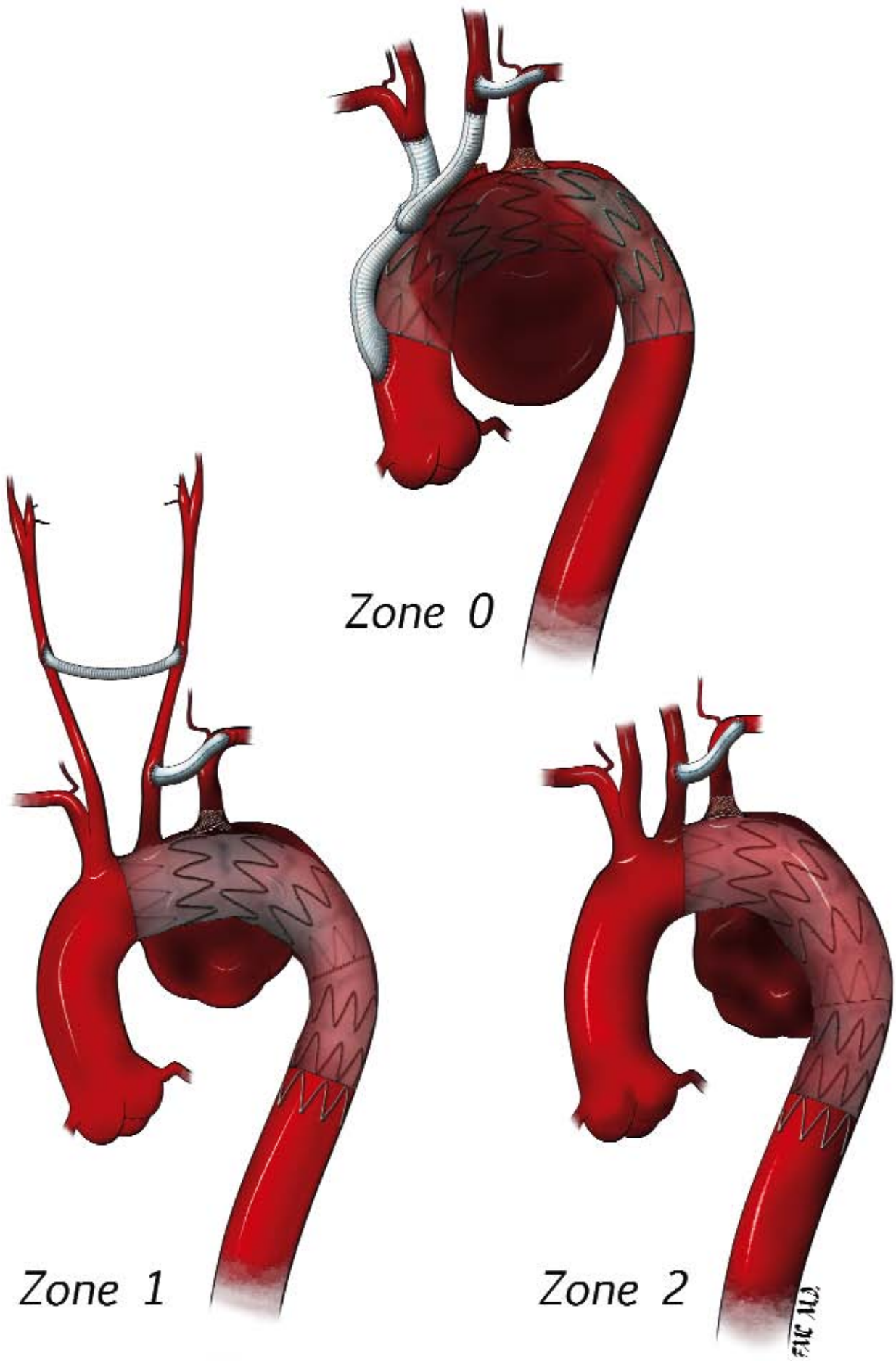
Between 1999 and 2008, among 292 patients treated at our Institution for thoracic aorta disease with a stent-graft, the aortic arch was involved in 106 cases. According to the classification proposed by Ishimaru, aortic "zone 0" was involved in 22 cases, "zone 1" in 23 cases and "zone 2" in 61 cases.

These have been our results: "Zone 0": proximal neck length after debranching:  $43.9 \pm 5.6$  mm. Initial clinical success 82%: 3 deaths (stroke), 1 type Ia endoleak. At a mean follow-up of  $24.7 \pm 17$  months the midterm clinical success was 86%. "Zone 1": proximal neck length after debranching:  $29 \pm 5$  mm. Initial clinical success 83%: 0 deaths, 4 type Ia endoleaks. At a mean follow-up of  $20.1 \pm 16$  months the midterm clinical success was 91%. "Zone 2": proximal neck length:  $30.4 \pm 5.0$  mm. Initial clinical success 90.2%: 1 death, 4 type Ia endoleaks, 1 case of open conversion. At a mean follow-up of  $33.4 \pm 19.2$  months the midterm clinical success was 95.1%: 3 type I endoleak spontaneous resolutions, 1 conversion.

Over the last years, synergy between endovascular and surgical procedures allowed treatment of all segments of the aortic arch. Overall perioperative and medium-term results were reasonably favourable. Total de-branching of the arch for "zone 0" aneurysms allowed to obtain a longer proximal aortic landing zone with lower incidence of endoleak, however a higher risk of cerebro-vascular accident was observed. The relatively high incidence of adverse events in "zone 1" could be associated to a shorter proximal neck, therefore this landing zone is reserved for patients unfit for sternotomy. "Zone 2" cases can be treated with the same low mortality and morbidity of regular descending thoracic aneurysms.

References:

1. Chan YC, Cheng SW, Ting AC, Ho P. Supra-aortic hybrid endovascular procedures for complex thoracic aortic disease: single center early to midterm results. *J Vasc Surg*. 2008 Sep;48(3):571-9
2. Saleh HM. Hybrid repair of aortic arch aneurysm. *Acta Chir Belg*. 2007 Mar-Apr;107(2):173-80
3. Melissano G, Bertoglio L, Civilini E, Marone EM, Calori G, Setacci F, Chiesa R. Results of thoracic endovascular grafting in different aortic segments. *J Endovasc Ther*. 2007 Apr;14(2):150-7.
4. Schumacher H, Von Tengg-Kobligk H, Ostovic M, Henninger V, Ockert S, Böckler D, Allenberg JR. Hybrid aortic procedures for endoluminal arch replacement in thoracic aneurysms and type B dissections. *J Cardiovasc Surg (Torino)*. 2006 Oct;47(5):509-17
5. Melissano G, Civilini E, Bertoglio L, Setacci F, Chiesa R. Endovascular treatment of aortic arch aneurysms. *Eur J Vasc Endovasc Surg*. 2005 Feb;29(2):131-8.
6. Bergeron P, Coulon P, De Chaumaray T, Ruiz M, Mariotti F, Gay J, Mangialardi N, Costa P, Serreo E, Cavazzini C, Tuccimei I. Great vessels transposition and aortic arch exclusion. *J Cardiovasc Surg (Torino)*. 2005 Apr;46(2):141-7.





# APPROACH TO RETROGRADE DISSECTION INTO THE AORTIC ARCH AND RESIDUAL DISSECTION AFTER OPEN TREATMENT OF TYPE A DISSECTION

**Vicente Riambau**

*Hospital Clinic, University of Barcelona - Spain*

V. Riambau, Ph. Lerut

Dissection in the thoracic aorta has an overall incidence of 2.9/100000/year. The most common classifications are the Stanford and the DeBakey systems. These classifications are mainly based upon the involvement of the ascending aorta and have their main implications towards treatment options. Type A or Type I-II are considered an open surgical indication whereas Type B or type III are mainly treated conservative or endovascular.

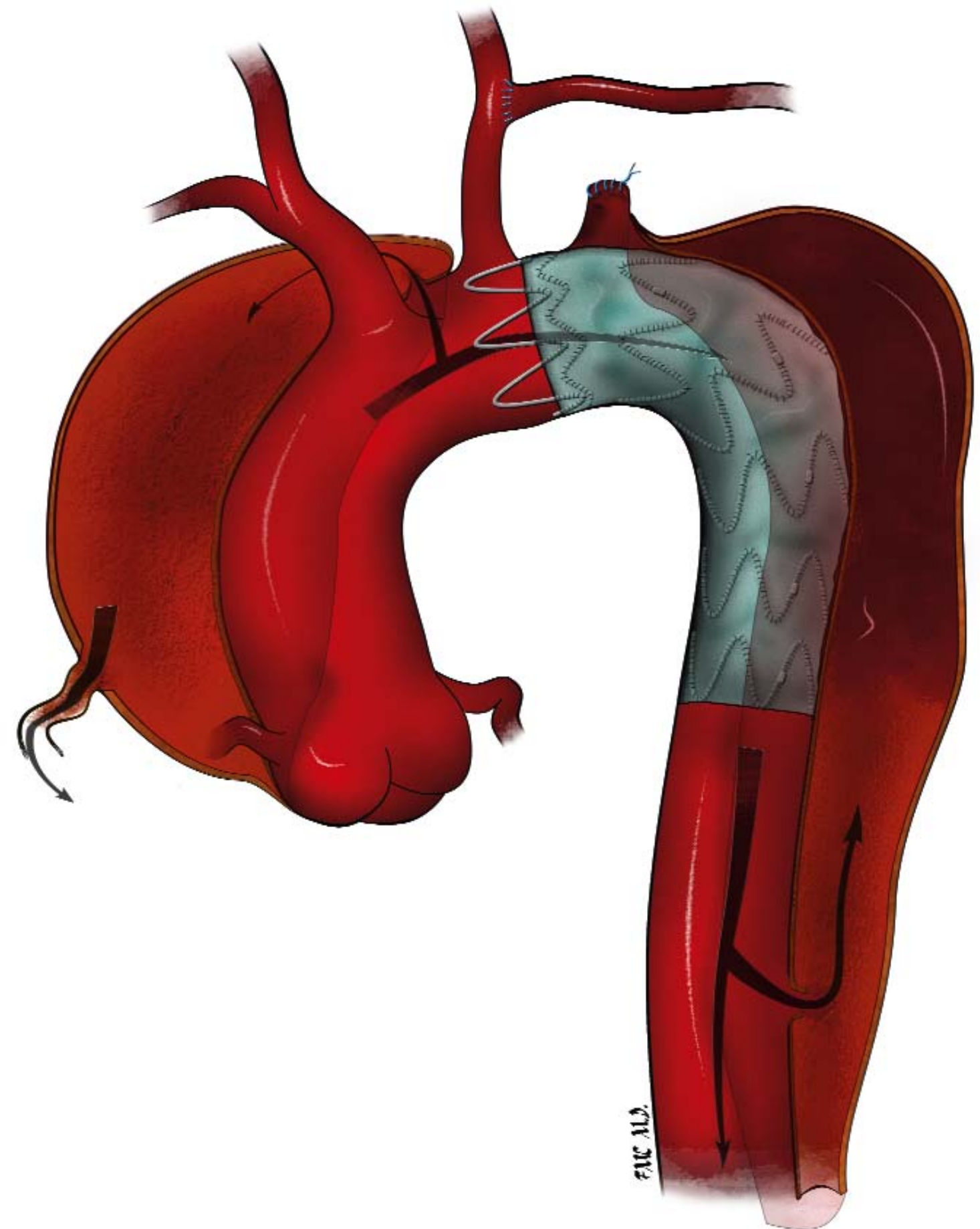
The outline of this talk includes: causes and treatment of retrograde type A dissection and the fate of the residual false lumen after type A surgical repair.

Retrograde type A dissection is defined as a dissection originating from a distal tear, beyond left subclavian artery, that is proximally progressing into the aortic arch and ascending aorta. Although fairly rare, it is seen more often as a complication of the endovascular treatment of a type B dissection. The overall incidence ranges from 4-20% among Stanford type A dissections. The main causes of iatrogenic retrograde type A dissection are wire and sheath manipulation, balloon dilatation and the use of rigid designed grafts not able to adapt perfectly to the aortic curve in an angulated aortic arch. Bare proximal spring in thoracic stent-graft has been reported as a cause of intimal tear. Moreover, the extra oversize of stent-grafts, more than 10%, results in a higher radial force against the aortic wall with potential intimal injury.

Besides retrograde type A dissection as a consequence of endovascular repair, a new distal dissection is described as a complication due to mechanical stress of the distal prosthesis. The initial endograft selection (short devices) seemed to be prone to this complication when the distal stent graft is positioned angulated with the longitudinal axis of the descending thoracic aorta.

Of the treatment options, prevention of complications is probably the first line of treatment. Endograft selection with the right diameter size and length, the use of non bare stents grafts, avoidance of ballooning and unnecessary guide or catheter manipulations are the lessons learned. Further security of sufficient sealing zone by covering the left subclavian artery whether or not in combination with hybrid techniques (supra aortic trunks transpositions) might be necessary in case of adequate treatment of type B dissection or retrograde type A dissection. Retrograde type A dissection needs an open repair as a first choice of treatment. Nevertheless, dissections limited into the arch or in the ascending aorta with a clear primary entry tear beyond subclavian artery can be approached by thoracic endografting in high risk patients.

The last question concerns the fate distal false lumen. Literature states that thrombosis of the false lumen is an independent predictor of aneurysm formation of the distal thoracic and abdominal aorta. A recent study looked at the fate of the distal lumen after open surgical type A repair and reports a false lumen thrombosis in 22,5% with no residual intimal flap. Among patients with a residual false lumen a partial thrombosis was visualized in 41,3% whereas they remained completely patent in 36,2%. As a consequence of the patency of the false lumen, follow-up screening towards aneurysm formation reported an aortic growth rate of 0.34 cm/year in patients with partial thrombosis of the false lumen versus an increase of 0.56 cm/year in patients without thrombus in the false lumen. Hybrid surgery combining open and endovascular grafts, like the so called 'frozen elephant trunk' or antegrade stent-graft deployment, have been suggested and are under evaluation. Other techniques can be applied during type A repair as a prophylactic surgery in order to facilitate later retrograde endovascular treatment of residual distal dissection. Longer grafts in the ascending aorta replacement with a bypass to the brachio-cephalic trunk would allow a further retrograde thoracic endografting with simplified extra-anatomical trunk transpositions in case of increase of residual type B dissections.



# ANOMALIES AND VARIANT ANATOMY OF THE AORTA AND SUPRA-AORTIC VESSELS: ADDITIONAL CHALLENGES MET BY HYBRID PROCEDURES

Carlo Setacci

Azienda Ospedaliera Universitaria Senese, Siena - Italy

C. Setacci, F. Setacci, P. Sirignano, G. de Donato, E. Chisci, G. Galzerano

The introduction of endovascular stent graft technology has ushered in a new era in therapy for diseases of the aortic arch and descending thoracic aorta. The technical challenges of stent graft deployment, such as proximity to the great vessels and arch tortuosity, have been and remain a focus of device engineering. More recently, repair of aortic arch aneurysms has been accomplished using both 'hybrid' (open and endovascular) and totally endovascular techniques.

The aortic arch anatomy can play a significant role in this specific procedure, and the operators have to deal with a variety of situations. Aortic arch anatomy can be classified as:

- Type I: all supra-aortic vessels originate at the same level in a straight line;
- Type II: innominate and left common carotid arteries originate below the left subclavian artery;
- Type III: all supra-aortic vessels originate below the straight line, the angle between vessel origin and aortic arch is acute.

It is known that complex arch anatomy such as arch elongation, diffuse vessel's calcification or anomalies of the origin of supra-aortic vessels increases technical difficulties during aneurysms exclusion.

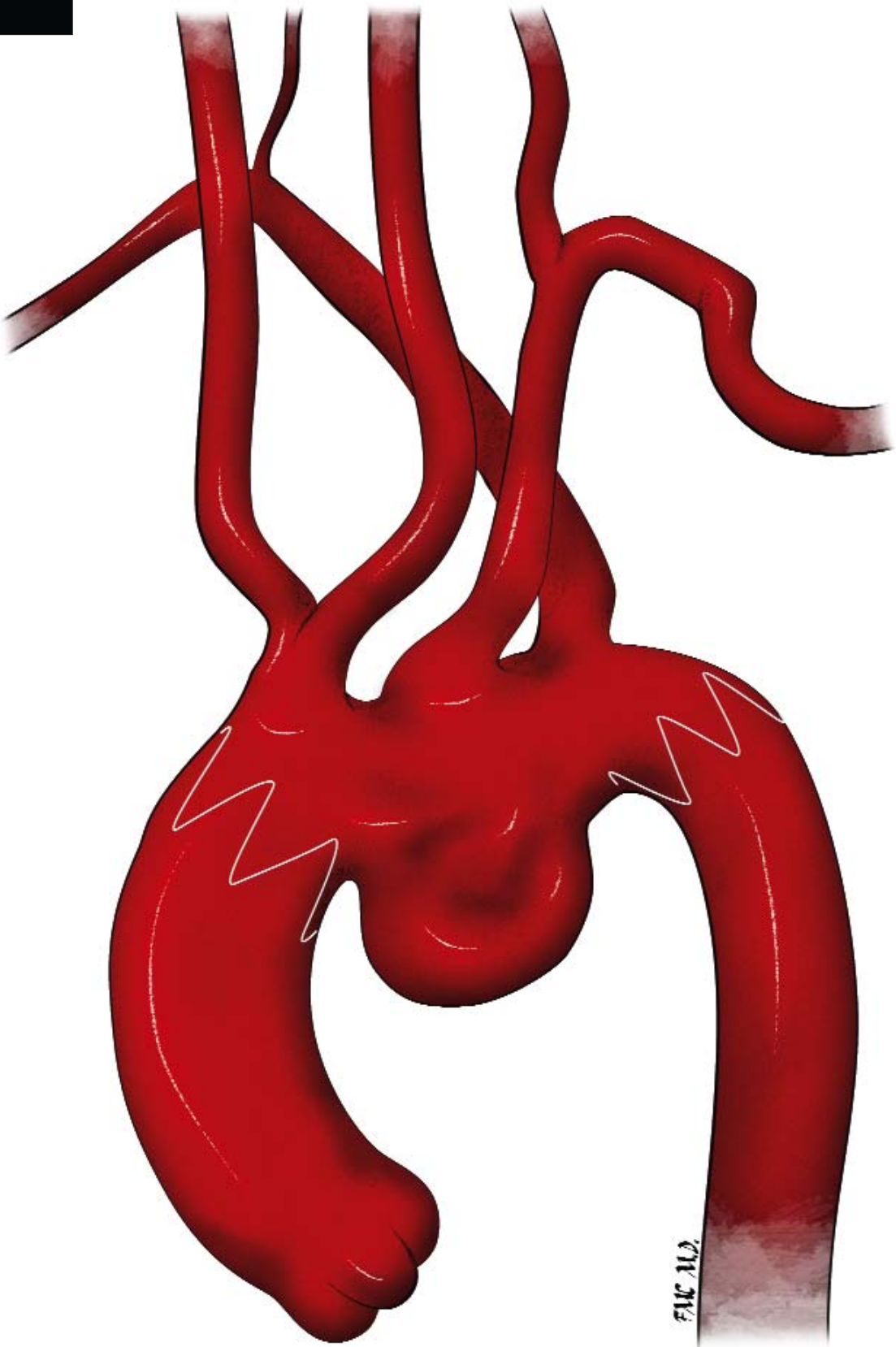
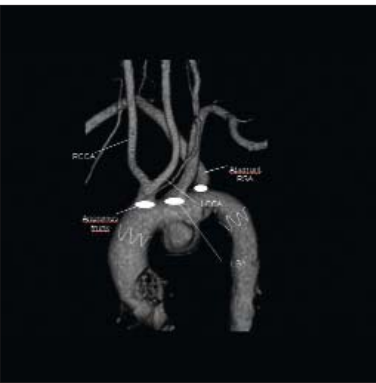
Aortic arch anomalies have been classified by various systems; some involving as many as 32 categories. There are five broad groups of aortic arch anomalies relevant to the vascular surgeons: (1) double aortic arch, (2) left aortic arch, (3) right aortic arch, (4) cervical aortic arch, (5) carotid anomalies.

The most common anomaly is an aberrant right subclavian artery, sometimes referred to as a 'ring', which is present in 0.5% of individuals. The right common carotid artery and subclavian artery may, also, arise directly from the aortic arch, with the absence of a brachiocephalic trunk.

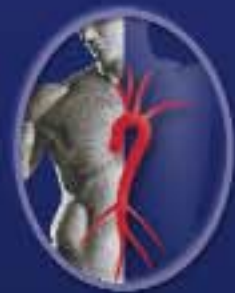Common carotid agenesis is much rare. One, frequent, anomaly is the independent origin of the left vertebral artery directly from the aortic arch. Another common anatomical situation, it is encountered in approximately 10% of cases, is the so-called "bovine-arch" where the left common carotid artery takes origin from the brachiocephalic trunk. This is a clear disadvantage during carotid stenting, but may represent an advantage during TEVAR.

Edward describes three main types of right-sided aortic arch: type I, with mirror-image branching of the major arteries; type II, with an aberrant subclavian artery; and type III, with isolation of the subclavian artery (where the subclavian artery is connected to the pulmonary artery through the ductus arteriosus). In each of these three major types of right aortic arch, the ductus arteriosus may be on the left, on the right, or bilateral. Type I represents 59% of all right aortic arches, type II 39.5%, and type III 0.8%. In adulthood, symptoms are more often the result of early atherosclerotic changes of the anomalous vessels, dissection, or aneurysmal dilatation with the compression of surrounding structures.

All these situations can increase the technical difficulty of endovascular exclusion of the aneurysm and, furthermore, can make complex debranching of the supra-aortic vessel necessary to obtain an adequate landing zone and to preserve the brain and spinal cord perfusion.







'08

SCIENTIFIC ABSTRACTS

EMERGENCIES

*Chairmen:* Giancarlo Bracale, Luigi Chiariello, Fabio Guarracino

THE AORTIC DEGENERATION ASSOCIATED WITH BICUSPID VALVE: A SOURCE OF EMERGENCY SURGERY?	Maurizio Cotrufo Discussant: Giovanni La Canna
EMERGENCY TREATMENT OF TRAUMATIC RUPTURE OF THE AORTA	Raphael de Geest Discussant: Enrico M. Marone
NEW AND OLD MECHANICAL DEVICES TO ASSIST CIRCULATION	Roberto Fumagalli Discussant: Antonio Pesenti
ACUTE TYPE B DISSECTION, CURRENT TREATMENT STRATEGIES	Nicola Mangialardi Discussant: Flavio Peinetti
“INTRA MURAL HAEMATOMA” AND “PENETRATING AORTIC ULCERS”	Arno von Ristow Discussant: Germano Melissano
ANESTHESIOLOGICAL MANAGEMENT AND ASSESSMENT OF RUPTURED TAA	George Silvay Discussant: Jane C. Ballantyne
MORE TREATMENT OPTIONS FOR RUPTURED AAA: ARE WE SAVING MORE LIVES?	Timothy Resch Discussant: Marco Setti

# THE AORTIC DEGENERATION ASSOCIATED WITH BICUSPID VALVE: A SOURCE OF EMERGENCY SURGERY?

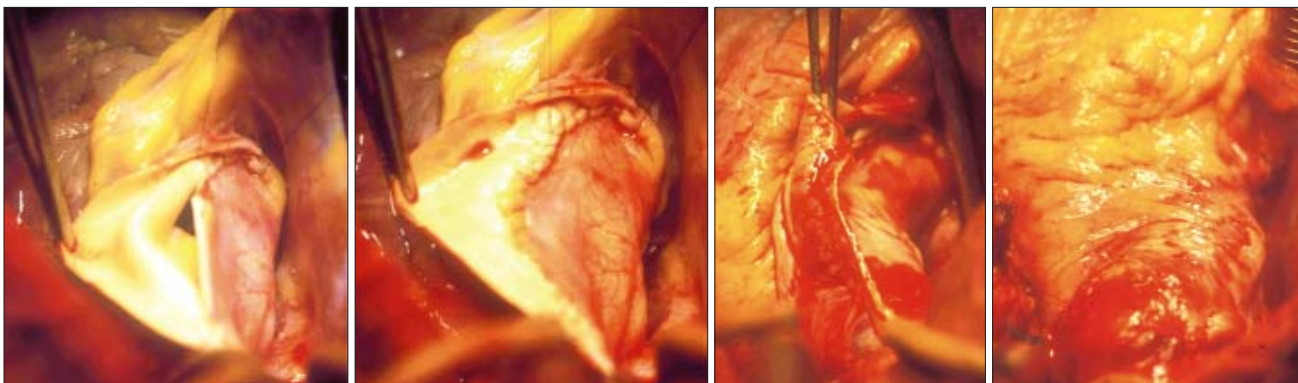
**Maurizio Cotrufo**  
*Università degli Studi di Napoli Federico II - Italy*  
 M. Cotrufo, A. Della Corte

**Introduction:** Bicuspid aortic valve is the most frequent cardiac congenital defect and accounts for the majority of patients needing aortic valve surgery in their adulthood and elderly age. It also represents a source of emergency, since it increases the risk of acute aortic dissection 9-fold. This study aimed to retrospectively review our 12-year experience with surgical treatment of the different anatomic-clinical forms of the syndrome of bicuspid aortic valve (BAV) with ascending aorta dilation.

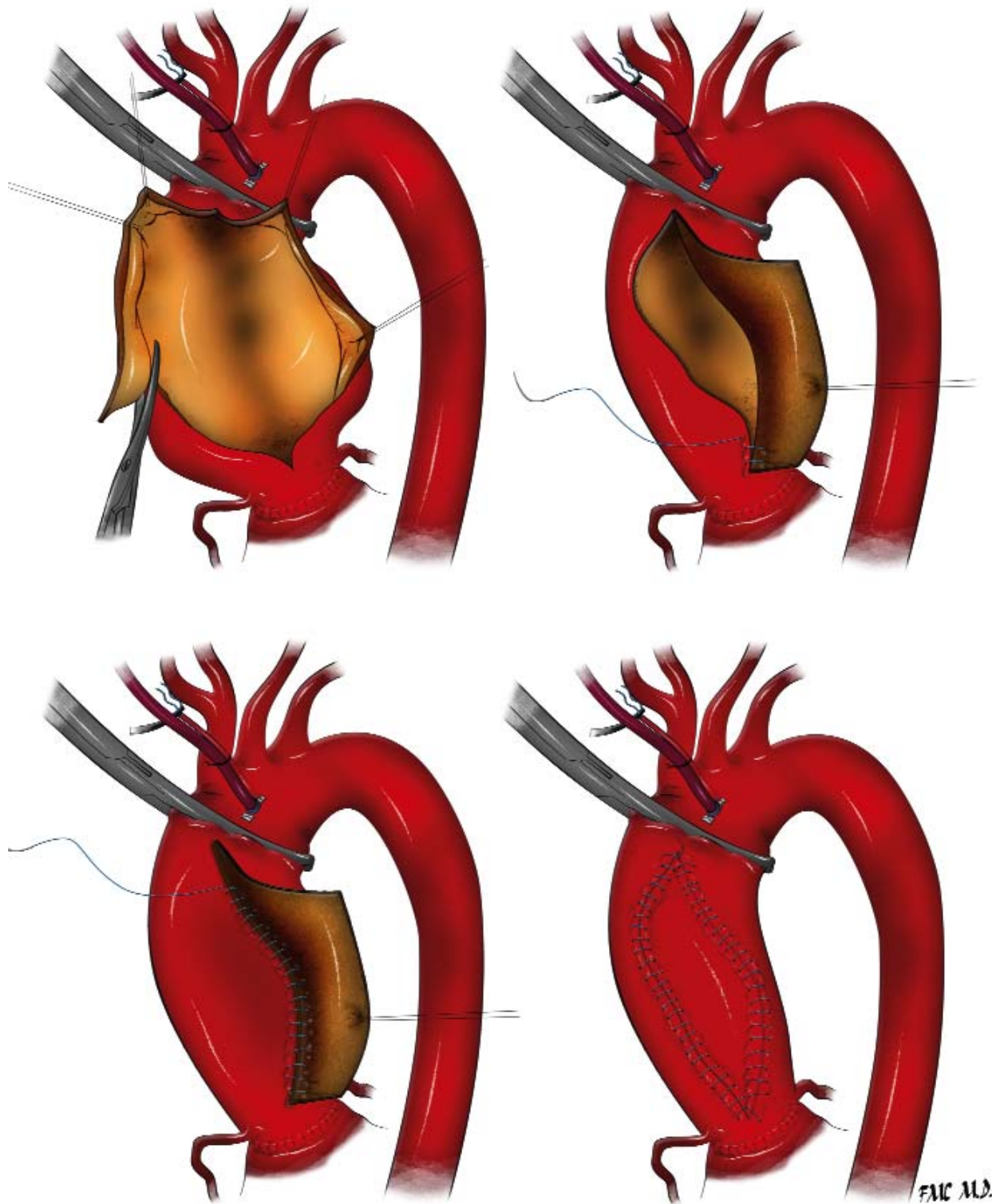
**Methods:** Between January 1996 and December 2007, 347 BAV patients underwent AVR and/or treatment of dilated ascending aorta (indicated for an aortic ratio of 1.4 or more). Surgical treatment was tailored on the basis of the aortic structures and tracts involved, also considering the geometrical configuration of the ascending aorta (symmetric versus asymmetric). Outcomes were evaluated by dividing the study population into 5 groups: A= AVR only, 248 patients; B= Bentall operation (for coexistence of sinus dilatation), 10 patients; C= AVR and supra-coronary aorta replacement (for associated symmetric dilatation of the tubular tract), 8 patients; D= AVR and waistcoat aortoplasty (associated asymmetric tubular tract dilatation), 74 patients; E= waistcoat aortoplasty only, 7 patients (normally-functioning BAV with asymmetric tubular dilation). Waistcoat ascending aortoplasty consisted of resection of the convex aspect and plastic reconstruction of a new reinforced convexity by overlapping two layers of autologous aortic wall.

**Results:** Overall hospital mortality was 1.4%, without significant differences between the groups. Mean in-hospital stay, ranging from 7±1 days (group E) to 11±5 days (group B) did not differ significantly. Follow-up was 98% complete. Five-year survival rates were comparable in the 5 groups (log-rank: group A versus B+C+D+E: p=0.19). In groups D and E, echocardiography showed stability of post-reduction aortic diameters (p=0.21 follow-up versus early postoperative) with no aneurysm recurrence and no case of emergency reoperation. Reoperation in the follow-up was needed in 8 group A patients due to ascending aorta aneurysm (6 patients, 2.4%) or acute type A dissection (2 patients, 0.8%). Two group E patients required reoperation during their follow-up, for BAV stenosis in both cases: aortic wall histopathology showed complete fusion of the two overlapped layers, with microvessel development and no medial degeneration.

**Conclusions:** The multiple anatomic-clinical forms of BAV disease require tailored surgical approaches: in our experience, including waistcoat aortoplasty for asymmetric forms of tubular dilatation, good long-term results were achieved. Waistcoat aortoplasty also represents an adjunctive procedure for patients with severe BAV stenosis and mild or moderate ascending dilation, to prevent the risk of postoperative further dilation or dissection.



Emergencies





# EMERGENCY TREATMENT OF TRAUMATIC RUPTURE OF THE AORTA

Raphael de Geest  
OLV Clinic, Aalst - Belgium

Acute traumatic rupture of the aorta (TRA) is one of the most catastrophic injuries which can occur to the human aorta.

Traumatic disruption is caused by the shearing forces of a blunt deceleration injury. The damage can be located at any site of the aorta, but in more than 90 per cent of cases it is situated at the isthmus of the descending aorta.

The disruption of the aortic wall may be complete (all three layers) or partial (only intima and/or media involved). Normally complete rupture kills the victim within moments of the accident while in partial rupture exsanguination may be prohibited by the almost intact adventitial wall and mediastinal tissues ("contained rupture"). Full rupture may then occur later mainly due to an episode of hypertension.

As a consequence rapid diagnosis and efficient treatment are essential in order to improve the usually fatal evolution.

Because most patients had a polytrauma a broad spectrum of other serious, even life-threatening injuries may be present which determines mainly the further strategy.

A TRA constitutes an absolute indication for prompt surgical treatment in most cases. In general as soon as the diagnosis of TRA has been made the patient is immediately taken to surgery because the risk of free rupture and exsanguination may be imminent.

- In a minority of cases an emergency thoracotomy may be necessary.
- Most patients will need urgent surgery because the risk of fatal rupture is high.
- In poly traumatic patients priority to treatment of other life-threatening lesions must usually be given.
- It is sometimes preferable to delay the intervention for some days, even weeks: the main goal is to avoid further damage or aggravation of serious lesions (e.g. cranial trauma) by the intervention, or to wait for healing or stabilization of non surgical lesions (e.g. lung contusion).
- Some surgeons have proposed to postpone the intervention for minor lesions e.g. a small pseudo-aneurysm without or only a minimal surrounding haematoma, which carries probably a lower risk for fatal rupture.

Surgical procedures: The aorta is approached through a left posterolateral thoracotomy in the IVth intercostal space.

Careful dissection of the distal thoracic aorta, the LSA and the aortic arch between left carotid and LSA is performed without touching the haematoma as less as possible.

In most cases the aorta can then be cross clamped just distally to the left subclavian artery if enough space available, and the distal clamp moved upwards close to the gap to avoid blood loss from intercostal arteries.

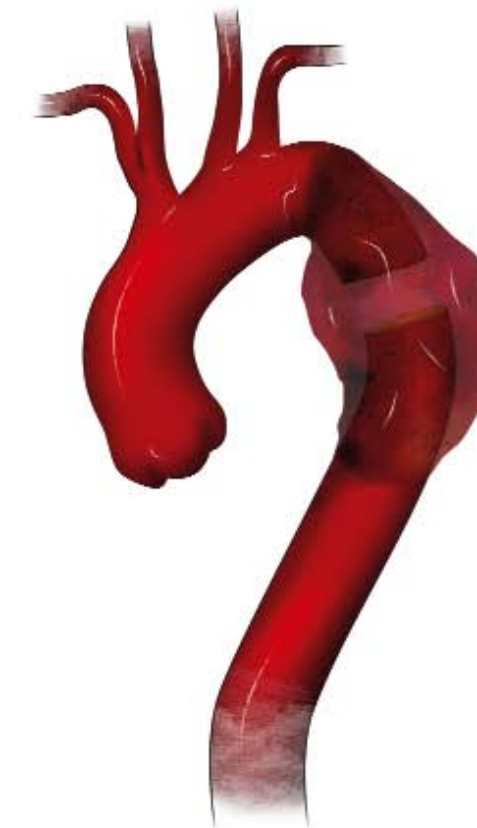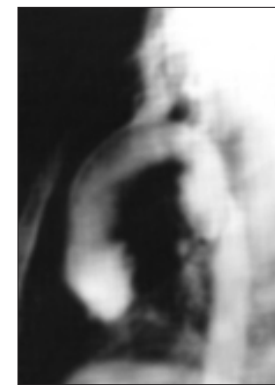
Three intra operative methods can be used to manage the surgery:

1. The most simple one is the simple cross clamp technique.
2. The use of external or internal temporary shunts (e.g. Gott shunt) is almost abandoned today.
3. Temporary bypass using extra corporeal circulation, whether left atrium – femoral artery partial bypass or femoral vena to femoral artery circulation with oxygenator. The latter method is advisable no tubes in the operation field are disturbing; A-V femoral bypass with oxygenator provides the possibility to switch to total bypass, deep hypothermia and if necessary circulatory arrest in complex cases.

Although recent reported series report low mortality and paraplegia rates with all techniques, no technique has proven to consistently prevent mortality and paraplegia. No techniques should be abandoned or condemned. In any particular surgical team's experience one or more of these techniques may be preferred over others.

Non invasive procedures: Since 2000 the use of transcatheter endoluminal stentgrafts has been introduced in our hospital. This procedure seems to be a promising tool. Although possible early and late complications of the stentgraft procedure have to be taken in consideration, the great advantage of this non invasive method is the possibility to use it in those cases where surgery is initially not attractive, contra indicated or impossible. Further more it can be easily combined with other surgical interventions.

The strategy in some complex cases will be illustrated together with the results of a personal experience of 47 cases.



*Total Transsection*



*Partial Rupture*

# NEW AND OLD MECHANICAL DEVICES TO ASSIST CIRCULATION

**Roberto Fumagalli**

*Ospedale S. Gerardo di Monza, Università degli Studi Milano Bicocca - Italy*  
L. Avalli, A. Perri, R. Fumagalli

The need for mechanical cardiac support has been involving physicians and the medical-device support industry for decades. For many patients affected by severe heart failure the medical therapy is not enough and no donor heart is available for transplantation.

Extracorporeal support was first used during cardiac surgery to substitute heart and lung function in 1953. The use of this device was limited to a few hours because of complications such as bleeding, thromboembolism and infections, since the oxygenator involved direct contact between oxygen and blood (1).

In 1962 the intraaortic balloon counter-pulsation was used for temporary hemodynamic support, but it was limited by the same invasive nature and complications of extracorporeal support.

A full cardiac (and lung) replacement was provided only in 1972 by a new oxygenator separating the oxygen from the blood by a membrane: the extracorporeal membrane oxygenation (ECMO). This approach has been used to support both circulation and gas exchange, but is mainly a treatment for refractory hypoxemic ARDS.

More practical and more generally useful kinds of mechanical cardiac support are the following devices: centrifugal pumps, volume-displacement pumps and axial-flow pumps. Their clinical indications are: a) the need of a temporary support, when recovery of native heart function is anticipated; b) patients candidates for heart transplantation who couldn't survive the waiting period, as a "bridge to transplantation"; c) a permanent replacement for the native heart (2).

Centrifugal pumps are only for short-term support. They are, up to now, the most diffused tool to temporary support the failing heart and most of the experience reported concerns this type of device. The percutaneous vascular approach and the availability of the heparin coated circuits is one of the reasons why this technique had been widely used. A major concern is still represented by the overload of the left ventricle: several operative solutions had been proposed. The content of the communication will refer to our clinical experience in the support of patients with cardiogenic shock using centrifugal pump.

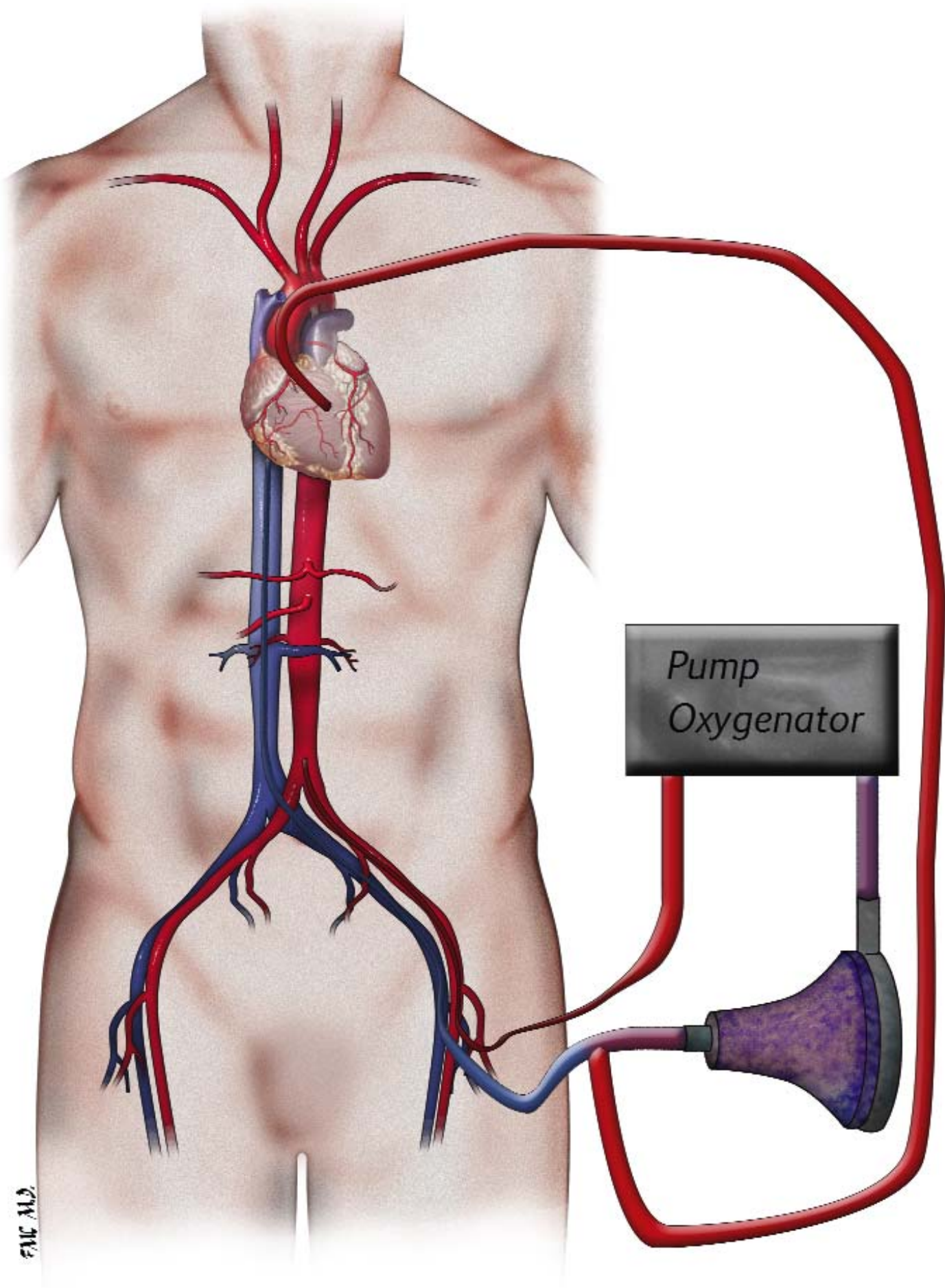
Volume-displacement ventricular assist devices mimic the cyclic systole and diastole of the heart; their use associated to a specific pharmacologic regimen has been shown to be able to reverse severe heart failure secondary to nonischemic cardiomyopathy (3).

The third category of ventricular assist device, the axial-flow pump, includes some percutaneous devices which can be inserted in the cardiac catheterization laboratory without requiring cardiac surgery.

In spite of the availability of these devices, the problems faced in the early years (infection, bleeding, thromboembolism, limited mobility) are still present and require further study.

**References**

1. Sala C, Patroniti N, Fumagalli R. Extracorporeal Support and Renal Function, in: Ronco C. Bellomo R.: Critical Care Nephrology, Kluwer Academic Publishers 187-10.
2. Baughman KL, Jarcho JA. Bridge to life-Cardiac Mechanical Support N Engl J Med 2007; 357 (9): 846-9
3. Birks EJ, Tansley PD, Hardy J, et al. Left ventricular Assist Device and Drug Therapy for the Reversal of Heart Failure, N Engl J Med 2006; 355 (18): 1873-84





Nicola Mangialardi

A.C.O. San Filippo Neri, Roma - Italy

N. Mangialardi, P. Costa, E. Serrao, S. Ronchey, V. Alberti

Introduction: Acute aortic dissection is the most frequent aortic emergency. The natural history of acute type B aortic dissection presents a high mortality risk at an early stage and also during follow-up.

Up to now, medical therapy has been the current treatment for un-complicated dissections, while open surgery, endovascular repair or fenestration are advocated for complicated pathologies.

Endovascular treatment is a newer technology that has shown the potential to improve the outcomes and reduce the risks even in un-complicated dissections but the optimal treatment remains controversial.

In this review of our experience, we compare the outcome of medical and endovascular treatment.

Methods: From May 1998 to May 2008, the Vascular Surgery Unit at S. Filippo Neri Hospital has treated 146 patients with thoracic aortic pathologies. The pathologic entities treated included: degenerative thoracic aortic aneurysms 42.4%, N=62, chronic aortic dissections 30.8%, N=45, acute type B dissections 10.9%, N= 16, pseudo-aneurysms 8.9%, N= 13, penetrating aortic ulcer 3.4%, N=5, aortic graft infection 1.3%, N= 2 and aortic coarctation 2.0%, N=3.

We started to treat acute dissections in 2002 and indications for treatment included rupture, impending rupture with periaortic haematoma, malperfusion, recurrent thoracic pain and refractory hypertension.

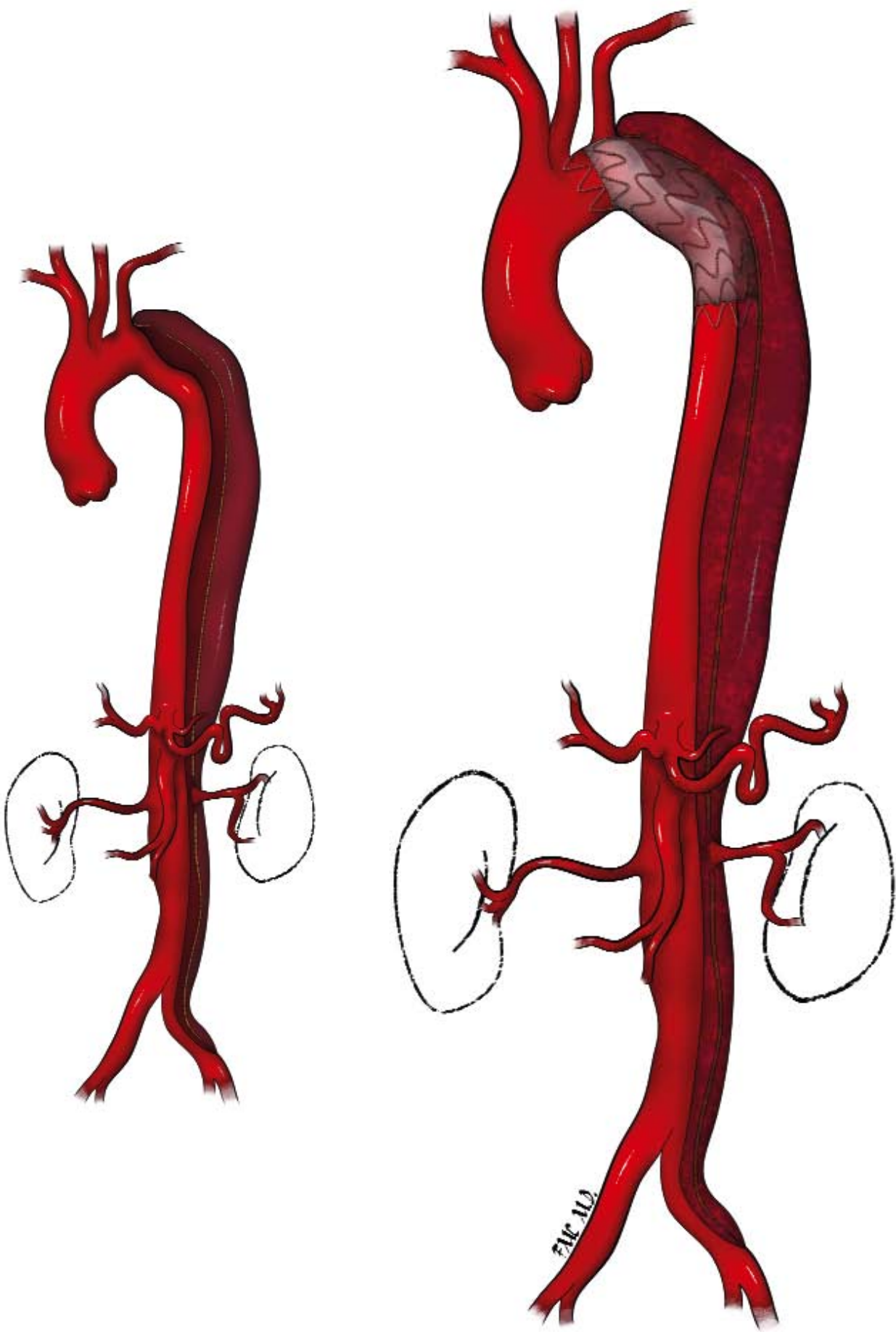
From 2003 we collected data on 31 medically treated patients affected by type B acute dissections.

Results: The 30-day mortality rate for patients submitted to endografting was 12,5% (2/16). During follow-up, no patients died but 1 patient had a dilatation of the abdominal aorta (7,1%). Proximal false lumen thrombosis was achieved in 87.5% of cases. Among medically treated patients there were 2 in-hospital mortality (6.4%). During follow-up we noted 9 dilatations of the thoracic and/or abdominal aorta (29.0%). Among these, 3 patients required open surgery for a thoraco-abdominal aneurysm and two an endovascular thoracic repair. Two death for unknown circumstances occurred also.

Conclusions: Aortic type B dissection is a serious disease associated with a high morbidity and mortality. Nowadays, medical therapy is our current treatment for un-complicated patients but long-term results are far from satisfactory. More consistent and aggressive use of anti-impulse and anti-hypertensive therapy is needed.

Despite improvements in surgical and anaesthesiological technique, open surgery mortality rate remains high in complicated cases even in more recent series. In similar patients, endovascular treatment with the new commercially available stent-grafts shows a lower mortality risk compared to surgery.

Endovascular treatment for un-complicated patients in order to prevent complications is an appealing option but it seems actually unjustified outside of randomized trials.



# “INTRA MURAL HAEMATOMA” AND “PENETRATING AORTIC ULCERS”

Arno von Ristow

Pontificia Universidade Católica and Centervasc-Rio, Rio de Janeiro - RJ - Brazil

A. Vescovi, M. Gress, B.V. Massière, J.M. Cury, R.C. Abreu, M. Lacerda, M. Arêas,  
A.L. Medina, A. von Ristow

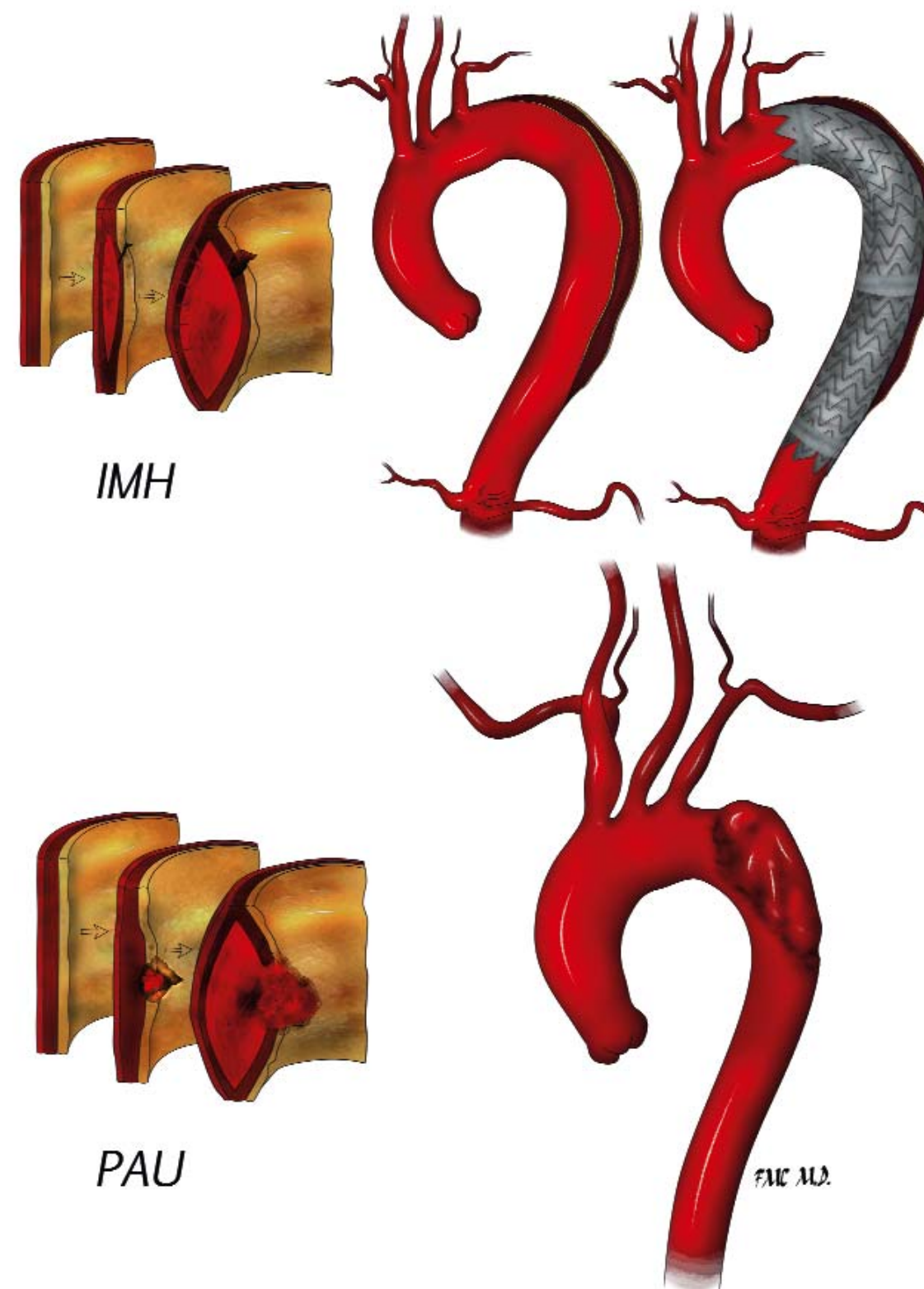
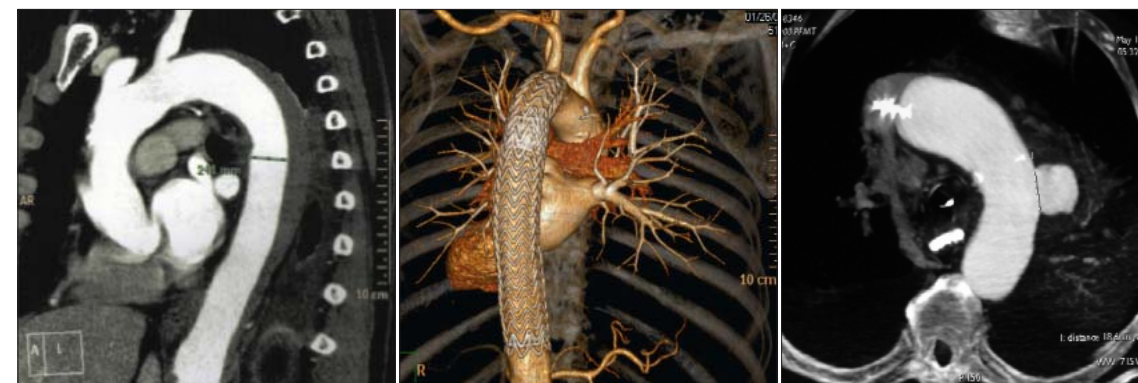
**Introduction:** Intramural Hematoma (IMH) and Penetrating Aortic Ulcers (PAU), two diseases that commonly have a fatal outcome, have been known since the early decades of the last century. Three modern imaging techniques have contributed to the better understanding of the development, natural history and diagnosis of these uncommon aortic pathologies: computerized angiotomography (CTA), magnetic resonance angiography (MRA) and transesophageal echography (TEE). Both these entities are classified today as atypical presentations of acute aortic dissections (AAD) and considered as part of the acute aortic syndromes (AAS). In fact, one in eight patients diagnosed with AAD, has either an IMH or a PAU. IMH is defined as a contained hemorrhage within the aortic layers, in the absence of a clearly detectable intimal tear. It originates from a ruptured vasa vasorum, followed by an aortic wall infarction, which in turn weakens and may rupture, resulting sometimes a classic AAD. However, there are well documented reports of IMH undergoing spontaneous resolution. Mortality is far higher when the IMH affects the ascending than the descending aorta. In PAU what occurs is a focal ulceration of an atherothrombotic plaque that penetrates the aortic wall with rupture of the internal elastic membrane and invasion of the media. Multiple ulcerations are exceedingly frequent. Several evolution are possible and unpredictable, such as embolization, aneurysm and pseudoaneurysm formation and aortic rupture. A particularly bad prognosis is a PAU with IMH. Because of the diffuse wall degeneration, a PAU rarely evolves into an AAD (AAD requires significant aortic wall integrity). Commonly the proximal descending aorta is the usual site of a PAU, but in fact, any segment of this artery can be affected. Patient that present themselves with IMH or PAU are usually older than those with classic AAD, the mean age being 74y.

**Diagnosis:** The symptoms of an IMH or PAU are similar to those of an AAD. Their presence and precise topography can only be established by imaging methods. In the hemodynamic unstable patient, TEE can be performed at bedside and is a very effective in establishing the presence of an IMH, as well as to establish the differential diagnosis with classic AAD. It also helps in the diagnostic of the type of AAD. Typical of PAU are crater like, irregular ulcerations, within severely atherosclerotic diseased. Multislice CTA is the most valuable imaging diagnostic tool for all AAD. In IMH, the diagnostic is established by presence of blood in the aortic wall and the lack of a tear or any communication to the aortic lumen. Classic in the diagnostic of PAU is the CTA finding of a pocket of contrast, which appears to be in the outside of the wall. The aorta adjacent to it is degenerated and calcified. The radiological finding of fluid surrounding the aorta is common. The findings of MRA are similar. Arteriography and intravascular ultrasound (IVUS) currently have only a very important role in the intra-operative setting.

**Indications and methods of treatment:** All patients must receive the best medical treatment available at admission. High risk but asymptomatic patients with IMH and PAU can probably be followed up without intervention. On the contrary, all symptomatic patients will need treatment, since the evolution is unpredictable and can be worse than with AAD. It is therefore clear the necessity to distinguish IMH and PAU from classic AAD. In many of these patients, a direct surgical approach is often prohibitive, due to age and multiple co-morbidities. Endoluminal based strategies broadened the therapeutic possibilities for IMH and PAU. IMH and PAU in the ascending and transverse aorta are rare. Currently the standard care for this entity is a direct surgical approach but endovascular treatment (EVT) for the same condition has been reported to have been successful. For this cases, either a direct implant or associated with supra-aortic debranching techniques have been used. The regularity of the lumen of the aorta in IMH and the limited segmental involvement in PAU make these pathologies ideal for EVT. Preserving the flow of the vital branches as well as covering all portions of grossly diseased aorta with the endoprosthesis is very important.

**Results:** Without treatment, the mortality for both pathologies is high – above 35% in IMH and 42% for PAU. Results published concerning PAU are more consistent than for IMH, possibly because the later is easily mixed with the overall results of AAD. Technical success above 95% and survival rates over 90% are reported with EVT for PAU. Paraplegia rates are low. Most publications reported a complete regression of the perigraft hematoma and/or hemothorax. Endoleak rates are low and reintervention was rare when the whole diseased segment is covered by the endograft. Regular follow-ups are essential.

**Conclusion:** IMH and PAU are variants of aortic dissection. They need a specific therapeutic approach, because without treatment they have a very poor evolution. EVT is becoming a recognized indication for patients with IMH and PAU and offers superior results. A multi-center trial to confirm the EVT approach to IMH is recommended.





George Silvaj

Mount Sinai School of Medicine, New York City - NY - USA

G. Silvaj, K.A. Plestis

Aortic surgery is a major insult to the organ subsystem and whole body homeostasis. Techniques utilized during repair of thoracic aortic aneurysm (TAA), e.g. prolong perfusion time, deep hypothermia, partial bypass, distal perfusion, circulatory arrest may further impair recovery. Improvements and progress in perioperative care including surgical, anesthesia, perfusion, monitoring and critical care management has resulted in favorable outcomes. Early diagnosis and treatment of TAA is of great importance and elective surgery in specialized institution have the best results. The type of treatment is dictated not only by location and extent of aortic disease, but also by underlying etiology, age and comorbidity of the patient. Recently, age is not a contraindication for repair of TAA.

The anesthetic approach to the patient with TAA depends on the urgency of repair. Symptomatic patients with leaking or ruptured aorta require emergent – instant, or urgent (up to 24 hours) surgical intervention. In such a situation there is little time to perform more than the most basic pre-operative assessment. Transesophageal echocardiography in the operating room may provide important information.

In the Aortic Symposium 2008 ([www.aats.org](http://www.aats.org)) Plestis et al reported a series of 219 patients treated in our institution for TAA (male 112; average age 66 years; emergency surgery in 30 patients). In the “Aortic Surgery and Anesthesia. How to do it” 2008 Congress in Milan we will present the perioperative management of a 70 year old male patient with dissection of an aortic aneurysm, Stanford type B. He was admitted with evidence of acute “sharp”, “ripping” and “stabbing” chest pain, with detection of pulse deficits on both lower extremities. The imaging studies documented recent enlargement of an aortic aneurysm in comparison to the previous study. A close communication with primary physician, surgeon and perfusionist is necessary to ensure optimal management. In this case we used: anesthetic techniques which do not interfere with monitoring of motor evoked potentials; one lung ventilation, mild systemic hypothermia; distal perfusion (heparin 3mg/kg; oxygenator, no reservoir, proximal pressure 110-130 mmHg); CSF drainage (catheter at L4-L5, pressure < 10 mmHg, continuous monitoring in ICU) and all laboratory tests and monitoring according our protocol for open heart surgery. In postoperative care mean arterial pressure is kept between 85 – 95 mmHg and avoidance of elevated CVP and prevention of hypoxemia and anemia.

Airway management & monitoring:

- Double lumen ETT

- TEE

- Esophageal temp

- Jugular bulb catheter

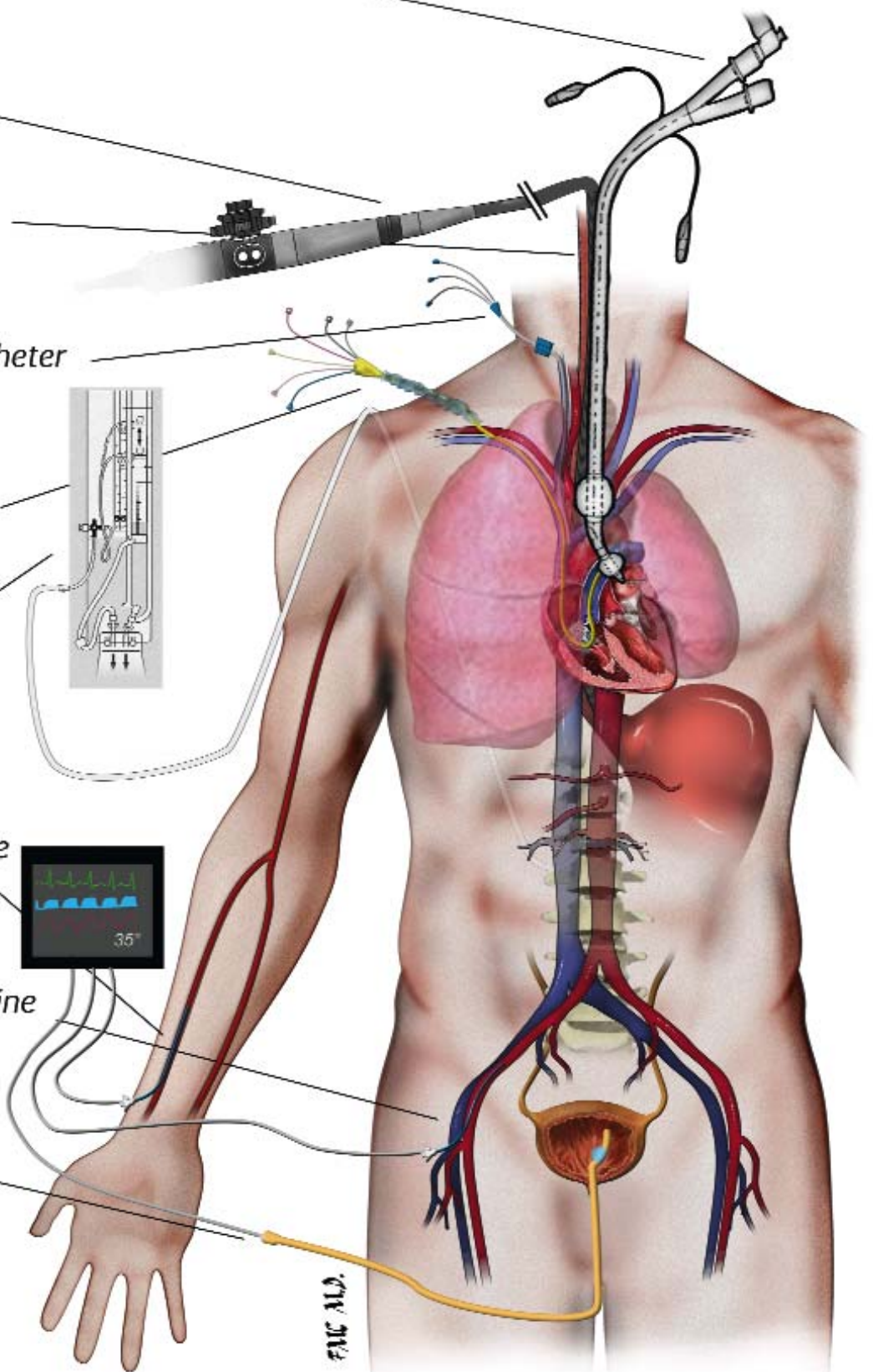
- Pulmonary artery catheter

- CSFD

- Right radial A-line

- Right femoral A-line

- Bladder temp



# MORE TREATMENT OPTIONS FOR RUPTURED AAA: ARE WE SAVING MORE LIVES?

**Timothy Resch**  
*Vascular Center Malmö-Lund - Sweden*  
M. Malina, F. Veith, J. Holst, T. Resch, B. Sonesson

Emergency endovascular aneurysm repair (eEVAR) has been applied to ruptured abdominal aortic aneurysms (rAAA) for more than a decade. Yet, there is no firm scientific proof of its superiority over traditional open repair (OR) except for retrospective, non-randomized case series accused of “cherry picking” the favourable cases. Prospective randomised trials seem difficult to conduct and only very limited data are available suggesting no clear benefit from eEVAR in rAAA. The mortality rate in our own series of 100 eEVARs has gradually increased from under 20% to currently almost 30%.

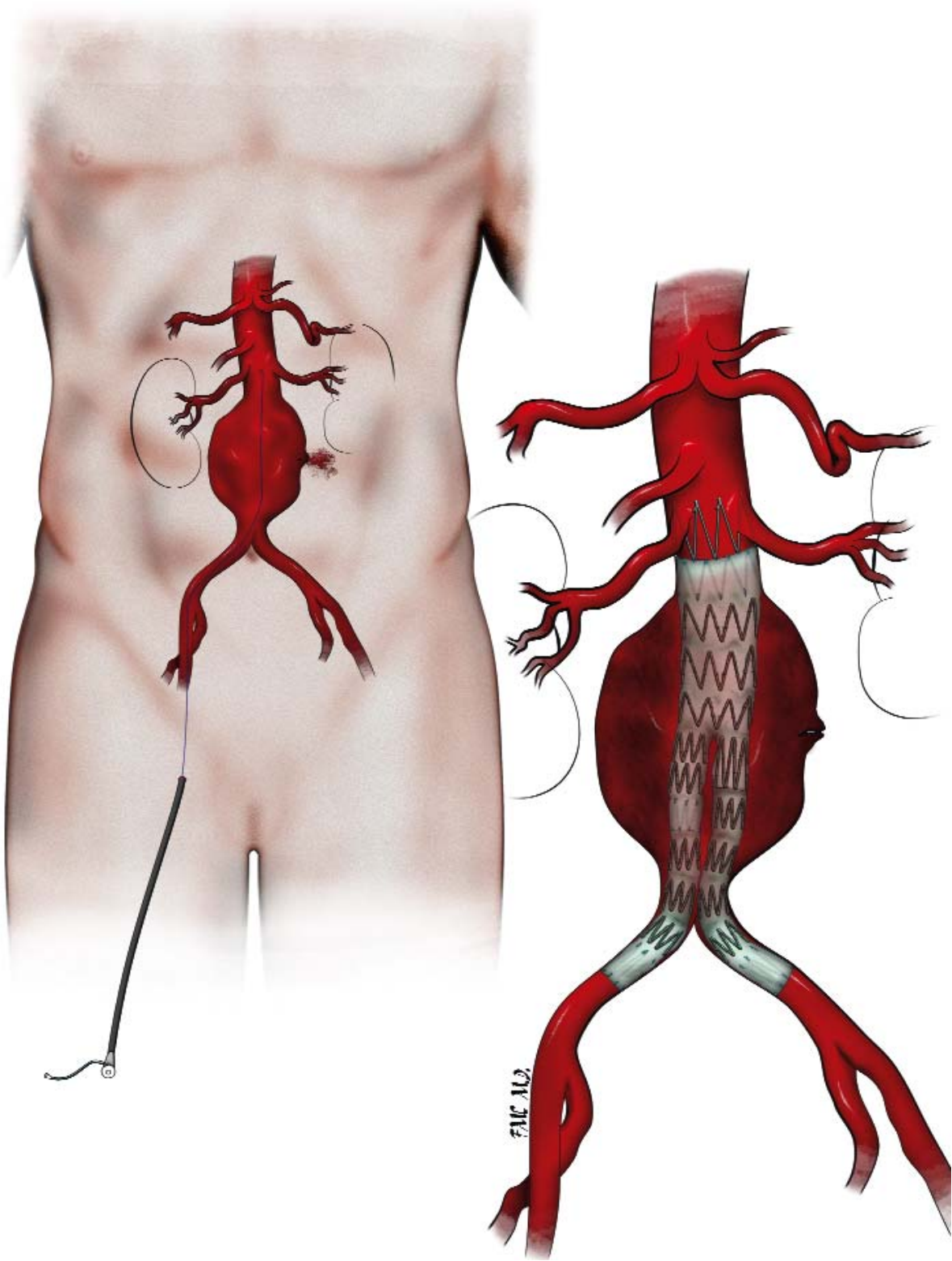
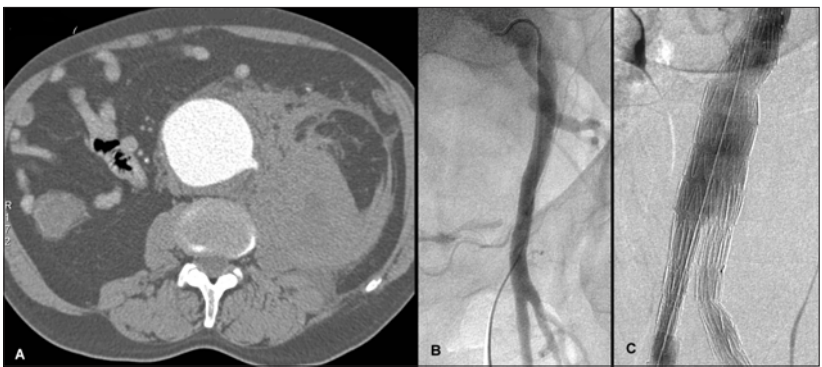
The question whether we actually save more lives may, therefore, seem appropriate. Yet, sometimes we need to rely on reasoning rather than accurate data. Most known facts about patients with a rAAA are in favour of EVAR. These patients:

- Require urgent haemostasis. There is no doubt that haemostasis can be efficiently obtained with EVAR.
- Tolerate surgical trauma poorly. EVAR reduces the surgical trauma significantly.
- Tolerate general anaesthesia poorly. eEVAR is preferably performed under local anaesthesia.
- Will bleed more upon abdominal depressurization during laparotomy. eEVAR avoids laparotomy.
- Must avoid further blood loss. eEVAR is performed without external haemorrhage.
- May need instant aortic cross-clamping. Transfemoral inflation of an aortic balloon catheter under local anaesthesia is quicker and simpler than conventional aortic cross-clamp in most hands.
- Preoperative CT is performed in most patients also in centres that do not offer eEVAR.

Will the mortality of eEVAR be lower than of OR? Hardly. The indications to treat rAAA expand. We will treat more increasingly sick patients until similar mortality of eEVAR and OR is obtained. It is simply hard to deny any patient an intervention under local anaesthesia if the patient is about to die from a rAAA.

Some juxta-renal rAAAs cannot be treated with conventional eEVAR. Instant, home-made fenestrations and chimney grafts are novel technologies that expand the indications for eEVAR in such cases. While the complication rate from these techniques is higher than for conventional EVAR we must recognize that these patients are at even higher risk from OR.

In conclusion; “No prospective randomized trial is needed to prove the efficacy of the parachute”. This also applies to eEVAR although the mortality rates may suggest otherwise.







'08

SCIENTIFIC ABSTRACTS

ENDOVASCULAR TREATMENT II

*Charimen:* Alessandro Del Maschio, Guido Fanelli, Gino Gerosa, Piergiorgio Settembrini

BALLOON EXPANDABLE TRANS-CATHETER AORTIC VALVE IMPLANTATION	Antonio Colombo Discussant: Francesco Maisano
ADVANCED IMAGING TECHNIQUES IN THE EVALUATION OF PATIENTS FOR TRANS-FEMORAL AORTIC VALVE IMPLANTATION	Pietro Spagnolo Discussant: Luigi Inglese
LOCO REGIONAL VERSUS GENERAL ANESTHESIA IN ENDOVASCULAR SURGERY	F. Luca Lorini Discussant: Elena Bignami
NON INVASIVE HAEMODYNAMIC MONITORING	Erminio Sisillo Discussant: Rosalba Tufano
BRANCHED ENDOGRAFTS FOR THORACO-ABDOMINAL ANEURYSM REPAIR	Roy K. Greenberg Discussant: Domenico Palombo
FENESTRATED AND BRANCHED ENDOGRAFT FOR THE TREATMENT OF JUXTARENAL AND THORACO-ABDOMINAL AORTIC ANEURYSMS	Claudio S. Cinà Discussant: Giancarlo Palasciano
SUPRARENAL FIXATION, FENESTRATION, BRANCHING; WHAT IS THE LONG TERM FATE OF THE TARGET VESSELS?	Fabio Verzini Discussant: Maurizio Taurino
STATE-OF-THE-ART IMAGING OF AORTIC ANEURYSMS AND POST-PROCESSING; DOES IT INFLUENCE INDICATIONS AND PLANNING?	Giovanni Gandini Discussant: Bruno Gossetti

# BALLON EXPANDABLE TRANS-CATHETER AORTIC VALVE IMPLANTATION

Antonio Colombo  
San Raffaele Scientific Institute, Milano - Italy

Since the first percutaneous implantation of an aortic valve performed by dr. Alan Cribier on April 16, 2002 utilizing an anterograde approach through transeptal puncture the field evolved quite a lot. Currently two prosthetic aortic valves obtained CE mark and are commercially available, each of them has up to now been implanted in over 1000 patients. The Cribier balloon expandable valve originally by Percutaneous Valve Technologies and with leaflets made of equine pericardium is now the Edwards Sapien valve (Edwards Lifesciences, Irvine, CA) with bovine leaflets treated with anticalcification methodology and is available for transfemoral or transapical implantation. This valve is made in two diameters 23 mm (for aortic annulus from 18 to 21 mm) and 26 mm (for aortic annulus from 22 to 24 mm) and needs a 22 F and 24 F sheath respectively. The common femoral artery can be accessed surgically or percutaneously with percutaneous suture closure system (Prostar). When the iliofemoral anatomy does not allow the introduction of these size sheaths a transapical approach can be utilized (presently over 200 patients treated).

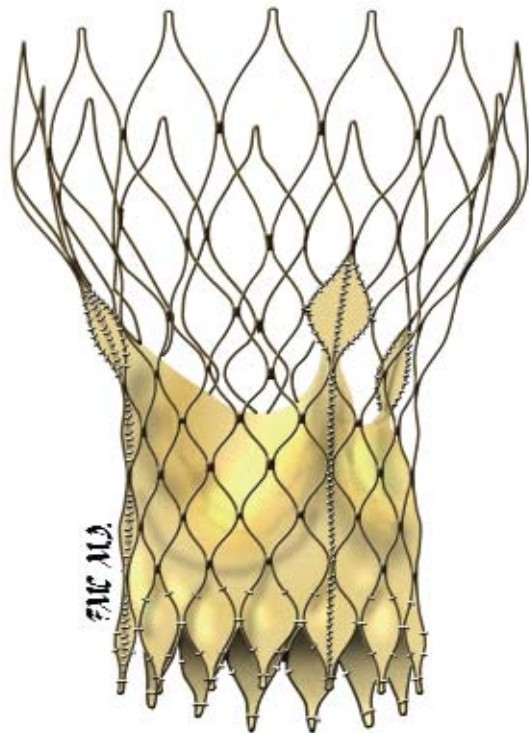
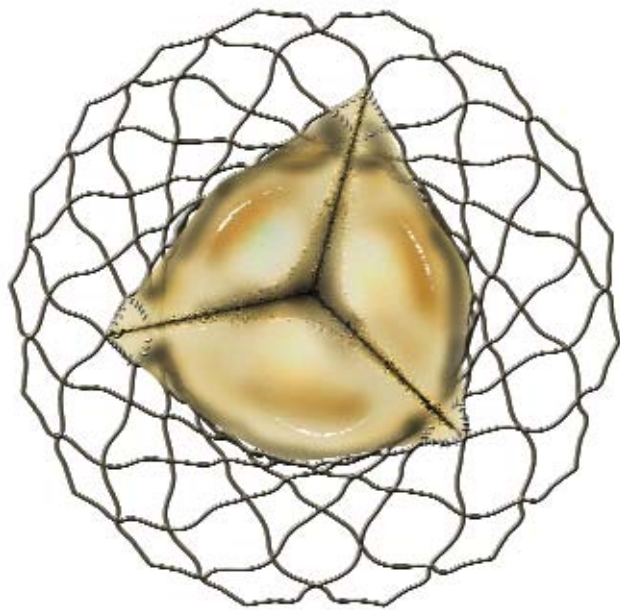
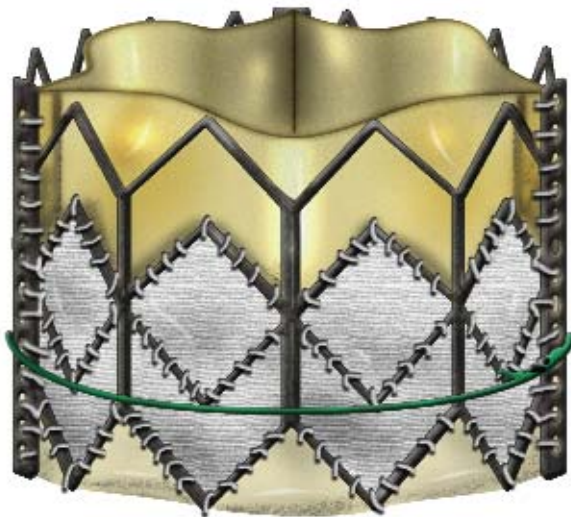
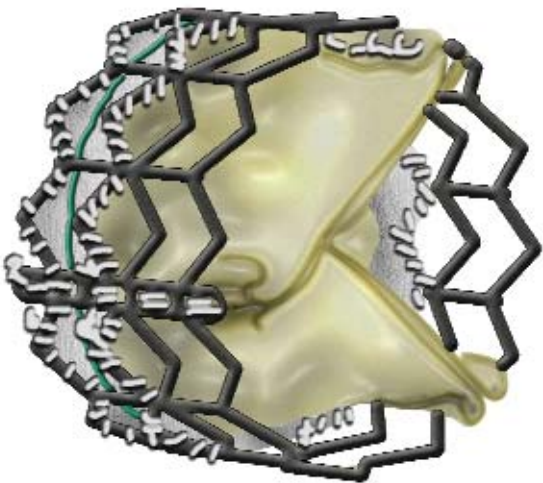
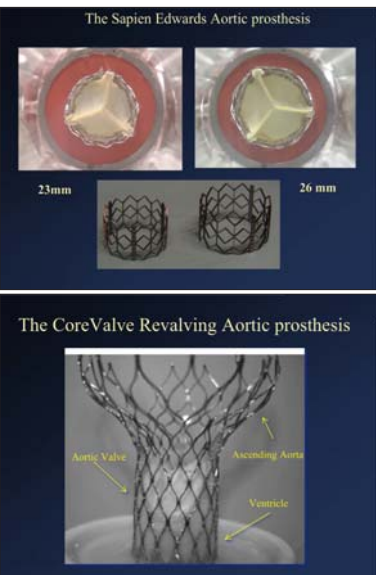
The CoreValve Revalving aortic valve made by Corevalve (Irvine, CA) is a self expanding prosthesis made with porcine pericardium. Presently more than 1700 implants have been performed with the CoreValve and follow-up is over 2 years. The CoreValve is currently available in 2 sizes: 26 mm prosthesis for aortic valve annulus from 20 to 24 mm and a 29 mm prosthesis for aortic valve annulus from 24 to 27 mm. The CoreValve originally with a delivery system of 24 F is now available with a delivery sheath of 18 F allowing treatment of patients with smaller iliofemoral vessels compared to the current Edwards device.

The patients treated with both valve were initially subjects with almost absolute surgical contraindications and very high surgical mortality it is therefore incorrect to quote a global complication rate or success. Presently with treatment of patients with a surgical mortality between 10 and 20 % (Logistic Euroscore) by traditional aortic valve surgical replacement we can state that with either of the two valves the average implantation success is over 90% with a 30 days mortality lower than 10%.

At San Raffaele Hospital 18 patients underwent successful implantation of a Edwards / Sapien™ valve. Valve annulus was  $22.9 \pm 1.7$ ; 9 pts received a 23 mm valve and 9 patients 26 mm valve. Procedural time was  $204 \pm 54$  minutes. Radiation dose was  $297 \text{ Gy cm}^2 \pm 132$ , contrast was  $\text{ml.} 358 \pm 111$ . Femoral access was surgically prepared in 3 pts and total percutaneous in 13 pts. No pts required cardiopulmonary support. General anesthesia was used in 13 pts (in 2 pts it was initiated after occurrence of complications). Hemodynamic of the implanted valve was satisfactory in all pts, with abolishment of the gradients (echo evaluation) and mean aortic regurgitation grade  $1, 17 \pm 0,4$ , with no pts having severe regurgitation (echo and angiographic evaluation).

Thirty days survival was 100%. One patient who was taking immunosuppressive therapy died in 58 pod for sepsis and multi organ failure. There were 6 complications: 3 iliac access complications requiring endovascular treatment, 1 femoral complication requiring surgical revision, one stroke, partially resolved at discharge, 1 acute renal failure required ultrafiltration, 1 peripheral femoral embolization resolved with balloon angioplasty.

TAVI is a promising opportunity to treat high risk patients with severe symptomatic aortic stenosis. Rigorous screening is mandatory to select the best candidates, both for procedural success and for avoidance of complications. Advancements in transcatheter technologies and introduction of new and smaller devices will expand the indications and reduce the rate of complications of transfemoral TAVI.





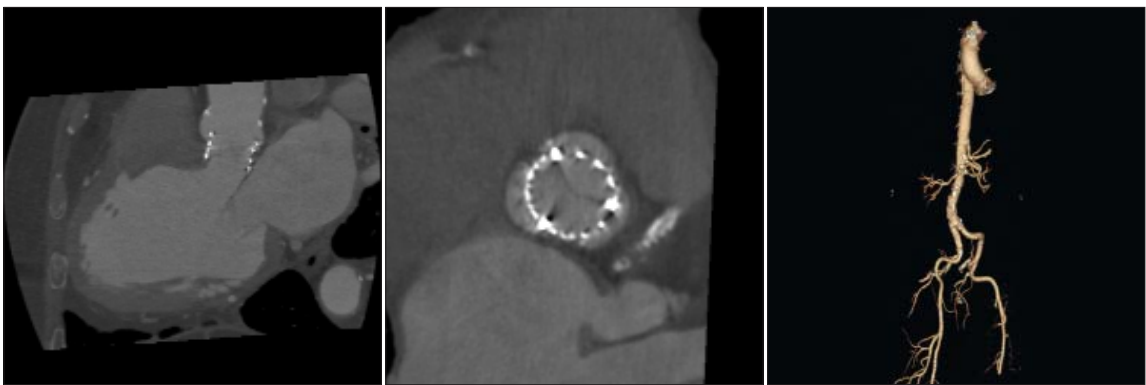
# ADVANCED IMAGING TECHNIQUES IN THE EVALUATION OF PATIENTS FOR TRANS-FEMORAL AORTIC VALVE IMPLANTATION

Pietro Spagnolo  
*San Raffaele Scientific Institute, Milano - Italy*

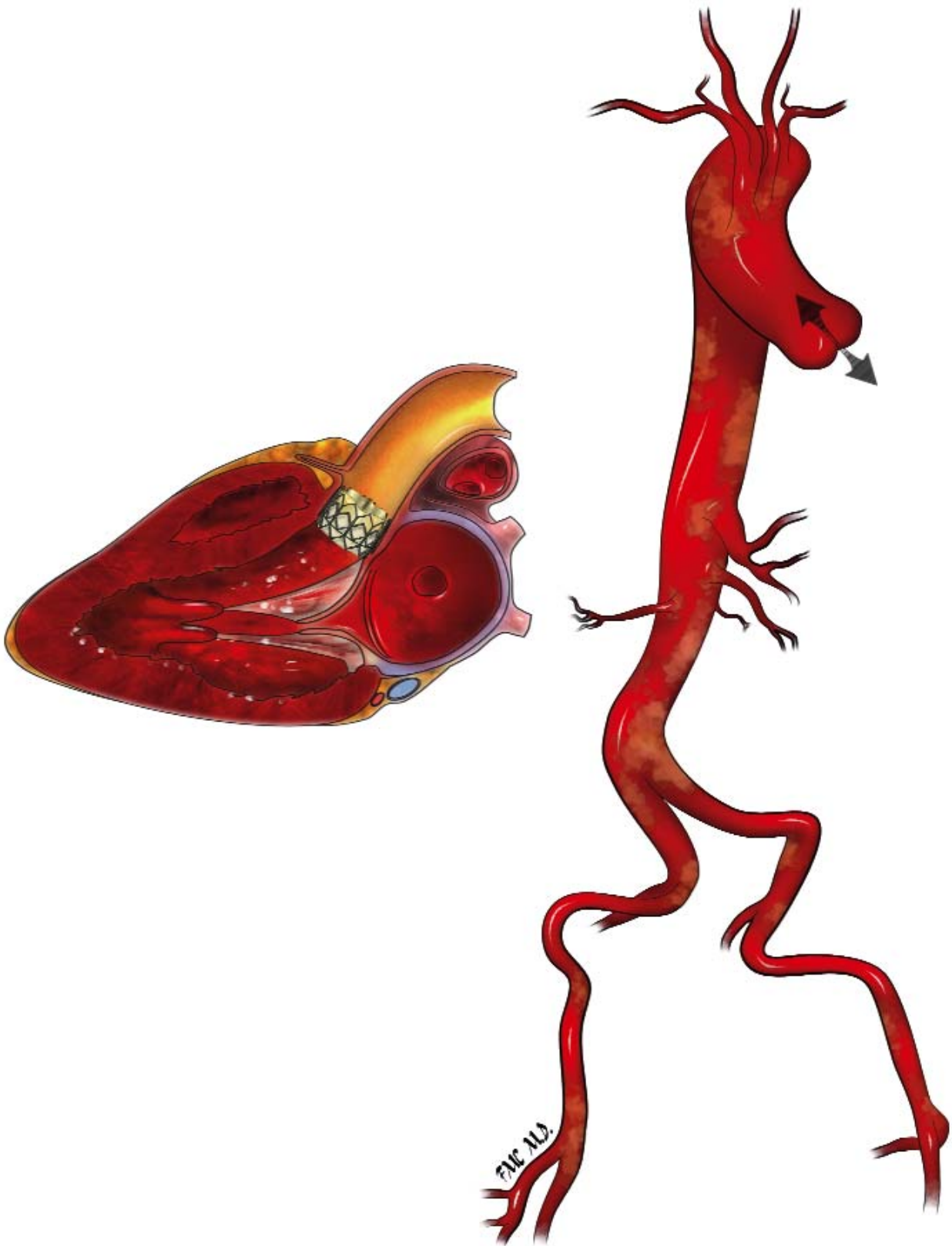
Availability of preoperative proper imaging techniques is a key component in the success of transcatheter endovascular aortic valve implantation (TAVI). Several techniques such as echocardiography, conventional angiography and fluoroscopy play an important role for diagnostic, preoperative planning of patients.

64-slice multidetector computed tomography (64 MDCT) is an emerging new imaging technique in the evaluation of patients scheduled for trans-femoral aortic valve implantation. It enables the determination of ventricular function, diameter of the left ventricular outflow tract, annulus size and aortic valve area. Thus, thanks to its high spatial resolution, non-invasivity and high reproducibility of measurements can provide excellent images, helping to correctly choose the ideal device size for a specific patient. Correct sizing is crucial in preventing device embolization and in minimizing the degree of paravalvular leaks.

With the same examination it's possible to visualize the coronary arteries and to detect significant coronary lesions with an excellent correlation with conventional coronary angiography. MDCT craniocaudal volume goes from the level of the aortic arch down to the femoral vessels allowing the simultaneous visualization of aorta and peripheral vessels and the detection of peripheral vascular disease (small, tortuous and severely calcified vessels) in the subgroup of patients candidates to the alternative approach through the left ventricular apex (transapical TAVR).



Endovascular Treatment II



# LOCO REGIONAL VERSUS GENERAL ANESTHESIA IN ENDOVASCULAR SURGERY

F. Luca Lorini

*Ospedali Riuniti di Bergamo - Italy*

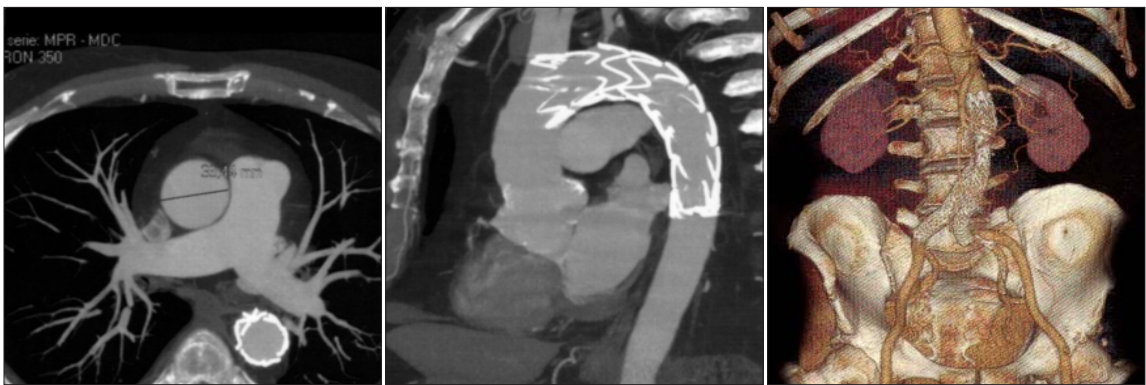
F. L. Lorini, M. Lagrotta, F. Ferri, G. Di Dedda, O. Valsecchi, L. Aiazzi

**Introduction:** Local and regional anesthesia were used in endovascular aortic aneurysm repair (EVAR) shortly after its introduction. Nonetheless, locoregional anesthesia is not accepted on a large scale, probably due to a traditional surgical attitude preferring general anesthesia. Aim of this study is to compare various anesthesia techniques in patients undergoing EVAR for thoracic and abdominal aortic aneurysms.

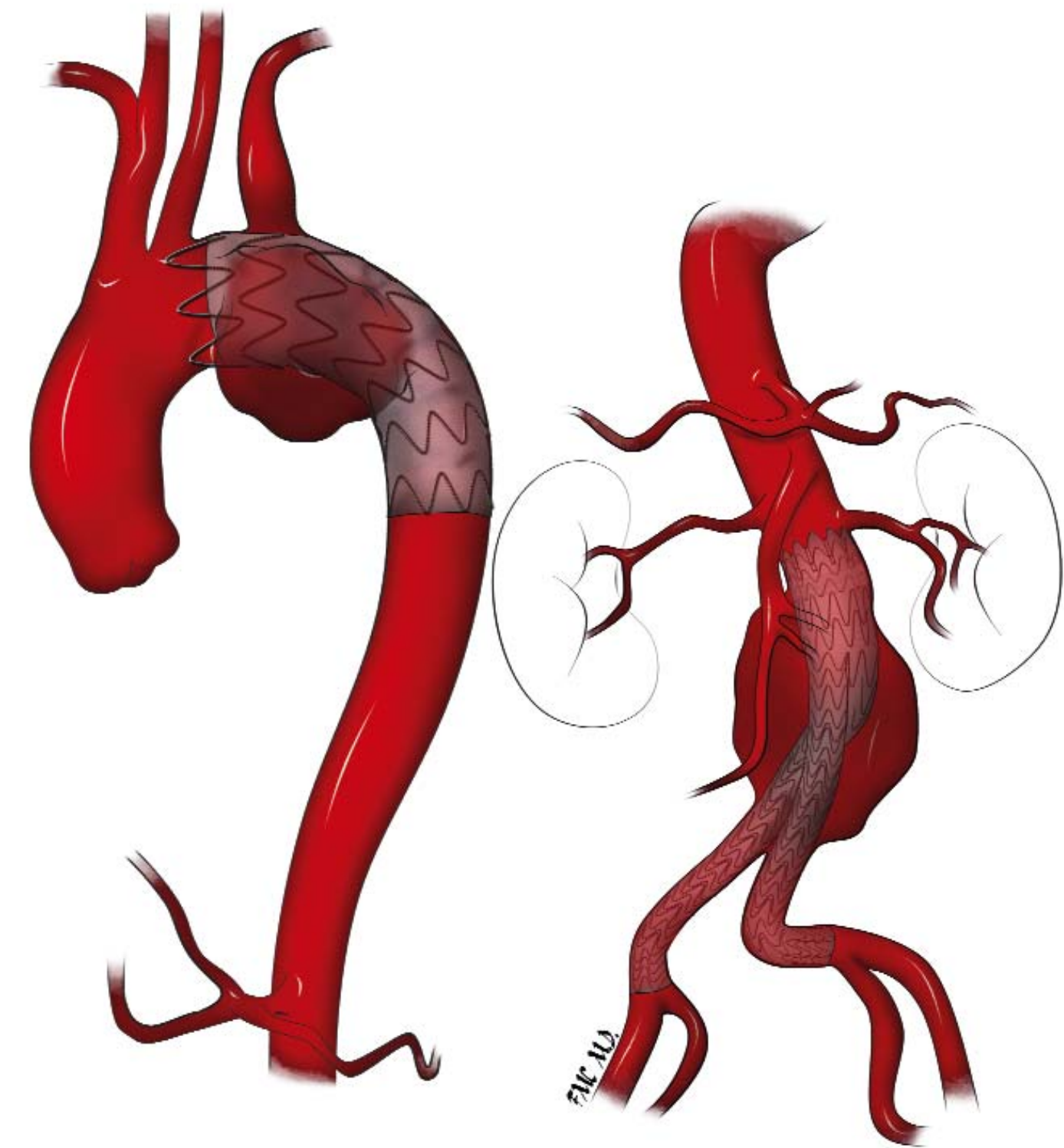
**Methods:** From April 2001 to June 2008, 175 patients (ASA II-III) were treated at our institution with EVAR for thoracic and abdominal aortic aneurysms. Data were compared among three groups: a general anesthesia group of 87 patients (50%), a loco regional anesthesia group of 52 patients (30%), and the local anesthesia group of 35 patients (20%).

**Results:** The surgical time of the procedure was reduced under local and loco regional regimen compared to general anesthesia. Length of hospital stay was 8 days in the general anesthesia group vs 6 days in the loco-regional anesthesia group vs 3 days in the local anesthesia group. No major intraoperative complications related to anesthesia technique were observed in the three groups. No conversions from local and regional to general anesthesia were needed. Greater hemodynamic stability was observed during local anesthesia. The same happened for cardiac, renal and wound healing complications.

**Conclusions:** The data demonstrate that patients appeared to benefit when a local or a loco regional anesthesia was performed for EVAR.



Endovascular Treatment II





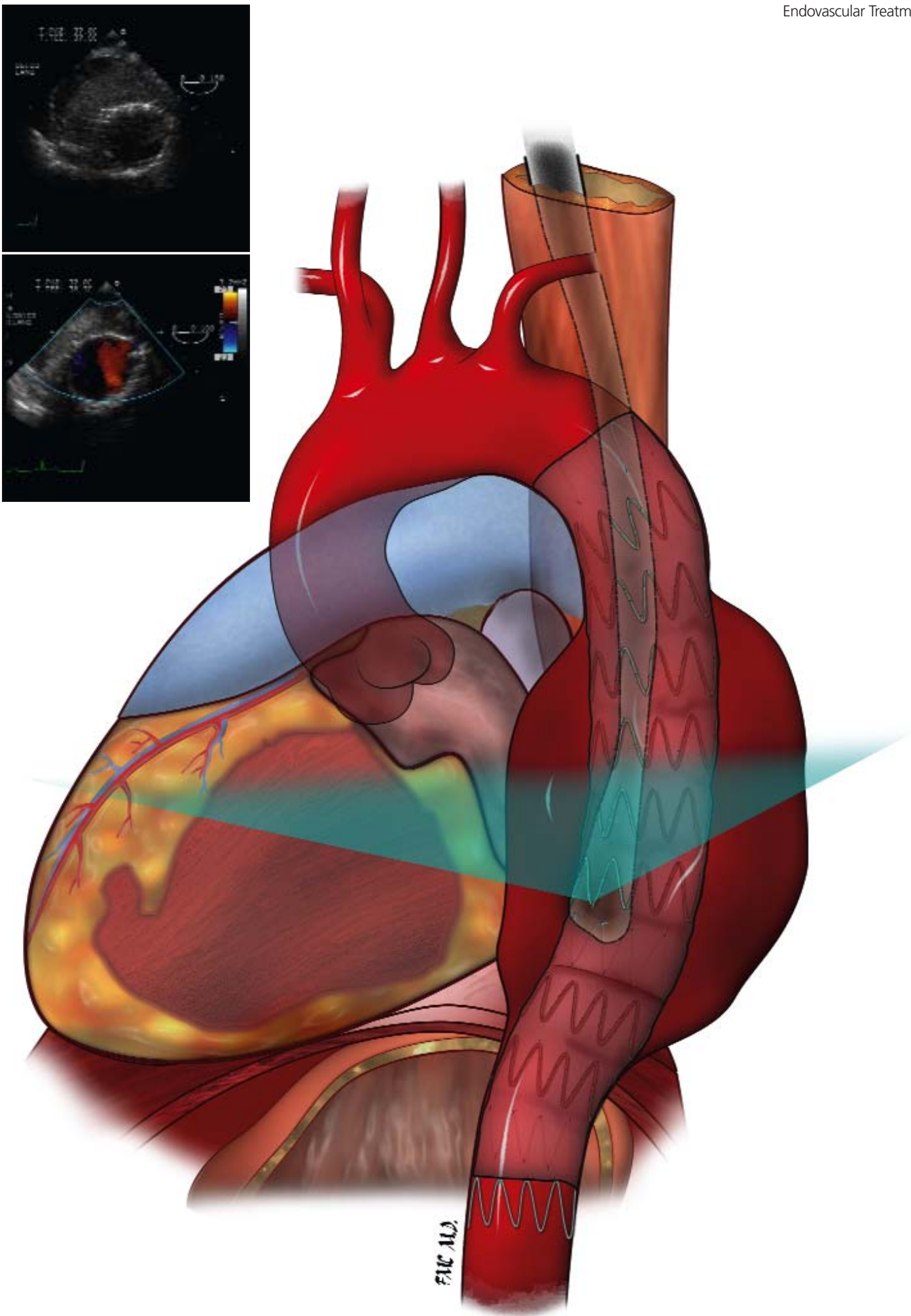
**Erminio Sisillo**  
*Centro Cardiologico Monzino, Milano - Italy*

Starting from 1991 endovascular aneurysm repair (EVAR) has gained progressive acceptance as an alternative technique to treat aortic aneurysms. EVAR may in effect reduce perioperative mortality and morbidity, decreasing intensive care unit and total hospital length of stay and allowing a more rapid recovery time. Due to its less invasive nature when compared with open surgery, EVAR has become an attractive option for patients with aortic aneurysms, and often the only option for very elderly patients and for patients with multiple organ dysfunction. During the procedure hemodynamic stability is the primary goal for stent graft placement to preserve organ function mainly in those patients where important comorbid conditions are present. Hemodynamic stability can be influenced by various factors: anesthesia technique and conduction, filling conditions, prolonged effect of preoperative medications and, of course, cardiac function. As the sickest patients may not tolerate hemodynamic changes, it is mandatory to provide at least a minimal invasive monitoring such as an arterial catheter. Actually different pulse-contour analysis methods of the arterial tracing can provide a real-time beat by beat monitoring of important hemodynamic parameters such as cardiac output (CO) and systemic vascular resistences (SVR). Among them, the PiCCO and the LiDCO are the most diffuse ones. They both need an initial termodilution set up (the first one with an iced saline bolus injected in a central vein the second one with a single bolus of litium solution), although the LiDCO does not necessitate of a dedicated arterial catether nor of a central venous access. Both systems are largely utilized in a wide series of application and are able to derive indirect parameters of cardiac function, like the stroke and pressure volume variation (SVV- PVV), the dp/dt max, which can be important in maintain adequate filling in this setting.

The only real non-invasive method to monitor hemodynamics is, however, the Impedance Cardiography (ICG). Based on the variations of thoracic electrical bioimpedance, due to the variations of thoracic fluid status and blood flow in the aorta, this systems requires the placement of several electrodes on the thorax and neck and the application of alternating current through them. The system can then derive, with different equations in conjunction with some others data (height, weight, surface ECG), the CO the SVR, the pre-ejection period (PEP), the left ventricular eject time (LVET) the systolic time ratio (PEP/LVET). However, published studies demonstrate that more data are necessary, mainly on cardiovascular patients, before a wider use of ICG could be recommended.

Finally, during EVAR procedures involving thoracic aorta aneurysms, the most effective monitoring can be achieved with the use of transesophageal echocardiography (TEE). Different papers in the literature have shown the benefits of TEE in this setting. In fact, TEE can document endoleaks that were missed by angiography immediately after the procedure, and can also continously monitor cardiac performance. By analyzing TEE images, the anesthesiologist has a direct and continous representation not only of cardiac kinetics, but also of the cardiac chambers filling and valves function. All these elements can be utilized to maintain and optimize the hemodynamic performance of the patient.

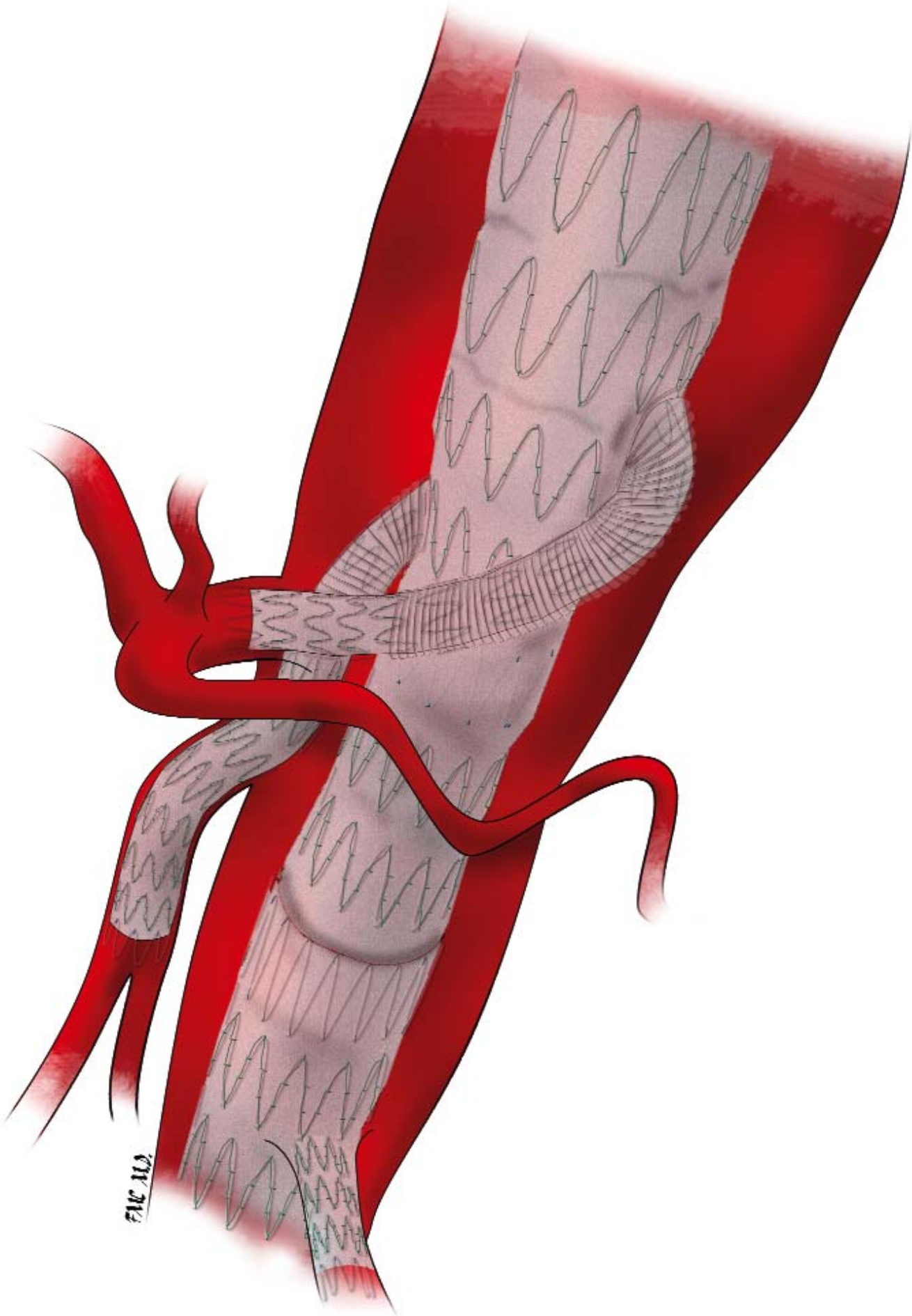References  
Parodi JC, Palmaz JC, Borone BD: Ann Vasc Surg 1991, 5:491-499  
Wang DJ, Gottlieb SS: Cur Cardiol Rep 2006, 8:180-186  
Fattori R, Caldarera I, Rapezzi C et al: J.Thorac.Cardiovasc Surg 2000, 120:490-5  
Jonas M , Tanser S: Cur Opin Crit Care . 2002, 8:257-261.  
Godje O, Hoke K, Fischlein T, et al: Care Med 22 (Suppl. 1): S58, 1996



# BRANCHED ENDOGRAFTS FOR THORACO-ABDOMINAL ANEURYSM REPAIR

**Roy K. Greenberg**  
*Cleveland Clinic Foundation - OH - USA*  
T.M. Mastracci, R.K. Greenberg

Open treatment for thoracoabdominal aneurysms (TAAA) was first described in 1955 and has undergone multiple iterations to reach its current status. Open surgical repair performs well in high volume centres in very low medical risk patients. For the remainder of the population, conventional treatment falls short, but an alternate approach, involving endovascular techniques, has been described. This minimally invasive approach has also undergone an evolution, and has developed from a purely fenestrated device to one that uses branches engineered to maximize stent overlap, accommodate a wider spectrum of disease, and in so doing, allow for treatment of an increasing cohort of patients and anatomy. Our group has demonstrated that outcomes for branched endografts in high risk patients are equivalent to open repair in healthier subjects. However, the same caveats for interventions are described in these patients, including a risk of perioperative mortality, spinal cord ischemia, coagulopathy and renal failure. Requisite follow up is necessary for ongoing surveillance and for determination of durability of the technique. Our approach to the thoracoabdominal aorta must reflect knowledge of the ongoing evolution, and specific characteristics of the current endovascular devices, but also consider the continuum of connective tissue disorders that may have ramifications on the success of repair. This talk will review outcomes for branched endovascular repair of TAAA, our experience with the current devices, and relevant considerations for device development in the future.





# FENESTRATED AND BRANCHED ENDOGRAFT FOR THE TREATMENT OF JUXTARENAL AND THORACO-ABDOMINAL AORTIC ANEURYSMS

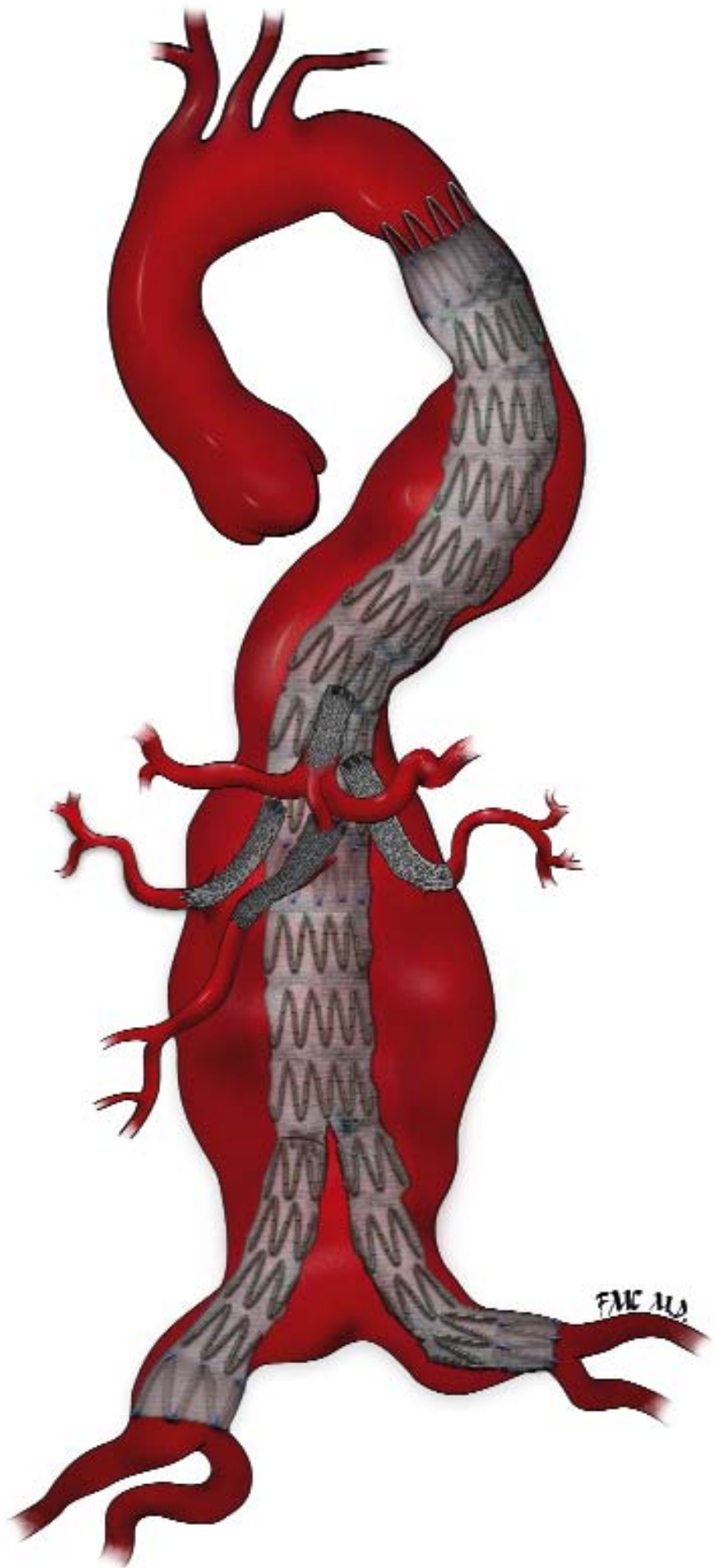
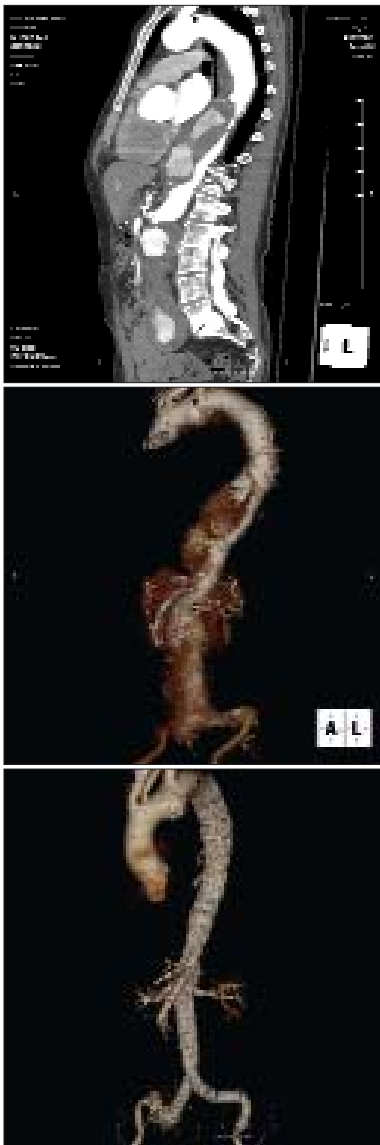Claudio S. Cinà  
St Michael's Hospital, University of Toronto - ON - Canada

Introduction: Fenestrated and branched endografts (FBEG) are used for the treatment of juxtarenal (JRA) and thoracoabdominal aneurysms (TAAA). Greater complexity sets these surgeries apart from infrarenal endovascular aneurysms repair (EVAR). Recognizing that this is an evolving and complex technology, we present our current experience and a step by step approach to the surgical technique

Methods: Between July 2005 and June 2008, we performed 275 EVAR and 14 FBGE. Planning was done using volumetric contrast enhanced computerized tomography (CT) with a 64 slice scanner and image post processing with the TeraRecon Aquarius workstation. Interventions were classified in those using fenestrated devices with bare stents, fenestrated devices with covered stents, or branched devices. Primary outcomes were mortality, dialysis, and paraplegia. Secondary outcomes were renal dysfunction (>30% increase in preoperative Cr); technical failure defined as the intra-operative loss of a target artery; length of stay (LOS) in hospital and in ICU; red cell transfusions, and dye volume.

Results: We used three branched devices and 11 fenestrated (7 using covered stents). One patient died on the 5th postoperative day of myocardial infarction (mortality 7%) and one patient developed transient paraplegia on the second postoperative day. Renal dysfunction was observed in 25% of patients but none received dialysis. There were a total of 51 possible target vessels: 10 in the branched and 41 in the fenestrated devices, respectively. One aberrant renal artery originating from within the aneurysm sac and revascularized with a retrograde branch, was lost. The volume of radiographic contrast used was  $229 \pm 53\text{mL}$ . None of the patients with fenestrated devices went in ICU, and the LOS in hospital was  $1.9 \pm 0.7$  days. In the three patients with branched devices, the LOS in ICU was  $8 \pm 7$  and in hospital  $13 \pm 12$  days, respectively. At an average follow up of  $14 \pm 6$  months, one type III endoleak developed, due to separation of the bifurcated from the fenestrated component, and one renal artery occluded.

Conclusions: FBEG are a realistic option for the treatment of JRA and TAAA. Results compare well with the traditional open approach particularly if we consider the fenestrated devices. The difference reflects the management of simpler disease than TAAA. Specific training, attention to details, and appropriate resources are necessary to achieve good results.



# SUPRARENAL FIXATION, FENESTRATION, BRANCHING; WHAT IS THE LONG-TERM FATE OF THE TARGET VESSELS?

Fabio Verzini

*Ospedale Santa Maria della Misericordia, Perugia - Italy*

F. Verzini, G. Panuccio, G. Parlani, L. Romano, R. De Prisco, P. Cao

Introduction: With the increasing diffusion of endovascular treatment (EVAR) of abdominal aortic aneurysms (AAA), the use of suprarenal fixation as well as fenestrated and branched endografts is more often required to address patients with challenging anatomies of proximal necks. Safety of endografts with suprarenal bare stent in preserving renal function has been studied in several small series and recently evaluated in an inconclusive meta-analysis, while long-term data on patients with visceral side branched endografts are still scarce, due to the recent adoption of the technique. One of the most feared complications is undoubtedly the occlusion of the visceral vessels due to plaque evolution at the ostia, partially covered by the aortic stent struts, or visceral stent occlusion in case of side branches.

Aim of the present study is to review our single centre series of EVAR with suprarenal fixation endografts to evaluate the incidence of visceral artery occlusion after treatment, and report the risk of visceral ischemia in our preliminary experience of fenestrated and branched endografts for the treatment of pararenal and thoraco-abdominal aneurysms.

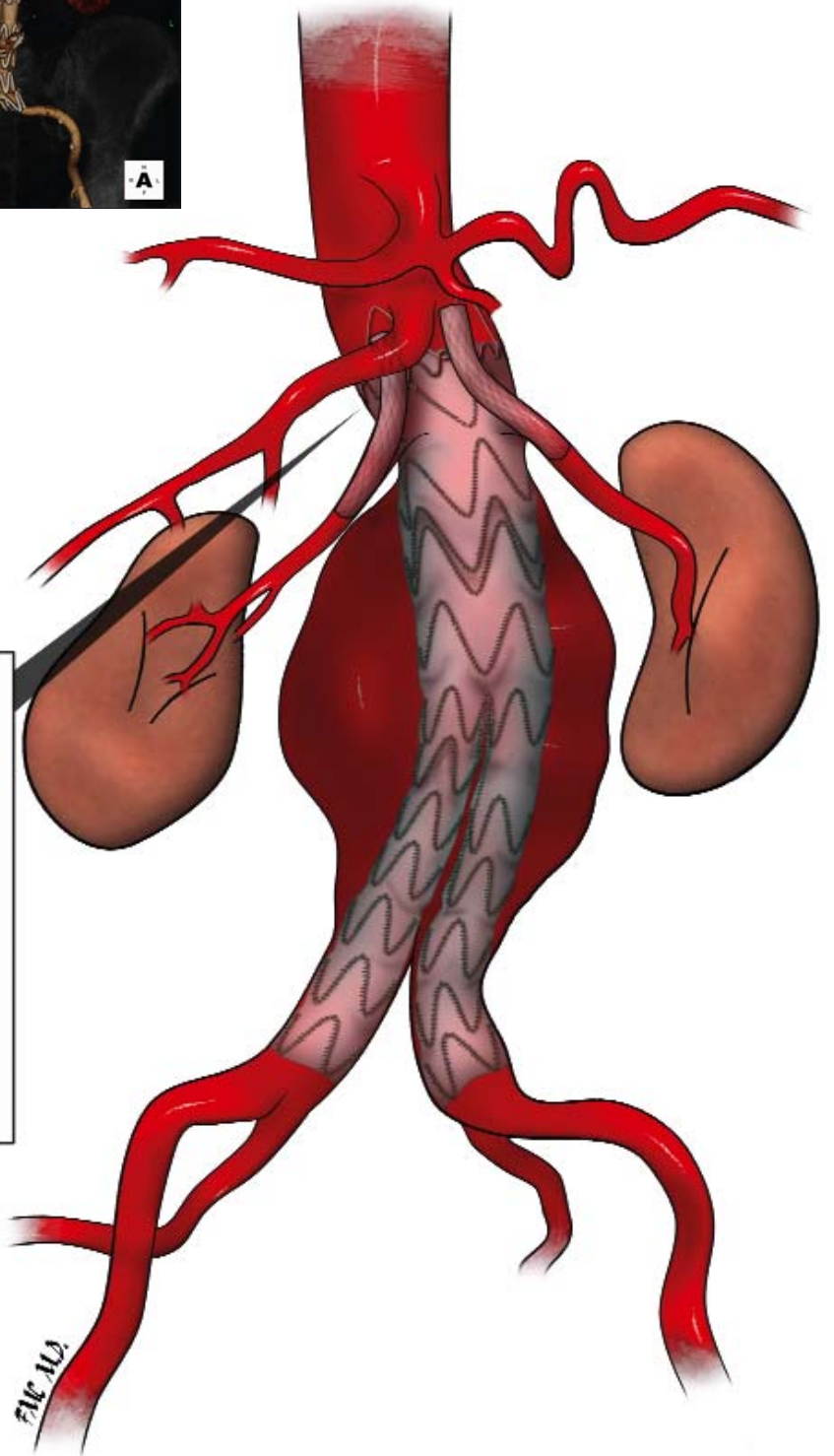
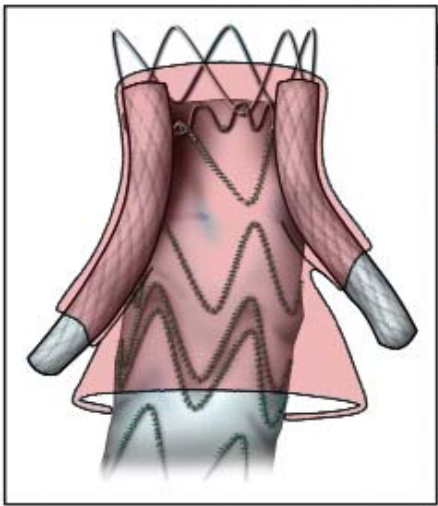
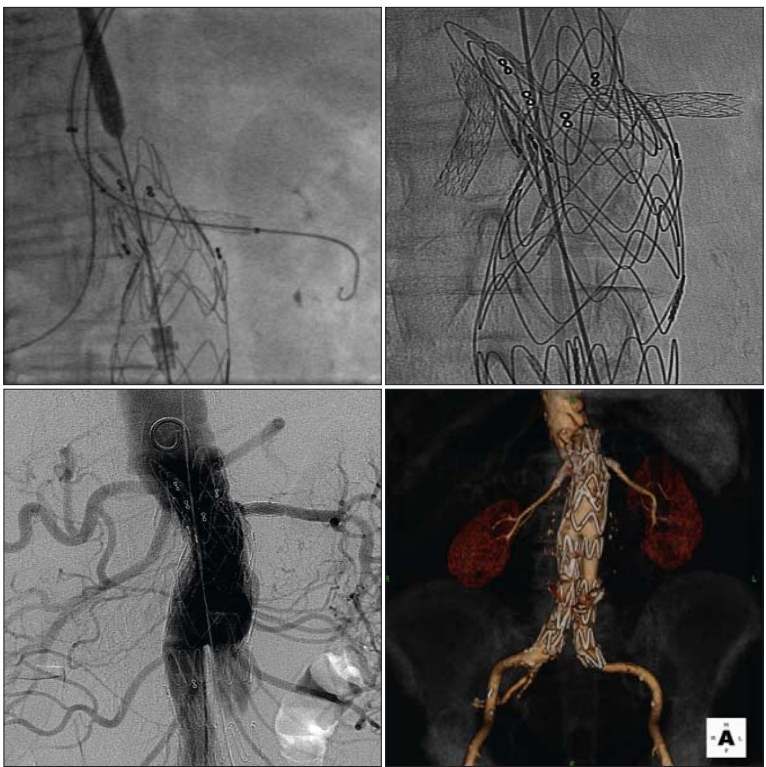
Methods: Between April 1997 and June 2008, among 1096 patients treated with EVAR in our centre, 667 supra-renal fixation endografts were used. Moreover, in the last 3 years, 27 patients received a fenestrated endograft for pararenal aortic aneurysm treatment and 7 branched grafts were used for thoraco-abdominal aneurysms.

Results: After EVAR with standard endografts, 10 deaths occurred in the first 30 days or during the same hospitalization after the procedure, accounting for an immediate mortality of 1.0%; conversion to open repair occurred in 10 patients (1.0%). Renal artery stenosis or occlusion was recorded intraoperatively or in the immediate postoperative period in 16 patients, without significant difference in patients with or without suprarenal fixation endografts; ten patients underwent successful renal artery revascularization, therefore incidence of postoperative renal occlusion resulted 0.6%. At a mean follow-up of 37 months, AAA-related death is 1.3% and reinterventions have been required in 93 patients (9.3%). Late renal occlusions have been detected in 3 patients and 3 other patients required chronic haemodialysis without signs of renal artery occlusion.

In patients with fenestrated and branched endografts, renal occlusion has been recorded immediately after treatment in 2 patients, while no celiac or superior mesenteric artery stents occlusions were detected. At a mean follow-up of 6 months, only 1 stented renal artery occluded and the endovascular attempt to rescue it failed. No patient in this group needed chronic haemodialytic treatment.

Conclusion: Incidence of renal artery occlusion after suprarenal fixation endografting for AAA treatment is infrequent and not superior than with infrarenal fixation endografts. The effect of suprarenal fixation on long-term renal function is still insufficiently studied, but available data support the continuous use of such endograft models.

Visceral ischemic complications after fenestrated and branched aortic endografts are still under close evaluation: mid-term outcomes in selected cases show promising results. Close monitoring in longer and wider experiences will establish the true role of this therapy for the treatment of suprarenal and thoraco-abdominal aneurysm.





# STATE-OF-THE-ART IMAGING OF AORTIC ANEURYSMS AND POST-PROCESSING; DOES IT INFLUENCE INDICATIONS AND PLANNING?

Giovanni Gandini

Università degli Studi di Torino - Italy

G. Gandini, M.C. Cassinis

Aortic disease is associated with high morbidity and mortality and thus require an efficient and accurate diagnostic approach, especially in the acute setting.

Conventionally angiography has long been the preferred technique for evaluating aortic aneurysms, but now has been worldwide replaced by CT Angiography (CTA) or MR Angiography (MRA).

With the recent introduction of multidetector computed tomography (MDCT) that provides high-resolution axial images with optimal contrast enhancement and advanced post-processing capabilities, CTA of the entire vascular system is possible in a very short time.

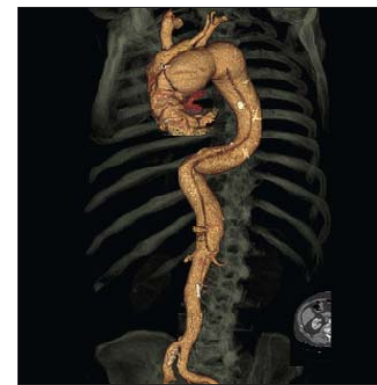At present CTA represents the current standard of reference in diagnosis and follow-up of patients with thoracic or abdominal aneurysms or with acquired aortic disease and has become critical for the pre-operative planning and post-operative follow-up of patient who have undergone endovascular aneurysm repair (EVAR). CTA provides all the informations (morphology, size, neck, extension, tortuosity, relationship with branch vessels, findings suggesting aneurysm rupture or inflammatory aneurysm) needed for selection of patients who are suitable for endograft and for the choice of the appropriate devices. In the follow-up of these patients it is effective and specific in the detection of procedure correlated complications, with sensitivity and specificity for endoleak detection better than those with conventional angiography ( 92% e 90% versus 63% e 77%).

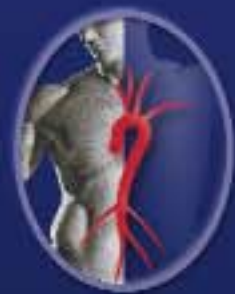Multiplanar and 3D reconstruction images provide additional advantages. They are the most relevant tool for patient selection and precise procedural planning and also for identifying post-interventional complications. Curved MPR is used primarily for automated calculation of the centerline of the vascular lumen and to estimate the orthogonal vessel diameter and the longitudinal extent. Due to the curvature of thoracic aorta and in case of marked aortic tortuosity, the size of aneurysm is most accurately measured when a perpendicular plane to the aortic flow lumen is generated. Reproducible and accurate measurement of diameters and courses of vessels improves the diagnostic accuracy. The sensitivity and specificity value for measurement of aortic aneurysms has been reported nearly 100%. Multiplanar reformation and 3D images also provide information in assessing the anatomical relationship of the aneurysm with branch vessels (especially when aortic disease involves the aortic arch) and with surrounding structures.

Furthermore CTA is the imaging modality of choice in suspicion of aortic emergency (dissection or in cases of acute aortic syndrome). It provides precise information about arterial lumen (true and false lumen), walls (development of thrombus or paraortic hematoma), entry and reentry sites, extralumen structure of entire aorta and main aortic branches. Sensitivity and specificity in detection of aortic dissection have been reported greater than 90%. Published sensitivity and specificity value in evaluation and classification of dissection (Stanford A e B) range between 96-100% for echocardiography, MRA and CTA.

In many studies MRI has been shown to be effective in identifying and characterizing thoracic and abdominal aortic aneurysms. Gadolinium-enhanced T1-weighted MRI and MRA may play an important role in preoperative evaluation and contrast-enhanced 3D MRA can provide precise topographic information about the extent of the aneurysm and its relationship to the aortic branches.

In the assessment of aortic aneurysms MR Angiography provides results similar to CTA, but is inadequate for the surveillance after EVAR. The advantages of MRA are the lack of ionizing radiation and iodinated contrast medium; for these reasons is usually reserved for young patients and those with contraindication to iodinated contrast material. The disadvantages of MRA are less readily availability, requirement of longer scan times, patient claustrophobia and contraindication in patients with cardiac pace-maker. Furthermore it is unsuitable for the evaluation of the patency of the stented vessel and in case of non MR compatible endograft, susceptibility artifacts can compromise image quality and mimic stent stenosis or occlusion.





'08

SCIENTIFIC ABSTRACTS

OPEN SURGERY II

*Chairmen:* Giovanni Deriu, H. Joachim Schäfers, Alberto Zangrillo

AORTIC ROOT DYNAMICS: IMPLICATIONS FOR AORTIC VALVE REPLACEMENT	Xu Yu Jin Discussant: Raphael de Geest
ELEPHANT TRUNK AND “REVERSED” ELEPHANT TRUNK PROCEDURES FOR EXTENSIVE THORACIC ANEURYSMS	Joseph S. Coselli Discussant: Francesco Siclari
GUIDELINES FOR THE MANAGEMENT OF THE CARDIOPATIC PATIENT IN VASCULAR SURGERY	Fabio Guarracino Discussant: Alberto Zangrillo
VOLATILE ANESTHETICS REDUCE PERIOPERATIVE MORTALITY IN CARDIAC SURGERY	Giovanni Landoni Discussant: Mara Scandroglio
TAAA: STATE-OF-THE-ART IN PARAPLEGIA PREVENTION AND THERAPEUTIC OPTIONS	Michael Jacobs Discussant: Francesco Setacci
SUPRARENAL AORTIC CLAMPING FOR JUXTARENAL AORTIC OCCLUSION, PARARENAL ANEURYSM AND RUPTURED ANEURYSMS	Attilio Odero Discussant: Pietro Rispoli
ABDOMINAL AORTIC SURGERY IN CHILDREN	Xavier Barral Discussant: Mauro Gargiulo



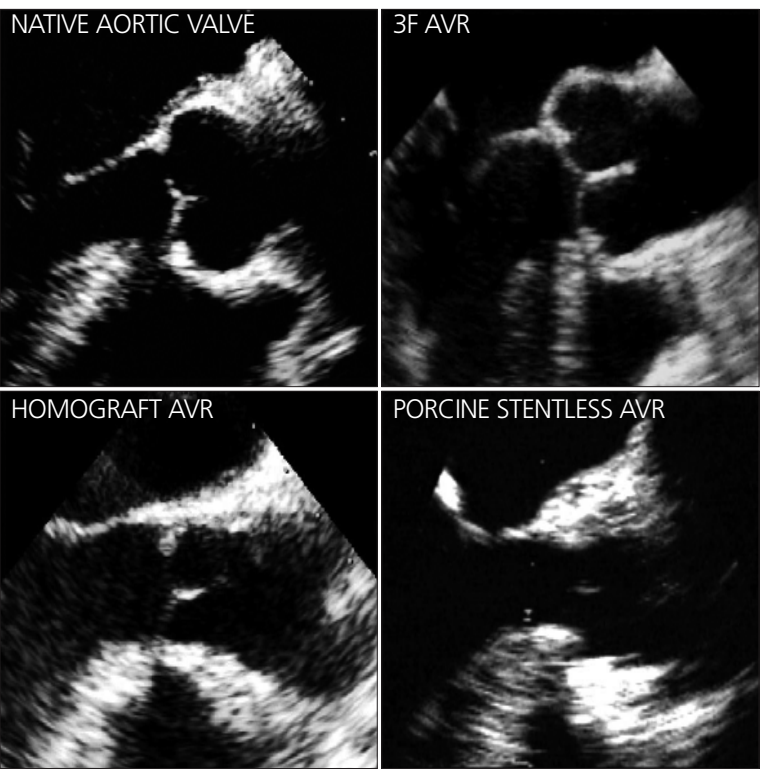
# AORTIC ROOT DYNAMICS: IMPLICATIONS FOR AORTIC VALVE REPLACEMENT

Xu Yu Jin  
John Radcliffe Hospital, Oxford - UK

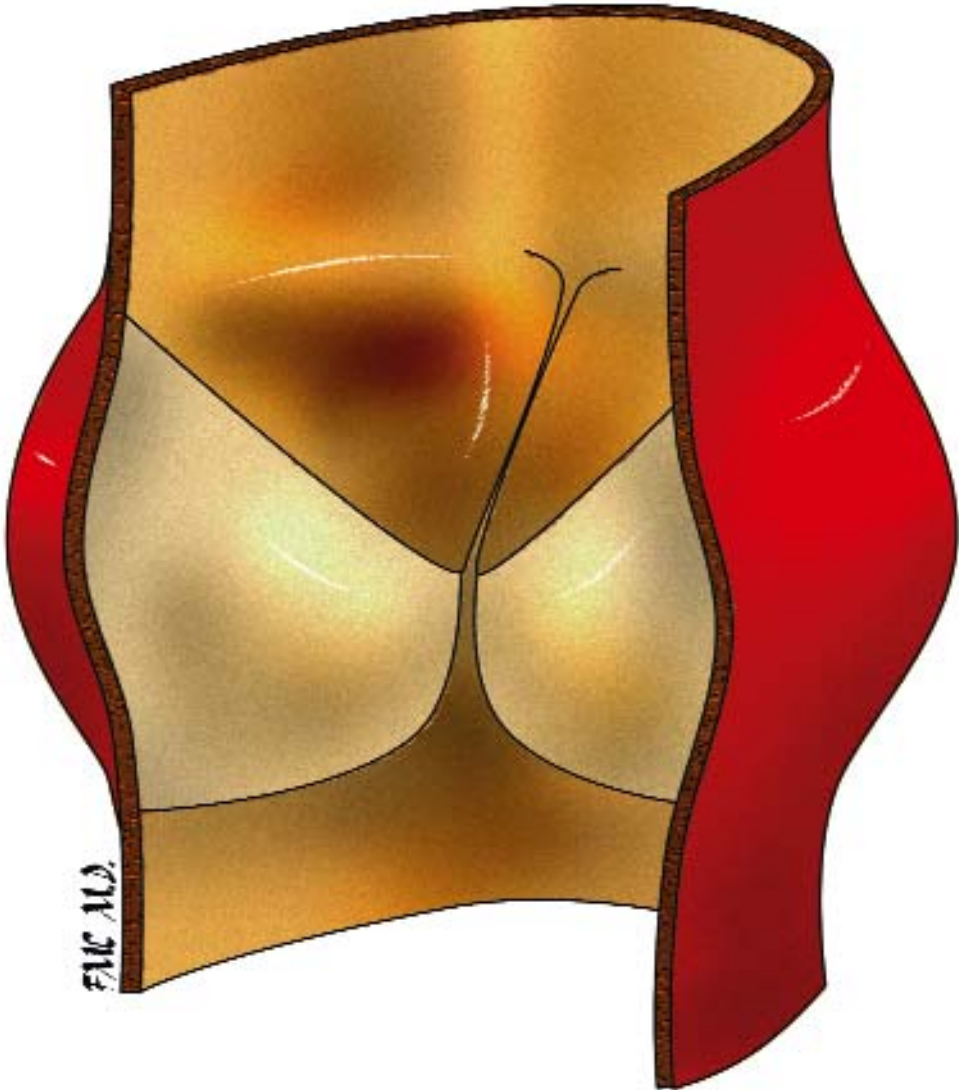
The preservation of the native root geometry and dynamics in contemporary aortic valve surgery has been clearly implicated for maintaining normal aortic cusp stress distribution, hemodynamic efficiency and long term valve durability. The pursuit of this concept in aortic root remodeling surgery for Marfan patients has lead to the development of a sinus shaped aortic graft. In the setting of stentless AVR, the overwhelming clinical attention to the size of sino-tubular junction and its relation to valve competence has diverted the need of focus on the whole root geometry and dynamics. By comparing native aortic root with those implanted with different types of aortic valve substitutes in sub-coronary position, we have demonstrated how valve design and implantation technique can modify aortic root geometry and dynamics. These findings have formed anatomic basis for clinical merits in considering valve type and its surgical techniques.

One hundred forty-five cases (age  $70 \pm 7$  yr, 63% males) were prospectively studied by trans-thoracic echo. Of those, 100 patients had AVR in the sub-coronary position with either a 3F tubular equine pericardial aortic bioprosthesis (using single suture-line techniques with fixation of 3 tabs at the sino-tubular junction (3F-AVR; n=44), a conventional porcine stentless valve (using double suture-line techniques) with either all three sinus scalloped (3SS-AVR; n=18) or with only the left and right coronary sinuses scalloped (2SS-AVR; n=38). In addition, 45 patients with a normal native aortic valve and root were served as control group (Native-AV; n=40). From 2D echo images of the left parasternal long axis view, aortic root geometry and dynamics was assessed by measuring the diameter and systolic changes of LV outflow tract, aortic sinus, S-T junction and ascending aorta at 12 months after AVR. Systolic sinus wall thickening rate was also quantified.

With comparable clinical demographic profiles, there was a significant difference in aortic sinus and ST junction diameters amongst the groups. 3F-AVR which has no direct sutures within the aortic sinus has fully preserved the native aortic root geometry and dynamics. 2SS-AVR and 3SS-AVR using conventional double suture-line techniques resulted in a significantly reduced aortic sinus diameter which was equalized to ST junction, thus formed tubular aortic root geometry and lost root dynamics. The functional implications of tubular root geometry for increasing aortic cusp stress and resultant clinically premature cusp tearing in stentless AVR are discussed in details. Our data suggest that avoiding a 2<sup>nd</sup> suture line within the aortic sinus and maintaining the continuity between the ST junction and aortic annulus, like the implantation of 3F valve, appears to be the key principles for achieving and maintaining native normal aortic root geometry and dynamics in stentless aortic valve replacement.



COMPARISON OF AORTIC ROOT GEOMETRY  
(IN END-DIASTOLE)



# ELEPHANT TRUNK AND “REVERSED” ELEPHANT TRUNK PROCEDURES FOR EXTENSIVE THORACIC ANEURYSMS

**Joseph S. Coselli**

*The Texas Heart Institute at St. Luke's Episcopal Hospital and Baylor College of Medicine, Houston - TX - USA*

J.S. Coselli, S.Y. Green, S.A. LeMaire

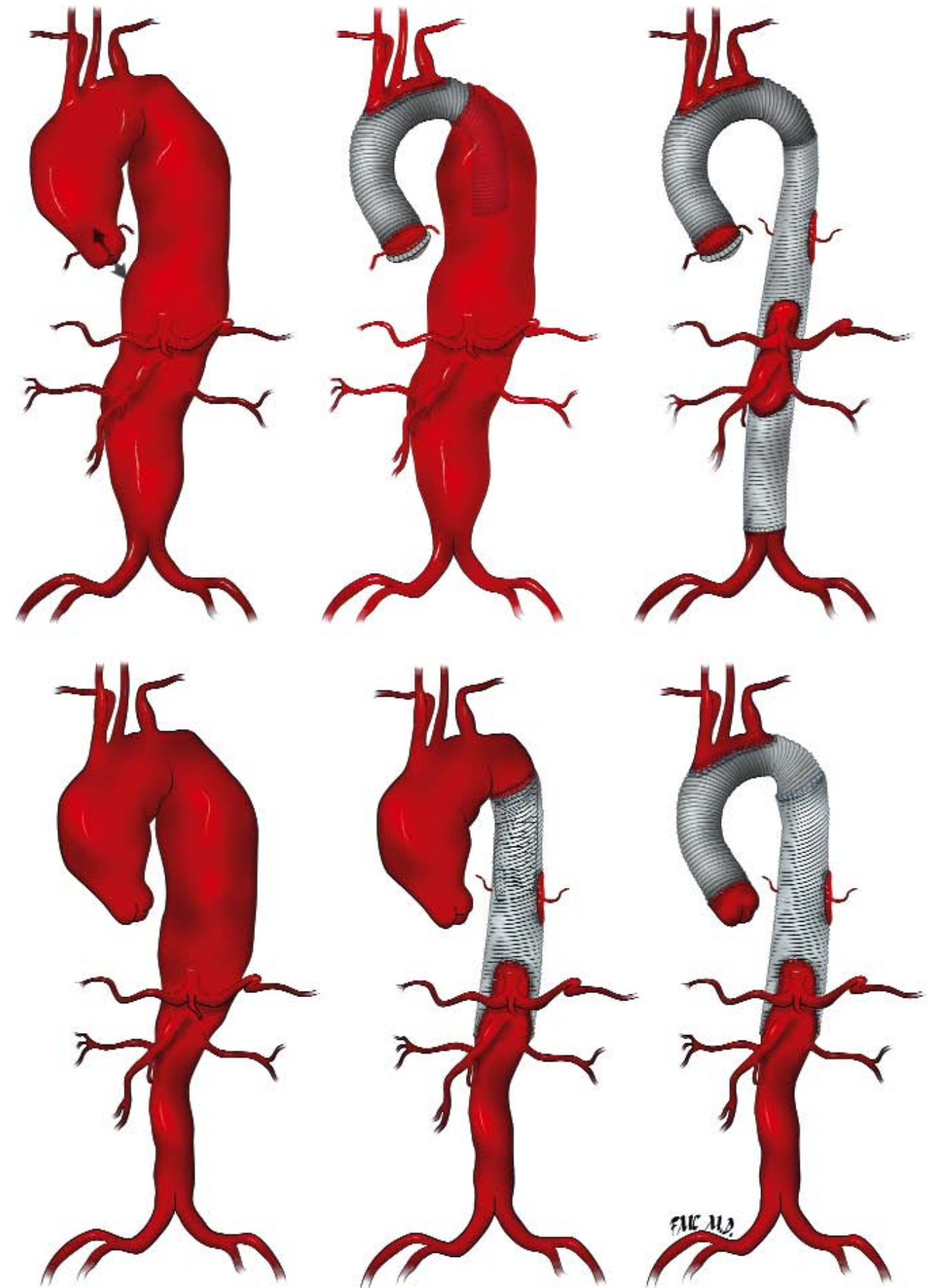
Surgical repair of extensive aortic aneurysms, ie, those that require replacement of the aorta from its ascending segment to the descending or thoracoabdominal portion, requires a specialized approach to enable sufficient exposure of all diseased segments. Although this repair can be made in a single operation, as in techniques reported by Kouchoukos and Svensson, it is more often done in stages. In his report published in 1983, Borst described a 3-stage aortic repair in which short sections (10 cm) of aortic graft were left freely floating in the segments of aorta beyond the repair. These suspended “elephant trunks” were anchored upstream by a circumferential anastomosis. This simplified the subsequent stages by providing the elephant trunk as the clamp-site and allowing a quick graft-to-graft anastomosis. This method avoids the need to expose and clamp the previously replaced aortic segment and reduces cross-clamp time. Other benefits include a reduced risk of injury to the pulmonary artery, esophagus, and local nerves, because the clamp-site and anastomosis have been moved further downstream.

Although Borst described a 3-stage aortic repair in his landmark publication, 2-stage repairs are more common today.

The traditional sequence for staged repair of extensive thoracic aortic aneurysms involves replacing the ascending and arch segments during the first operation and the descending or thoracoabdominal segments during the second procedure. However, in some patients – such as those with symptomatic or disproportionately large descending thoracic aneurysms – it is necessary to replace the distal segments first. The reversed elephant trunk technique can be used during the first-stage descending or thoracoabdominal procedure, and leaves a segment of graft suspended from the proximal suture line. This segment can then be retrieved during the second-stage arch operation, eliminating the need for a distal arch anastomosis and thereby reducing circulatory arrest time.

We have reported results for 148 first-stage elephant trunk aortic arch repairs; 130 patients (88%) survived, and of these, 76 (58%) underwent the second-stage repair of the distal aorta with 73 (96%) survivors. Two patients (3%) developed paraplegia after the second operation. We have also reported 38 first-stage reversed elephant trunk repairs of the descending or thoracoabdominal aorta; 32 patients (84%) survived the first operation, and of those, 12 (38%) had completed the second-stage arch repair with 11 (92%) survivors.

Finally, 1- or 2-stage hybrid elephant trunk repairs, which combine open surgical and endovascular techniques, have recently emerged as valuable alternative approaches. The primary benefit of these hybrid repairs is that they are less invasive, can be performed in patients unable to withstand a second open procedure, and reduce or eliminate the interval between operations.





**Fabio Guarracino**

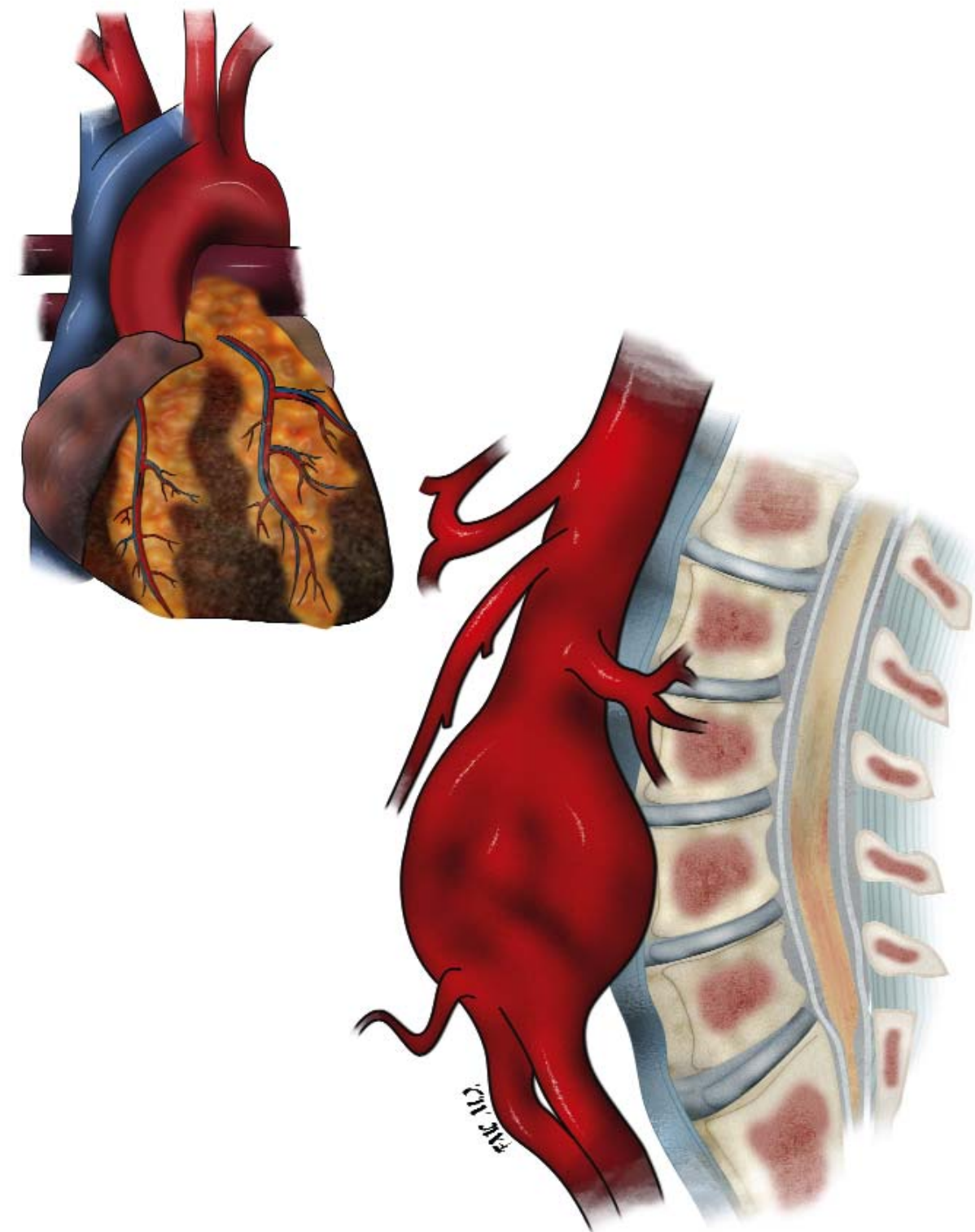
*Azienda Ospedaliero-Universitaria Pisana, Pisa - Italy*

Risk stratification before vascular surgery is an everyday challenge for the clinical team (surgeon, anaesthetist, cardiologist). The prediction of events in this set of patients bears important clinical and practical implications. Cardiovascular complications are the leading cause of death after non-cardiac surgery accounting for approximately half of all mortality. Moreover, patients with peripheral vascular artery disease have a higher chance of dying for cardiac and cardiovascular causes compared to patients with no peripheral vessel disease. In the setting of vascular surgery the incidence of cardiac morbidity and mortality (myocardial infarction and death) in the post-operative period is higher when compared to other type of non-cardiac surgery.

The need for a strategy of stratification for patient evaluation before vascular non cardiac surgery led to the definition of periodically updated guidelines by the American Heart Association/American College of Cardiology. The aim of such Recommendations is: to identify those patients in whom the optimization of medical therapy or a coronary revascularization before surgery might reduce the risk of the surgical procedure; to identify those patients in whom an invasive and intensive monitoring might reduce the risk of perioperative events; to assess the long-term risk of a future cardiac event.

Although risk stratification in patients undergoing vascular surgery has a relatively low prognostic power, it is a rational approach to avoid any form of risk stratification in asymptomatic patients with no history of coronary artery disease. On the other side patients with peripheral artery disease do not have this clear clinical presentation and might experience cardiac complications due to the following reasons: many of the risk factors contributing to peripheral vascular disease (diabetes mellitus, smoking habit, dyslipidemia) are also risk factors for coronary artery disease; the usual symptomatic presentation for coronary artery disease in these patients may be obscured by exercise limitations due to advanced age or intermittent claudication; major arterial operations often have long duration and may be associated with relevant fluctuations in intra-extra vascular fluid volumes, blood pressure, heart rate. These considerations do not imply that all patients undergoing major vascular surgery should undergo risk stratification.

The decision to recommend further stratification procedures in each single patient must take into account the probability of efficacy versus the potential risks. It is conceivable that during the stratification process the risks of tests or treatment might outweigh the potential benefits of the evaluation. The incidence of coronary artery disease in patients with peripheral vascular disease is around 60% and asymptomatic, preoperative screening might represent the first one for the assessment of a previously unsuspected coronary artery disease. Therefore, many patients will have their coronary artery disease diagnosed at the moment of the intervention whereas those with known coronary artery disease will benefit of an optimization of the medical regimen.



# VOLATILE ANESTHETICS REDUCE PERIOPERATIVE MORTALITY IN CARDIAC SURGERY

Giovanni Landoni  
San Raffaele Scientific Institute, Milano - Italy  
G. Landoni, E. Bignami

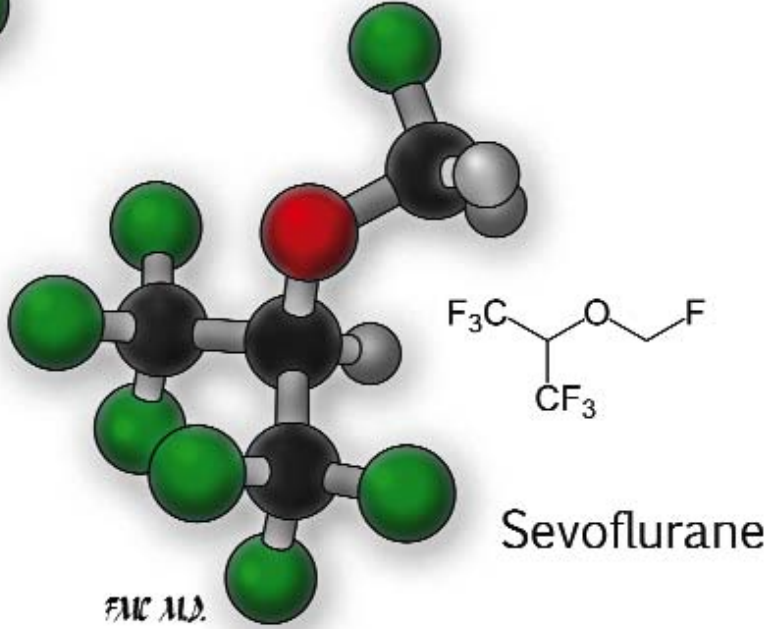
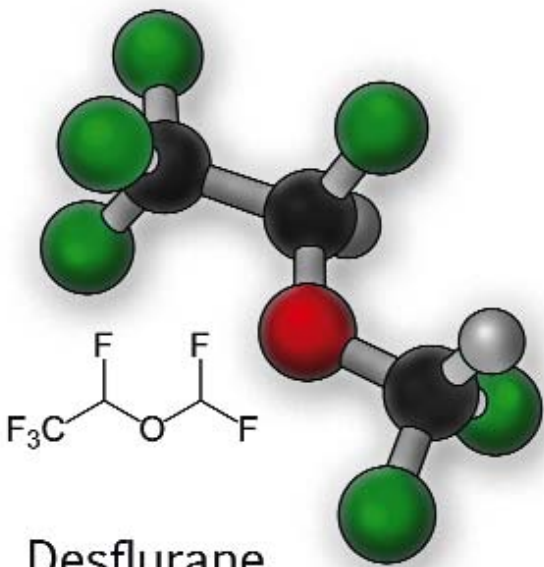
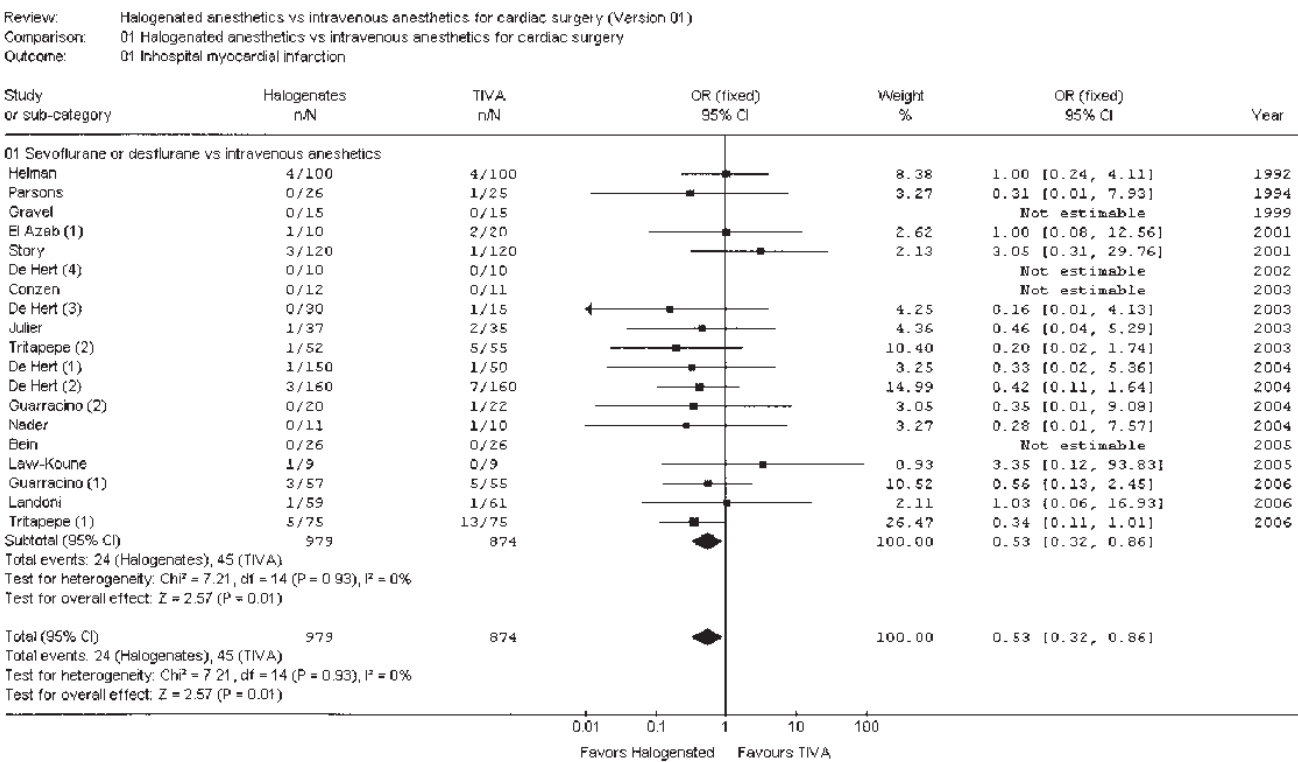
Desflurane and sevoflurane are the only anaesthetic drugs that have been proven to reduce perioperative morbidity and mortality up to date. [1] A recent meta-analysis recently shown a reduction in perioperative myocardial infarction (MI) and death in those patients randomised to receive desflurane or sevoflurane versus a total intravenous anaesthesia (TIVA) for cardiac surgery. [1] The 22 included trials randomised 1922 patients (904 to TIVA and 1018 receiving desflurane or sevoflurane in their anaesthesia plan). Most studies were performed on patients undergoing on-pump coronary artery bypass grafting (CABG), six on patients undergoing off-pump CABG, and only one investigated patients undergoing mitral surgery. Overall analysis showed that, in comparison to TIVA, volatile anaesthetics were associated with significant reductions in the rates of all major endpoints. Specifically, volatile anaesthetics reduced the risk of MI (24/979 [2.4%] in the volatile anaesthetics group vs 45/874 [5.1%] in the control arm, OR=0.51 [0.32-0.84], p=0.008), and all-cause mortality (4/977 [0.4%] vs 14/872 [1.6%], OR=0.31 [0.12-0.80], p=0.02).

The mechanisms that lie beneath the protection from perioperative cardiac ischaemic damage given by desflurane and sevoflurane still lack a complete explanation, although pharmacological properties which are not related to anaesthetic or haemodynamic effects of these drugs appear to be involved.

Recent American College of Cardiology / American Heart Association Guidelines recommended volatile anaesthetic agents during non-cardiac surgery for the maintenance of general anaesthesia in patients at risk for MI but whether these cardioprotective properties exist in non-cardiac surgery settings is controversial. [2]

References:

1. Landoni G, Biondi-Zoccai GG, Zangrillo A, Bignami E, D'Avolio S, Marchetti C, et al. Desflurane and sevoflurane in cardiac surgery: a meta-analysis of randomized clinical trials. J Cardiothorac Vasc Anesth 2007;21(4):502-11.
2. Landoni G, Fochi O, Zangrillo A. Cardioprotection by volatile anesthetics in noncardiac surgery? No, not yet at least. J Am Coll Cardiol 2008;51(13):1321.





**Michael Jacobs**  
*European Vascular Center Aachen-Maastricht - Germany - The Netherlands*

Spinal cord ischemia with subsequent paraplegia remains one of the most dreaded complications following open and endovascular thoraco abdominal aortic aneurysm (TAAA) repair. During the last decades several adjunctive measures have been developed in order to limit neurological deficits.

At present several issues regarding spinal cord ischemia can be addressed, including 1/ risk assessment; 2/ preoperative visualization of spinal cord vasculature; 3/ surgical protocol; 4/ intra-operative neuromonitoring and 5/ therapeutic measures.

Ad 1/ Both in open and endovascular TAAA repair several preoperative conditions can be identified which increase the risk on spinal cord perfusion problems like previous aortic surgery, occluded internal iliac arteries and diseased or overstented left subclavian artery.

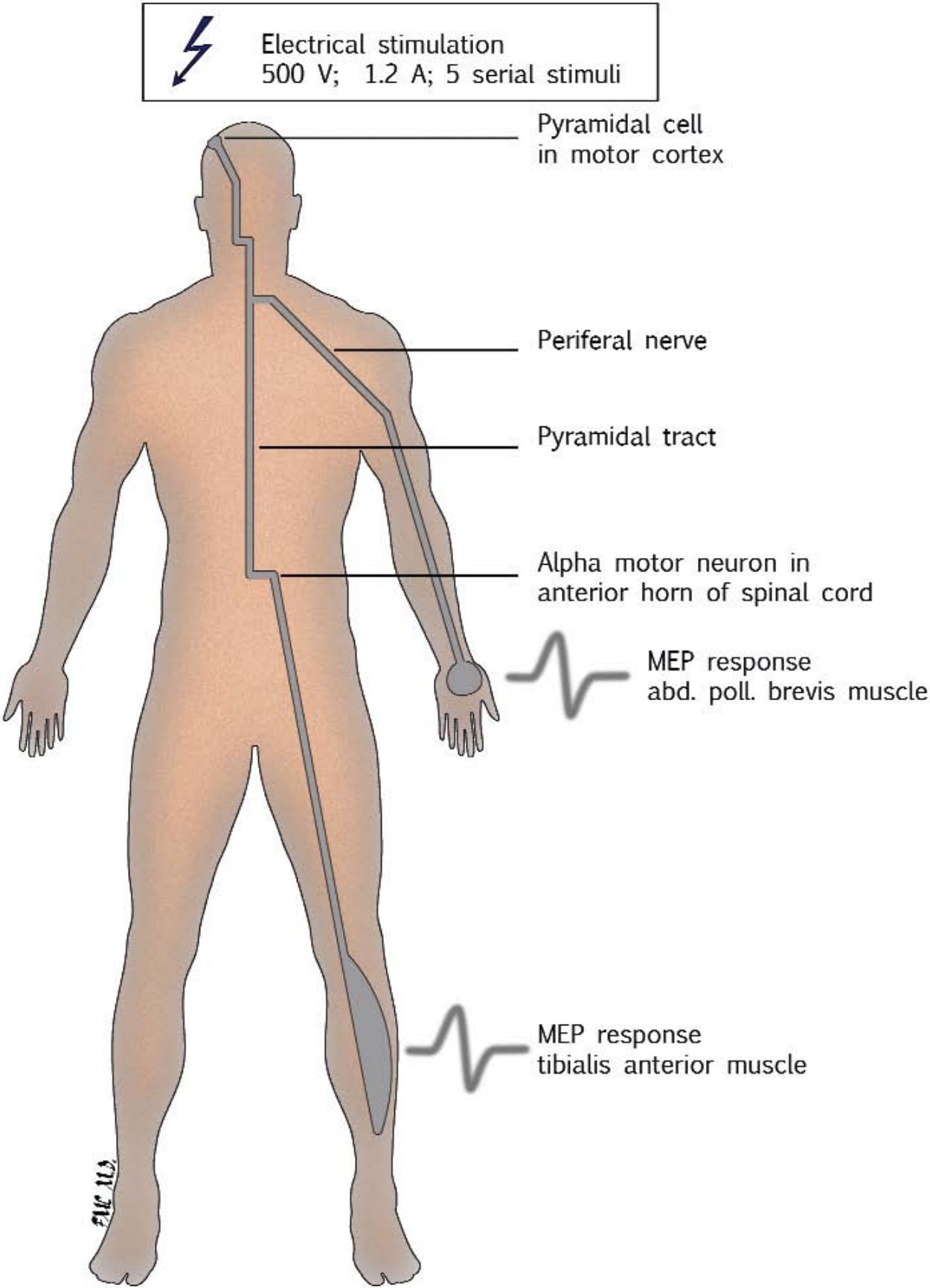
Ad 2/ Newly developed CT and MR techniques allow visualization of the anterior spinal artery as well as its main feeding vessels. This information might play a significant role in endovascular planning or surgical revascularization.

Ad 3/ In patients undergoing endovascular repair at high risk for spinal cord ischemia and in all patients planned for open repair, cerebrospinal fluid drainage should be part of the surgical protocol. Furthermore, in open repair, distal aortic perfusion permits continuous perfusion of the lumbar and iliac arteries, which form a significant part of the collateral blood flow to the spinal cord.

Ad 4/ During the procedure, on-line monitoring of spinal cord integrity allows detection of ischemic conditions, prompting corrective measures to re-establish adequate spinal blood flow. Monitoring motor evoked potentials is a highly sensitive technique to assess spinal cord function with, in our experience, absence of false positive or false negative readings.

Ad 5/ Perioperative therapeutic measures to improve spinal cord perfusion can be based on preoperative anatomic and/or perioperative functional information. These measures include increasing mean arterial and distal aortic pressure, reimplantation of segmental arteries or aortic endarterectomy with selective intercostal artery bypass. Also, postoperative hemodynamic management in the intensive care unit depends on perioperative information regarding required arterial pressures to maintain spinal cord integrity.


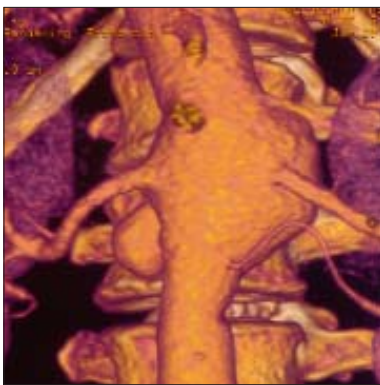
Implementing the above described strategies can reduce the incidence of paraplegia in patients undergoing endovascular and open TAAA repair. In our experience following this protocol in more than 500 patients we have encountered overall paraplegia rate of less than 2.5%.



# SUPRARENAL AORTIC CLAMPING FOR JUXTARENAL AORTIC OCCLUSION, PARARENAL ANEURYSM AND RUPTURED ANEURYSMS

**Attilio Otero**  
*Università degli Studi di Pavia - Italy*  
A. Otero, V. Arici

Suprarenal aortic clamping (SAC) is a procedure used in selected cases during the repair of lesions involving infrarenal aorta. These are juxtarenal aortic aneurysm (JxAA: neck length below 1 cm), aortic occlusion close to renal arteries emergency (JAA) and ruptured infrarenal aortic aneurysm (RIAA), when a large haematoma doesn't allow infrarenal aortic control. In the case of pararenal aneurysms (PA: aneurysms involving the emergency of at least one renal artery), suprarenal aortic clamping is steadily unavoidable. A particular case in which SAC can be necessary is secondary aortoenteric fistula (sAEF), because of the aortic neck lack and adhesions. Inter-renal (between the emergency of the renal arteries) aortic clamping is a dangerous procedure because of the high incidence of atheromatous renal embolism. As well known SAC causes renal or total visceral ischemia depending on the SAC level: when possible, SAC under superior mesenteric artery is preferable to supraceliac clamping to limit ischemia damage. Ischemia can cause organ damage with consequent acute tubular necrosis and renal failure (ARF) (14-16%), acute dialysis (7-9%), late renal functional decline or multiorgan failure, the latter often fatal. Perioperative mortality rate for selective SAC is around 3%. Short period renal ischemia is well tolerated in absence of preoperative renal arteries stenosis and renal failure. On the contrary preoperative renal artery stenosis and renal failure are proven risk factors for postoperative ARF or dialysis. Protective aids for splanchnic and renal parenchymas are cooling with 4°C saline local infusion, systemic dopamine or corlopam, mannitol, controlled hypervolemia and anticoagulation. Critical issues during SAC are left renal vein (LRV) division and following reconstruction, renal and visceral arteries thromboembolism prevention and correct flushing before declamping. Better SAC time is obviously the shorter than possible, but a 20-30 minutes clamping time, as shown in literature, are well tolerated. Moreover SAC for ruptured aneurysm is more dangerous because of the systemic shock state. In our experience, among 2845 infrarenal aortic intervention over an 18 years period, we used SAC in 213 cases (7.48%). 43 cases (20.18%) were PA or suprarenal aneurysms, 32 (15.02%) JxAA, 45 (21.12%) JAA, 68 (31.92%) RIAA and 25 (11.73%) sAEF. LRV division was necessary in 15 cases (7.04%) and in 10 it was repaired. Perioperative mortality rate was electively 2.5%, in emergency 21.5%. Postoperative ATN and ARF was 16.9%, acute dialysis 3.7%, permanent in 2.34%. We can conclude that SAC shows acceptable rates of mortality and ARF, especially during elective procedure.





Xavier Barral

Hôpital Nord, Centre Hospitalier Universitaire de Saint Etienne - France

X. Barral, M. Vola, G. Nourissat, J.N. Albertini, J.P. Favre

Acquired or congenital lesions of the abdominal aorta in childhood are rare. In our experience, they represent 0.1% of overall abdominal aortic procedures.

Lesions may be aneurismal, traumatic, occlusive (in case of middle aortic syndrome) and inflammatory (in case of Takayasu disease). Those lesions are characterized by the frequent involvement of visceral and renal arteries.

A number of technical aspects are important in order to obtain good long-term outcomes.

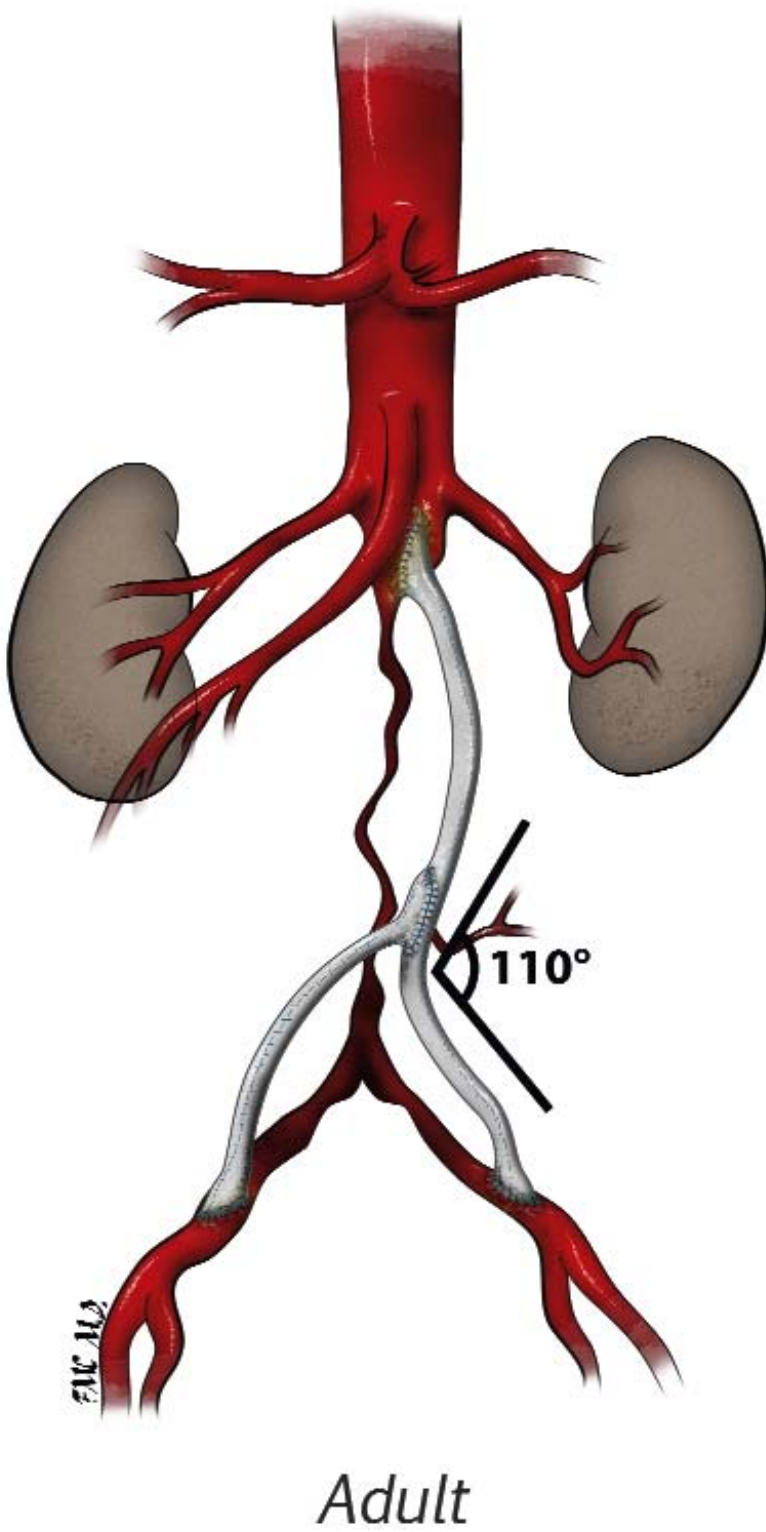
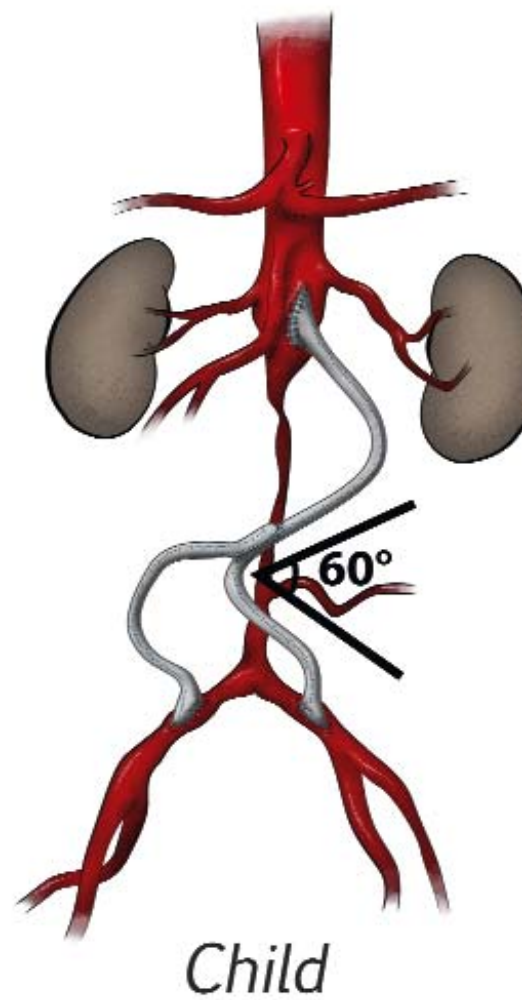
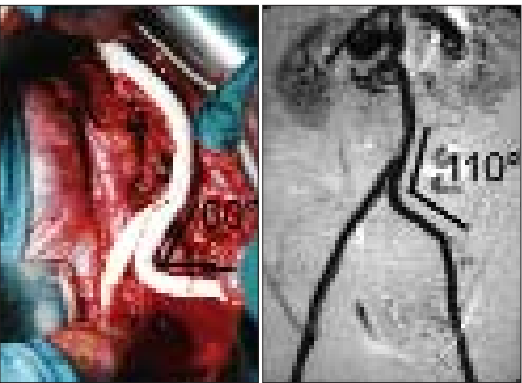
A - In case of occlusive disease (middle aortic syndrome and Takayasu disease) aortic replacement is necessary only when children are symptomatic or if pressure gradient between descending thoracic aorta and infrarenal aorta is equal or greater than 20 mmHg. In those cases, it is preferable to wait and operate at the age of 10-12 year, in order to use 8 mm graft or greater, which allows to maintain adequate flow when adults.

B - Aortic and/or iliac grafting should be performed with an excess of graft length, so that traction and false aneurysm during growth may be prevented.

C - Associated visceral or renal artery lesions should not be treated using saphenous grafts because they tend to dilate over time. Prosthetic grafts should be avoided because they are poorly adapted to small arteries that rarely exceed 3 mm in diameter. Moreover, the thinness of the arterial wall in children favors the occurrence of myointimal hyperplasia. Instead, arterial substitutes such as superficial femoral or hypogastric arteries are the gold standard and provide the best long-term outcomes. Autotransplantation with direct reimplantation of the renal artery in the distal aorta or common iliac artery may be a good solution as well. Also, the Riolo arch may be used as inflow site during renal artery revascularization. This technique avoids the use of venous or prosthetic bypass and is easier than autotransplantation. Reimplantation of renal or visceral arteries in Dacron grafts should be avoided because of the high rates of restenosis.

D - In case of abdominal aortic hypoplasia or middle aortic syndrome, the arterial supply to the bowel is provided by the inferior mesenteric artery and the arch of Riolo. These children are often asymptomatic. Surgical treatment of superior mesenteric artery stenosis is not necessary. On the contrary, superior mesenteric artery aneurysms are to be operated on. A normal Riolo arch provides sufficient blood flow to ensure normal growth without malnutrition.

The observance of the present recommendations should provide good immediate and long-term outcomes as it has been the case in our experience. We operated on 8 children with a mean age of 10 year. All have been followed up at least fifteen years. Three needed a secondary operation. They all remain alive to date with normal familiar and professional lifestyles.





'08

SCIENTIFIC ABSTRACTS

COMPLICATIONS

*Chairmen:* Alain Branchereau, Tommaso Fiore, Luigi Martinelli, Giuseppe Raimondo Pistolese

PROSTHETIC ENDOCARDITIS FOLLOWING AORTIC VALVE REPLACEMENT	Luigi Martinelli Discussant: Antonio Grimaldi
STROKE AFTER OPEN ARCH SURGERY. PREVENTION STRATEGIES	Stefano Benussi Discussant: Xu Yu Jin
PERIOPERATIVE PREVENTION AND POSTOPERATIVE MANAGEMENT OF RESPIRATORY COMPLICATIONS AFTER AORTIC SURGERY	V. Marco Ranieri Discussant: Federico Pappalardo
RENAL PROTECTION IN THE CRITICALLY ILL PATIENT WITH OR AT RISK FOR ACUTE RENAL FAILURE. THE ROLE OF FENOLDOPAM	Tiziana Bove Discussant: Tommaso Fiore
ENDOVASCULAR TREATMENT OF COMPLICATIONS FOLLOWING THORACIC AND THORACO-ABDOMINAL AORTIC SURGERY	Franco Grego Discussant: Yamume Tshomba
SOLUTIONS FOR FAILURE OF EVAR AND TEVAR	Piergiorgio Cao Discussant: Gioacchino Coppi
ADVANCEMENTS IN THE TREATMENT OF THORACIC AND ABDOMINAL GRAFT AND STENT-GRAFT INFECTION	Olivier A. Goëau-Brissonnière Discussant: Vincenzo Rampoldi
AORTOENTERIC AND AORTOBRONCHIAL FISTULAE	Enrico M. Marone Discussant: Claudio Novali

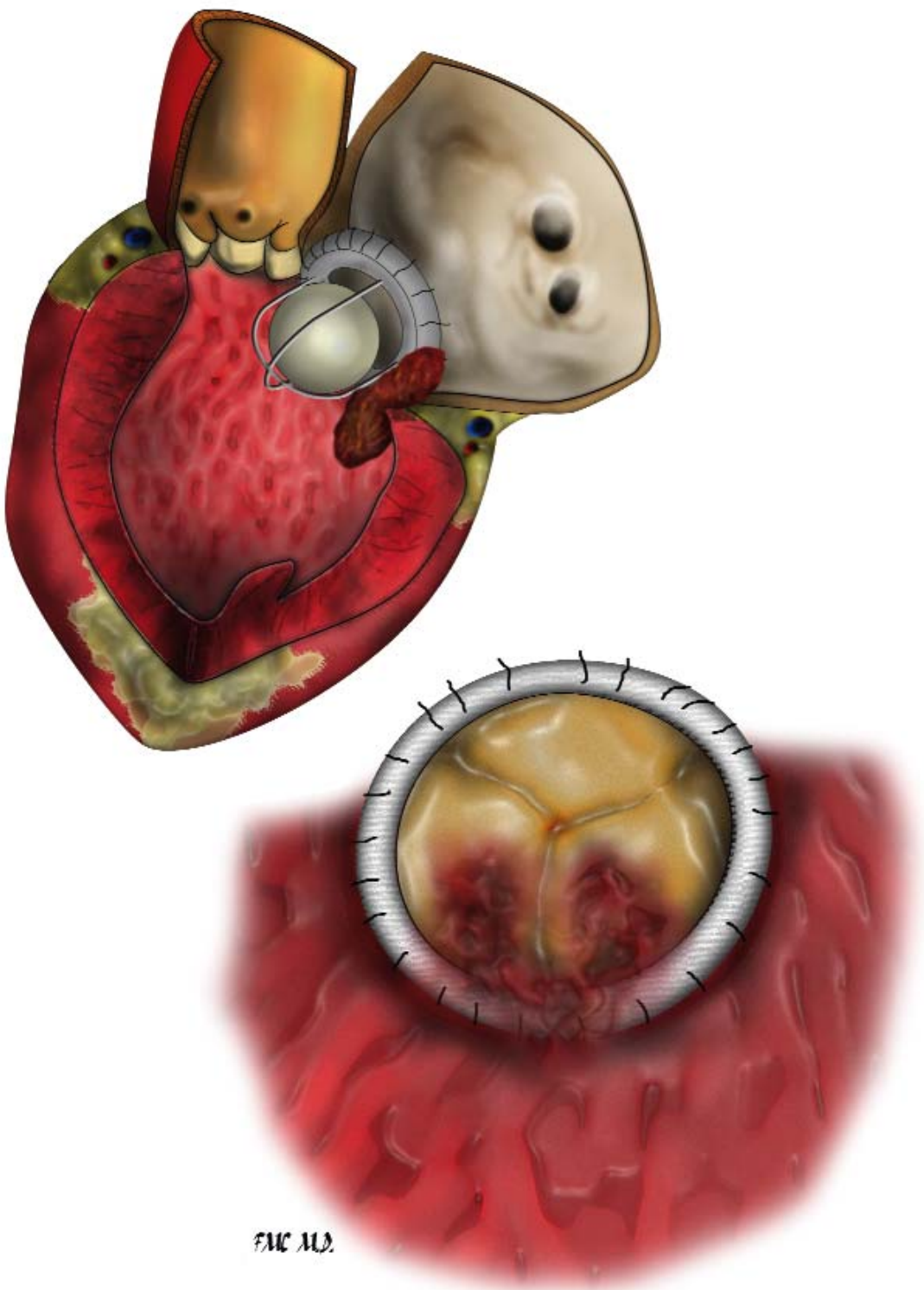
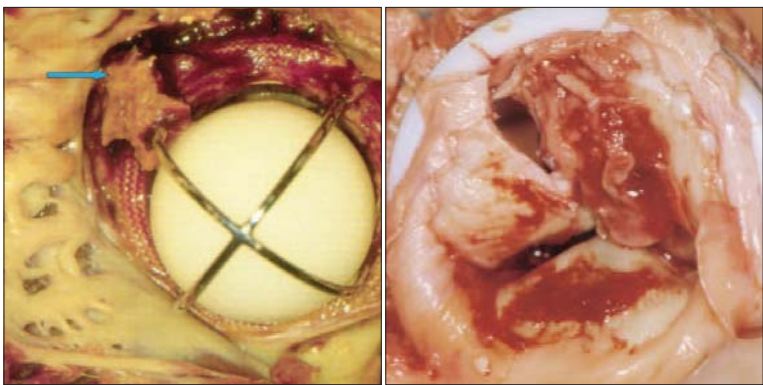


# PROSTHETIC ENDOCARDITIS FOLLOWING AORTIC VALVE REPLACEMENT

Luigi Martinelli  
*Ospedale Niguarda Ca' Granda, Milano - Italy*

Prosthetic valve endocarditis (PVE) is a major complication of aortic valve replacement (AVR). Patients (pts) with prosthetic aortic valves have an incidence of PVE of 0.2-1.4% per patient-year. Approximately 1.4% of pts undergoing AVR develop PVE during the first postoperative year. Mechanical and bioprosthetic valves are equally affected during the first postoperative year; after 18 months there is an increased risk for pts with bioprostheses. PVE has been classified as early when it occurs within the first two months after surgery and as late when it occurs after two months. However, it is possible that many cases of PVE that occur during the first year after surgery are acquired at the time of implantation of the prosthesis. Incremental risk factors include multivalve operations, aortic root replacement with a synthetic graft and operation for native aortic valve endocarditis. For pts without native valve infection as an indication for surgery, early PVE appears to be a nosocomial infection based on intraoperative contamination or bacteremia in the postoperative phase. The most common portals of entry are intravascular catheters and skin infections. *Staphylococcus aureus*, coagulase-negative staphylococci, *Enterococcus faecalis*, gram-negative organisms and fungi are the more common microorganisms responsible for early PVE. Most series of pts with late PVE usually have a higher incidence of *Staphylococcus aureus* and *Enterococcus* infections. Nosocomial infection also causes late PVE, particularly for pts with the need for dialysis or with medical conditions involving immunosuppression. In a small proportion of cases of PVE, no microorganism can be cultured from either the blood, surgical specimens or the explanted valve. Infection of a mechanical aortic valve is usually located in its sewing ring, creating a periprosthetic leak. Infection of a porcine or pericardial valve may involve the cusps, the sewing ring, or both. Often the infection extends into the fibrous trigone of the heart and may displace the anterior leaflet of the mitral valve inferiorly, creating abscess cavity. In the areas of the septum, extensive infection may erode into the right ventricle or into the right atrium in the region of the membranous septum, creating intracardiac fistulae. Valve leaflets involvement with vegetations may serve as a source for emboli and cause formation of distant abscesses. Infection in aortic valve homografts and pulmonary autografts resembles that of native aortic valve: it begins in the aortic cusps and destroys them, causing aortic insufficiency, but it may also extend into surrounding structures. Endocarditis after aortic root replacement with mechanical valves frequently causes dehiscence of the valve from the aortic annulus with consequent false aneurysm.

Most pts with PVE following AVR treated with only antibiotics generally experience very poor outcomes. Reports from experienced centers confirmed the superiority of combined medical-surgical therapy in order to improve the survival. Early surgery is recommended particularly for pts with early PVE and with annular involvement. For pts with isolated aortic PVE, complete removal of the valve and implantation of a biologic or mechanical valve usually resolves the problem. There is no evidence that bioprostheses are better than mechanical valves in pts with infective endocarditis. Some investigators believe that aortic valve homograft is the ideal choice for these pts, but the fact is that it can become infected like other valves. If the aortic annulus is involved in the infective process, resection of the necrotic or inflamed area is needed before a prosthetic valve can be implanted. The defect created by the resection should be patched before a prosthetic valve is implanted. Surgery for aortic root abscess and/or cardiac fistulas is challenging. The most important aspect in the surgical treatment of these patients is radical resection of all infected tissues rather than the type of valve implanted. These pts frequently require replacement of the entire aortic root (often with an aortic valve homograft or a valved conduit) and reconstruction of the surrounding structures that are also involved by the abscess (interventricular septum, dome of the left atrium, inter-valvular fibrous body, right atrium, pulmonary artery may be necessary, left and/or right coronary arteries).



# STROKE AFTER OPEN ARCH SURGERY. PREVENTION STRATEGIES

**Stefano Benussi**  
*San Raffaele Scientific Institute, Milano - Italy*  
L. Torracca, S. Benussi

Cerebral damage resulting in permanent or transient neurological dysfunction is the major source of mortality and morbidity after aortic arch surgery.

Brain damage can be due to global hypoperfusion occurring during circulatory arrest or to embolisation of particulate materials during vessels manipulation.

Various brain protective strategies have been advocated to reduce neurological risk.

Today selective antegrade cerebral perfusion (SACP) is probably the most widely used technique to supplement hypothermic circulatory arrest (HCA).

Crittenden and co-workers were the first to demonstrate experimentally the advantage of SACP over any alternative method of cerebral protection, showing that hypothermic low-flow SACP preserve intracellular pH and energy stores in sheep.

Clinical application reported in large series have shown good results and important advantages when compared with other brain protective technique.

While there are clear evidence of the superiority of cerebral antegrade perfusion, optimal delivery way and perfusion characteristics are still debated.

Perfusion through the axillary artery have been advocated to reduce the epiaortic vessel manipulation but concern still remain regarding the unilateral perfusion, at least for those 15% of patients with incomplete circle of Willis.

Recent data demonstrate the absence of correlation between anatomical completeness of the circle of Willis and sufficient cross-perfusion during unilateral cerebral perfusion and rule out the usefulness of preoperative CT scan in patients selection for unilateral brain perfusion.

In this context of uncertainty and conflicting data, the use of a second cannula placed in the common carotid artery still remain a safe and not expensive solution. The risk of particulate material embolisation can be minimize using specific soft cannula introduced 1cm distal to the vessel origin where the atherosclerotic plaque localisation is less common.

The optimal flow rate and temperature of SACP are also debated.

Most of the authors report the use of a flow of 10ml/kg/min as proposed by Kazui. Recent studies using Near Infrared Spectroscopy have demonstrated that 5ml/kg/min are adequate for cerebral perfusion during anesthesia and hypothermia, but the real advantage of a reduced flow is unknown.

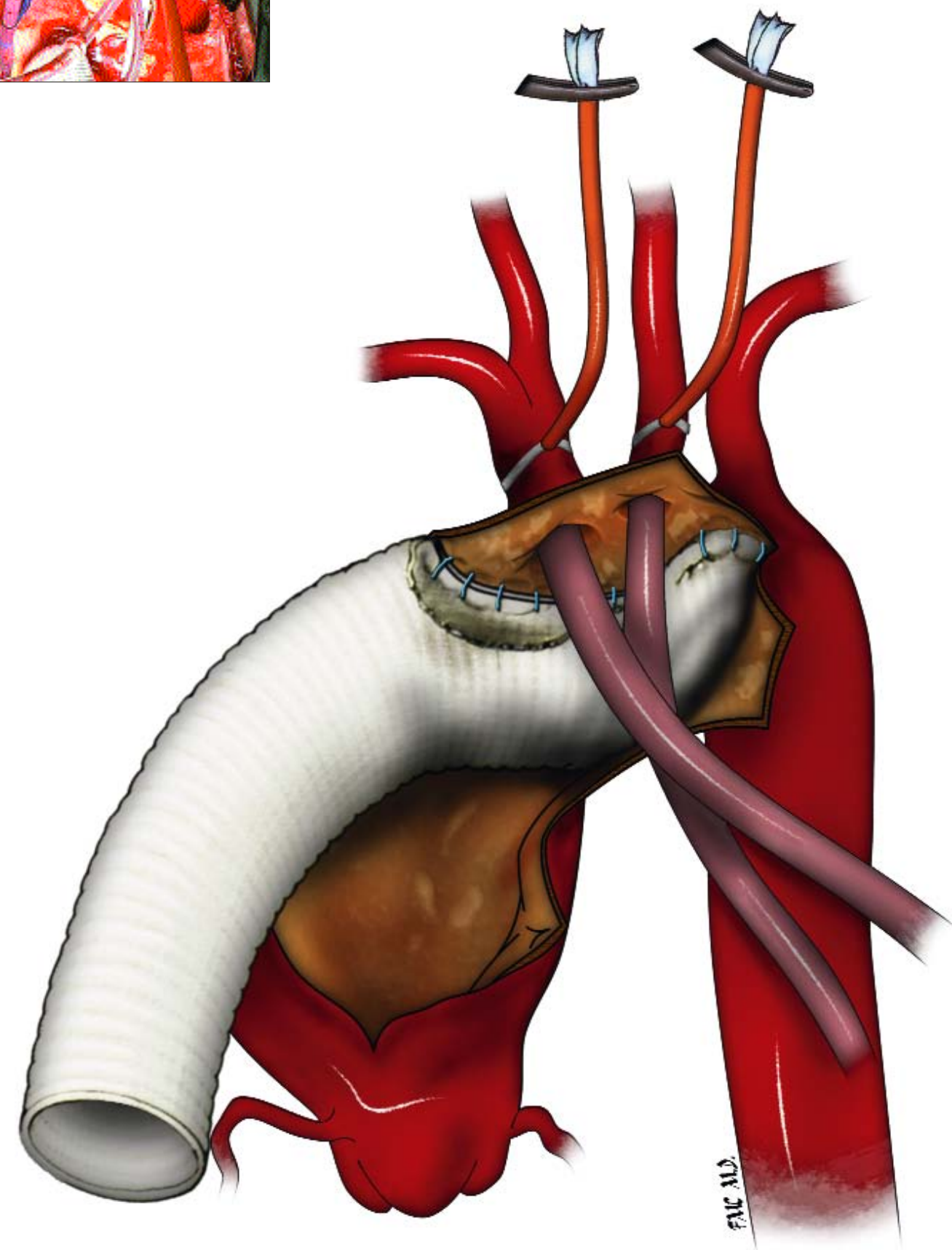
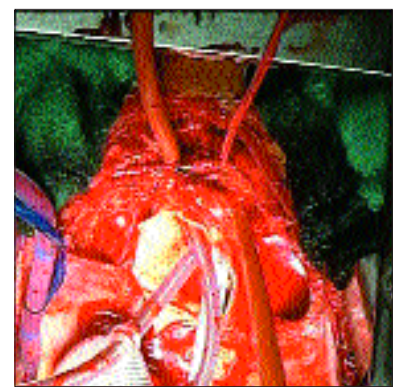
ASCP can be used with deep hypothermia or with moderate hypothermia, as suggested by Kazui.

A growing number of clinical experience reported in the literature shows that moderate hypothermia is a safe technique, allows to maintain the cerebral autoregulation and avoid all undesirable effects of deep hypothermia.

Monitoring the cerebral perfusion is strongly recommended.

The adequacy of cerebral metabolic suppression can be monitored by jugular venous oxygen saturation or by electroencephalographic monitoring. Cerebral perfusion can be evaluated by bilateral radial artery pressure or by pressure monitoring at the tip of the perfusion cannula. Flow distribution can be controlled by transcranial Doppler of middle cerebral artery flow velocity or by NIRS.

Although the use of all these protective and monitoring techniques, brain damage still remain an important concern in arch surgery. Further studies are necessary to determine optimal cerebral protection strategy to reduce the incidence of cerebral damage.





RENAL PROTECTION IN THE CRITICALLY ILL PATIENT WITH OR AT RISK FOR ACUTE RENAL FAILURE. THE ROLE OF FENOLDOPAM

Tiziana Bove  
San Raffaele Scientific Institute, Milano - Italy

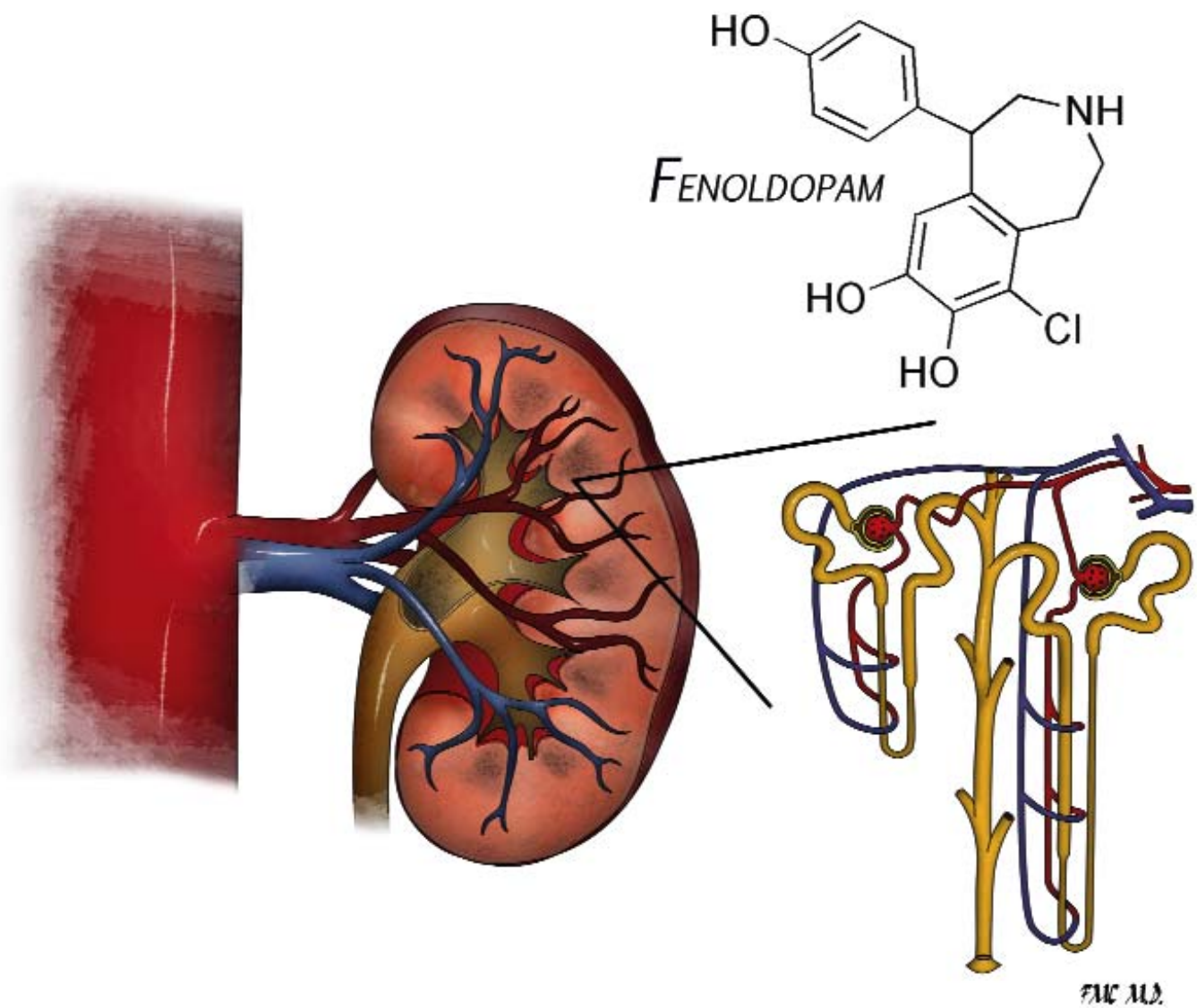
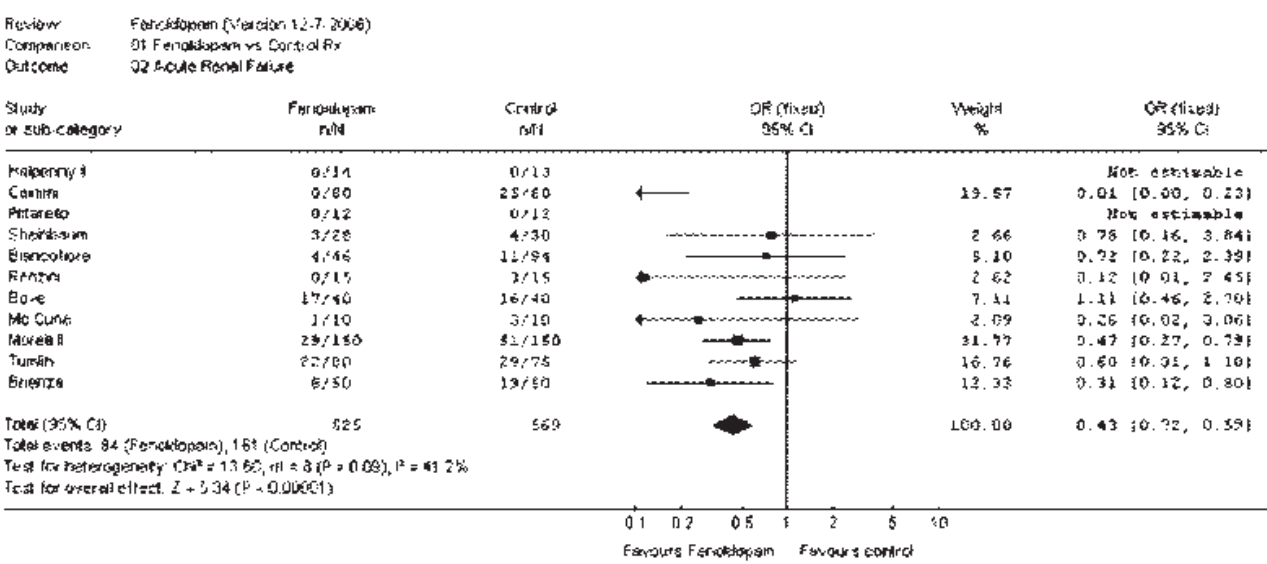
At present, evidence-based medicine dictates that there is no place in clinical practice for dopamine infusion in the prevention or treatment of ARF. Fenoldopam, unlike dopamine, stimulates only dopamine 1 (and not dopamine 2) receptors, thus theoretically inducing greater vasodilation in the renal medulla than in the cortex. Furthermore, fenoldopam has no alpha or beta adrenergic activity, properties that are believed to cause arrhythmias and other adverse effects during dopamine infusion.

Fenoldopam ameliorates ischemic/reperfusion (I/R) injury-induced inflammation via an action involving NF-kB pathway. NF-kB is an inducible transcription factor that is sequestered in the cellular cytoplasm in an inactive state, due to its association with inhibitory kB proteins. With cell stimulation by cytokines, I/R, or endotoxin, there is disruption of the NF-kB-IkB complex. Activated NF-kB subsequently translocates from the cytoplasm to the nucleus, where it activates a number of downstream proinflammatory genes. Consequently, NF-kB has been implicated in the pathophysiologic features of a number of inflammatory disorders, including renal I/R injury. Fenoldopam has anti-inflammatory activity that is mediated via inhibition of NF-kB signaling pathway. Clinical trials were required to examine whether delective DA-1 receptor stimulation may have a role in profilaxis against acute renal injury.

We (Landoni et al AJKD 2007) recently performed a meta-analysis on fenoldopam in critical care settings: a total of 1,290 patients from 16 randomized studies were included in the analysis. Pooled estimates showed that fenoldopam consistently and significantly reduced the risk for acute kidney injury (odds ratio [OR], 0.43; 95% confidence interval [CI], 0.32 to 0.59; P < 0.001), need for renal replacement therapy (OR, 0.54; 95% CI, 0.34 to 0.84; P = 0.007), and in-hospital death (OR, 0.64; 95% CI, 0.45 to 0.91; P = 0.01). These benefits were associated with shorter intensive care unit stay (weighted mean difference, -0.61 days; 95% CI, -0.99 to -0.23; P = 0.002). Sensitivity analyses, tests for small-study bias, and heterogeneity assessment further confirmed the main analysis.

We (Landoni et al JCVA 2008) confirmed the reduction in the need for renal replacement and mortality in a meta-analysis that focused on patients receiving fenoldopam in the setting of cardiovascular surgery. We're conducting a large, multicenter, appropriately powered trial to confirm these results.

A possible future trend in the use of fenoldopam is the intrarenal administration. Selective intrarenal (IR) fenoldopam would increase local concentration, leading to a higher glomerular filtration rate, and, because of first-pass renal elimination, result in lower systemic drug levels and less decrease in systemic blood pressure (BP). It would be appropriate to restudy this renal vasodilator using selective IR delivery.



# ENDOVASCULAR TREATMENT OF COMPLICATIONS FOLLOWING THORACIC AND THORACO-ABDOMINAL AORTIC SURGERY

Franco Grego

Università degli Studi di Padova - Italy

F. Grego, M. Antonello, M. Menegolo, S. Lepidi, S. Bonvini, G.P. Deriu, P. Frigatti

Aneurysmatic evolution of native aorta and anastomotic aneurysms are the most common long term complications after thoracic aorta procedure (TAP). Anastomotic stenosis have also been reported.

From 2000 to 2007, 87 patients were treated with TAP, [31 surgical (ST), 37 endovascular (ET) and 19 by hybrid procedures (HT)]; two cases of ST for complications after ET and four cases of ET for complications following ST (two patients) and ET (two patients) were performed.

A 55 y.o. man had a graft replacement of the descending thoracic aorta (type B dissection) in 1996. The 10 year CT scan showed an aneurysmatic evolution of the distal thoracic aorta, a dissection of the thoraco-abdominal aorta, with perfusion of renal and visceral arteries through the false lumen. The aneurysm was excluded using two endografts (from the distal thoracic graft to the celiac trunk) and, through a laparotomy and aortotomy, an infrarenal aortic fenestration, above the renal arteries, allowed the retrograde reperfusion of renal and visceral arteries.

A 48 y.o. man had elsewhere in 2000 a prosthetic replacement for acute complicated type B dissection; he survived but developed a very severe hypertensive state. In 2003 an angio CT and angiography showed a false aneurysm of the aortic arch, landing zone 2, a kinking with very severe coarctation of the proximal part of the graft, a false aneurysm at the distal anastomosis and an aneurysmatic retrograde perfusion dissection of the thoraco-abdominal aorta.

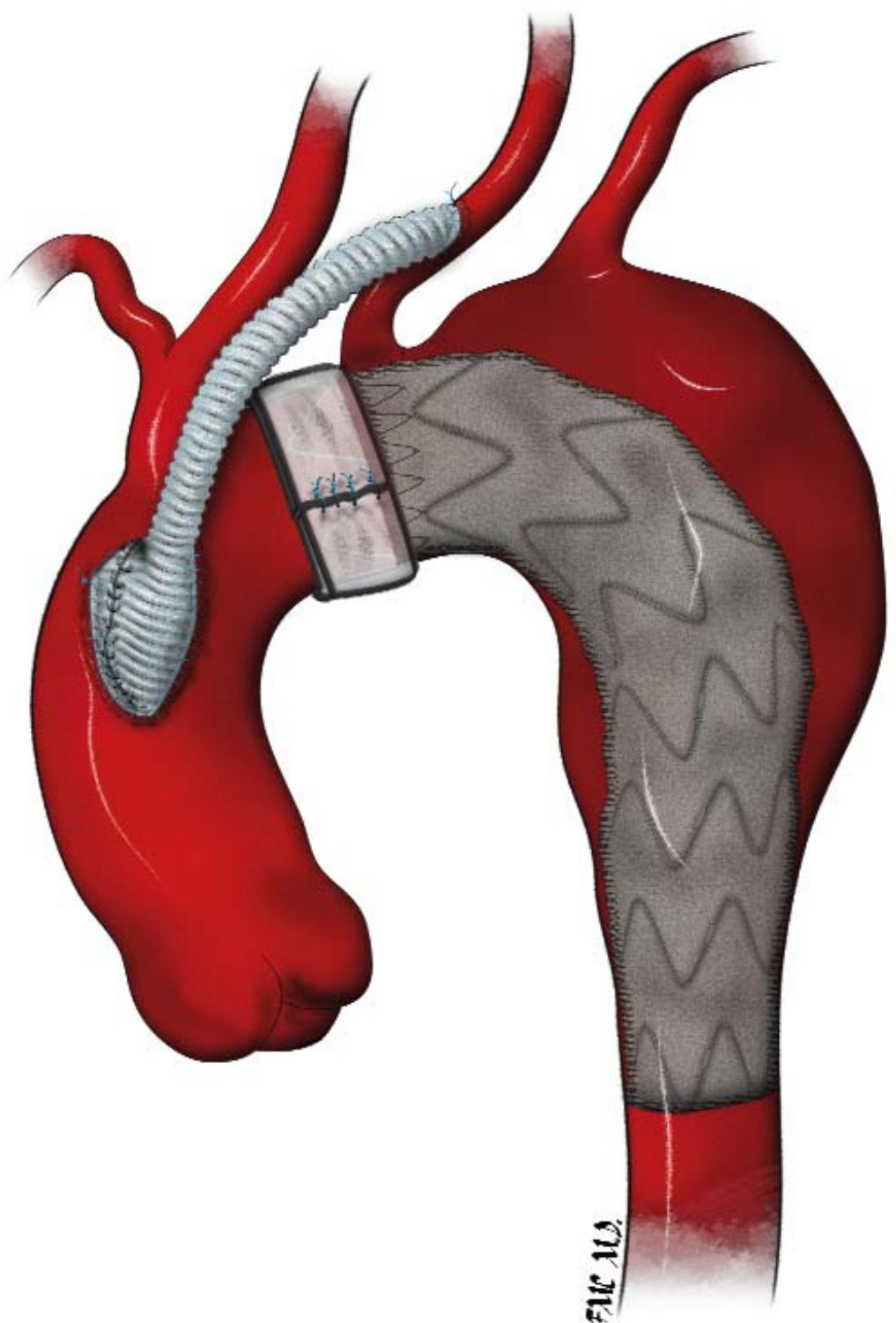

An endovascular procedure was considered as first choice option, with the possibility to be unable to negotiate the coarctation with the endoprosthesis. A "ventral" aorta, with the surgical exclusion of both the zone 2 of the arch and the descending thoracic aorta was considered as the "fire-exit" option. A debranching of the left common carotid artery was considered sufficient to obtain a safe neck: it was performed with a side to side anastomosis of the body of a bifurcated 16 x 8 graft, at the ascending aorta, with the goal to suture end to end the body of the bifurcated graft to a tubular graft, to build, if necessary, a "ventral" aorta. A Talent (Medtronic) endograft was deployed with the free webs at the anonymous trunk, covering the origin of the left common carotid artery, the arch and the proximal and distal pseudoaneurysms. Crossing the tight isthmic stenosis was very difficult but finally it was possible through a "cable" super stiff guidewire going from the proximal access (the second branch of the bifurcated graft) to left femoral artery. The final result was the complete exclusion of the two false aneurysms, enlargement of the prosthesis coarctation and disappearance of hypertension and of the gradient.

A 43 years old man was treated in emergency for polytraumatism by endograft placement for an isthmic rupture. An angio CT scan, performed (2<sup>nd</sup> p.o. day) because of sudden oliguria and feeble femoral pulses, showed a cave in of the graft, occluding the flow with a valve mechanism at every systolic peak.

Timeliness of diagnosis and of the endovascular redo-positioning of a new endograft extended to cover the left subclavian artery resolved successfully the problem.

The last case concerns a huge aneurysmatic evolution of the aortic arch after endovascular treatment of an acute tipe B dissection. The patient underwent a complete debranching of supra-aortic trunks and a second endograft was placed to cover the whole arch.

In conclusion, the endovascular treatment is the best choice and a safe treatment of complex and difficult redo case concentering complications following descending thoracic aorta procedures.





**Piergiorgio Cao**  
*Università degli Studi di Perugia - Ospedale Santa Maria della Misericordia, Perugia - Italy*  
G. Panuccio, G. Parlani, F. Verzini, L. Romano, P. Cao

**Objective.** Late results of all published studies regarding endovascular treatment of abdominal (EVAR) and Thoracic (TEVAR) aortic pathology show an increasing incidence of failures, questioning effectiveness and durability of the procedure. The present study evaluates the causes, incidence, and efficacy of secondary treatment after aortic endografting.

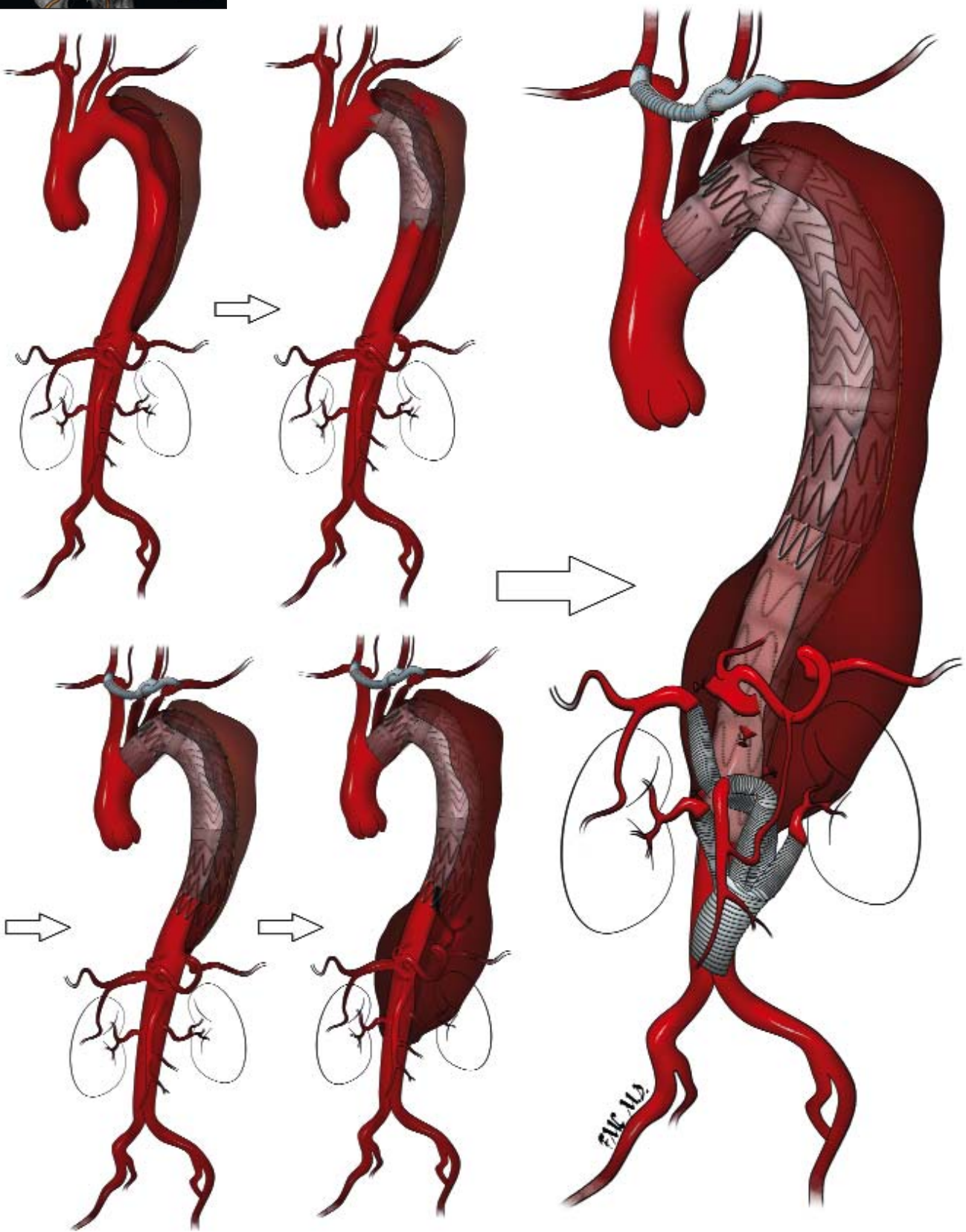
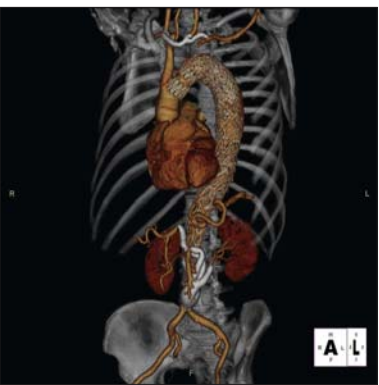**Methods.** A 11-year single centre experience of consecutive 1111 primary successful EVAR procedures and 102 successful TEVAR with commercially available endografts was reviewed. The follow-up program comprised clinical and Computed Tomography scan at 1 month, 1 year and annually thereafter. The data were prospectively collected on all the patients. The medium follow-up was 41 months (range 1-138). None of the patients were lost to follow-up. Reintervention was considered as any secondary procedure either open or endovascular performed after successful T/EVAR. Reintervention failure was defined as any need of subsequent reintervention, conversion to open repair, persistence of T/AAA growth after the secondary procedure, or T/AAA rupture.

**EVAR Results.** A total of 153 patients (14%) required one or more reintervention after EVAR for a variety of late problems, including aortic rupture (N=5), Type I endoleak (N=14), persistent aneurysm growth (N=50), graft migration (N=42), short landing zone (N=24) or vessel/branch occlusion (N=18). Overall, 27 conversions to open repair, 109 endovascular reinterventions (26 proximal cuffs, 36 distal cuffs, 21 catheter based or sac embolizations, 2 iliac angioplasties, 5 renal stent and 19 AortoUniliac [AUI] + cross-over bypass) and 17 surgical procedures not involving endograft explantation (12 cross-over bypass, 2 splenorenal by-pass, 1 axillo-bifemoral bypass, 3 graft limb thrombectomies, and 1 limb amputation, 1 laparoscopic mesenteric clipping) were performed. Kaplan Meier estimates of 24, 48, 72, 96 and 120 months freedom from reintervention were 93%, 81%, 71%, 62% and 60% respectively.

Reinterventions were successful in 80% (123/153) of the patients. At a mean follow-up of 26 months (range 1-86) after reintervention, 24 re-reinterventions were performed: 16 conversions to open repair, 3 AUI+ crossover bypass and 3 sac embolization for persistent AAA growth were needed in patients who have undergone a previous catheter-based reintervention (13 proximal cuffs, 3 distal cuffs and 6 sac embolization), one open graft limb in-situ replacement for infection after conversion to open repair, and one Axillo-bifemoral bypass for occlusion of an AUI bypass. In addition, 2 AAA fatal ruptures after proximal cuff disconnection with rapid AAA growth and 4 AAA persistent growths were recorded in patients with reinterventions. Two patients (1.5%) died perioperatively after secondary procedures, in both patients the indication for reintervention was AAA rupture.

**TEVAR Results.** At mean follow-up of 17 months (range 1-94), a total of 8 patients (9%) required one or more reintervention after TEVAR for type I endoleak in 7 patients and type III endoleak in the remaining patient. Kaplan Meier estimates of 24, 48 and 72 months freedom from reintervention were 88%, 79%, 79% , 62% and 60% respectively. Reintervention was successful in 6 patients (75%), while one patient required conversion to open repair after unsuccessful proximal cuff and another patient required total debranching of supraaortic and visceral vessels and proximal and distal extension after unsuccessful proximal cuff.

**Conclusions.** Risk of reintervention after T/EVAR is high but this is associated with low periprocedural mortality in case of elective procedures. In our 11-year experience, reinterventions were deemed successful in the vast majority of patients; in 13% of these there was need for re-reintervention within 26 months of medium follow-up. Rigorous follow-up program and aggressive attitude towards early and elective correction in case of endograft failure, can ensure high late success rates.





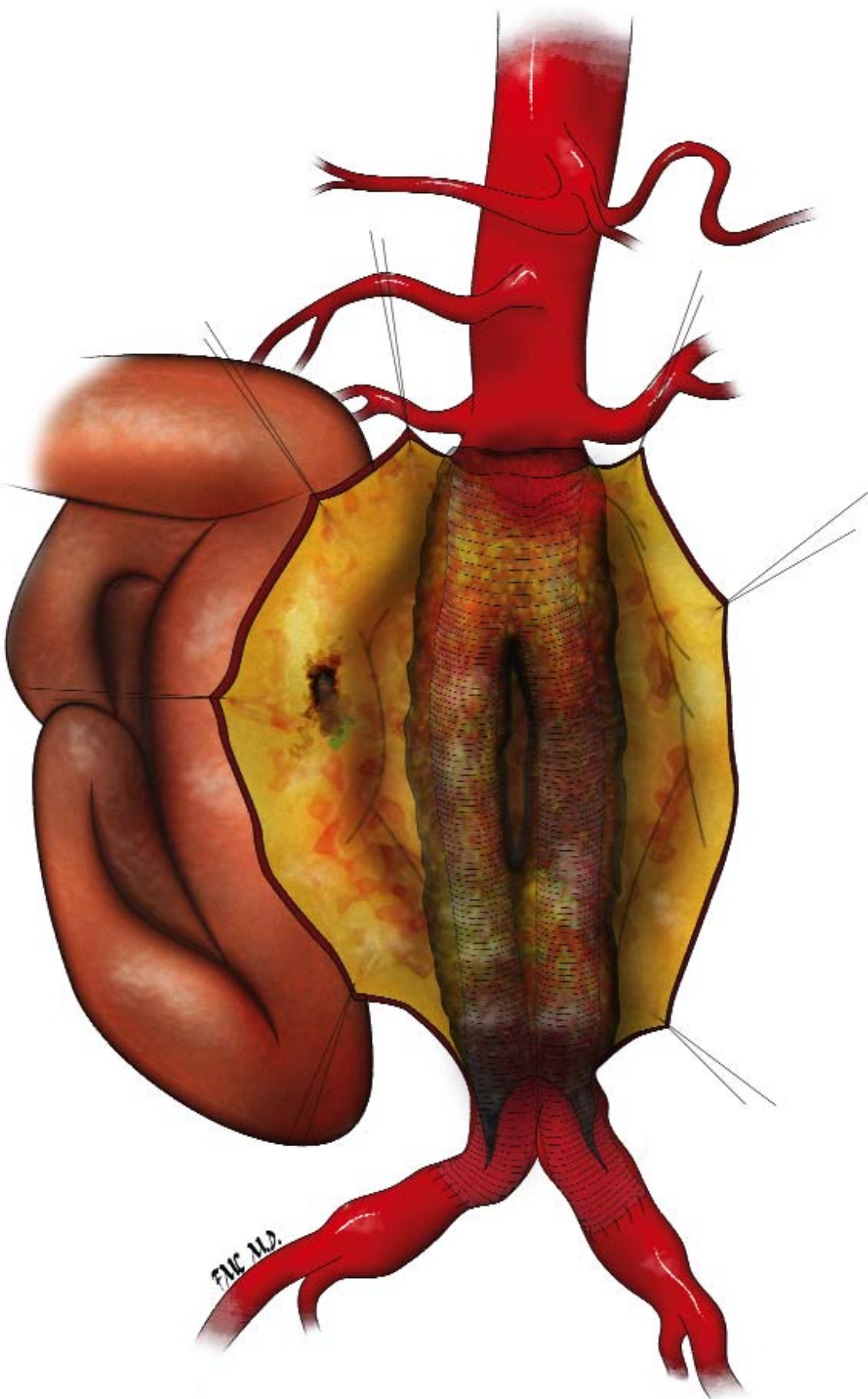
# ADVANCEMENTS IN THE TREATMENT OF THORACIC AND ABDOMINAL GRAFT AND STENT-GRAFT INFECTION

**Olivier A. Goëau-Brissonnière**  
*Ambroise Paré University Hospital, and Versailles Saint-Quentin en Yvelines University, Boulogne-Billancourt - France*  
O. A. Goëau-Brissonnière, M. Coggia, I. Javerliat

The management of prosthetic vascular graft infection remains a formidable challenge. The two main objectives are to eradicate the infection and to maintain an adequate limb perfusion. Systemic antibiotic therapy and removal of the prosthetic material remain the two cornerstones of the treatment, with different options for revascularization. Extra-anatomic bypass has been considered as the gold standard, with high mortality and morbidity rates. In line bypasses through clean tissues were also proposed, but a major advance was obtained with arterial allografts, which allow in situ revascularisation for thoracic or abdominal prosthetic infections.

The availability of prosthetic grafts resistant to infection would also help, in particular when an allograft is not available. Grafts containing silver and collagen have been proposed with some encouraging results, but they are probably less resistant to infection than rifampin soaked polyester prostheses. The experience with rifampin loading led us to evaluate a new graft preloaded with rifampin and tobramycin. To develop this material, tobramycin was added to rifampin because of its good activity against Gram-negative bacteria. That material is a true innovation since, as yet, no manufactured graft has been made commercially available prebonded with antibiotics. One of the greatest advantages of grafts prebonded with antibiotics would be their availability in any circumstances, especially in emergency, or in patients at high risk of infection. Using experimental models in the dog, we showed that the healing of this prebonded graft was similar to that of commercial gelatin-sealed grafts, without any signs of toxicity. We then recently demonstrated the antibacterial efficacy of this new rifampin/tobramycin bonded grafts in an established dog model of graft infection. In these experiments, 6 dogs receiving an antibiotic-bonded gelatin-sealed polyester grafts loaded with rifampin and tobramycin were protected from a local *Staphylococcus aureus* contamination, whereas 5 out of 6 dogs receiving a standard gelatin-sealed graft had graft infection. Further studies are definitely mandatory to confirm our experimental findings, but these experimental results are in line with previous clinical results with rifampin soaking.

Another issue regarding the treatment of prosthetic infections is the emergence of stent-graft infections, which incidence should be close from that observed after conventional surgery. Despite the report of a few cases treated without graft removal, aortic rupture may happen in these patients. Successful treatment implies endograft removal, which can be quite difficult, in particular with endografts with a suprarenal fixation. Revascularization with arterial allografts may also be complex in these patients, but it remains the most logical options, in particular when additional bypasses are necessary to visceral arteries.





**Enrico M. Marone**

*Vita-Salute San Raffaele University, Milano - Italy*

R. Chiesa, G. Melissano, E. M. Marone, M. Marrocco-Trischitta, A. Kahlberg

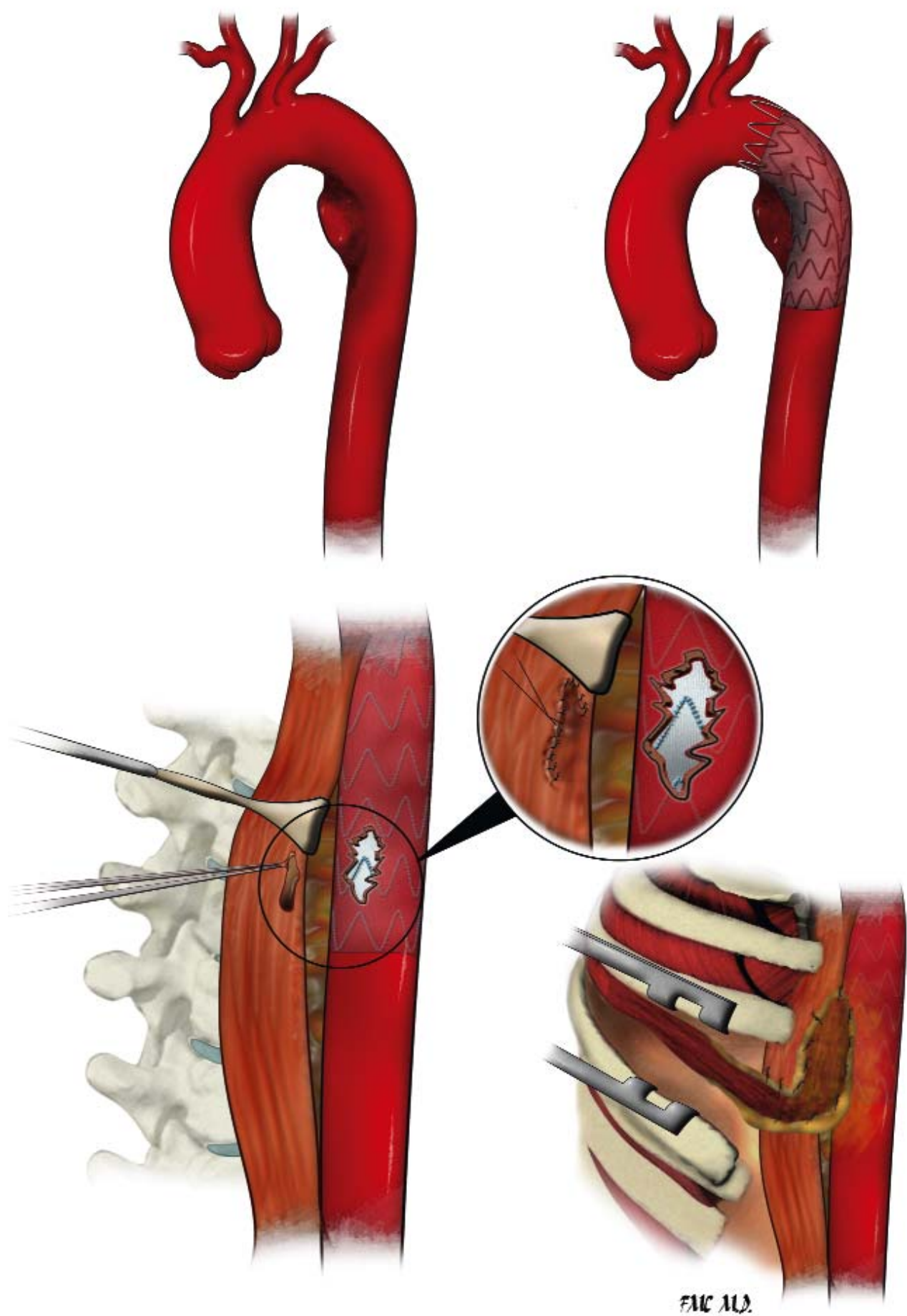
**Introduction.** Aortoenteric (AEF) and aortobronchial (ABF) fistulae represent an uncommon and highly fatal condition, even if timely and adequately treated. Conventional treatment includes open surgical repair, with still high mortality and morbidity rates. Several alternative strategies have been recently reported in the literature including endovascular repair. However, no general consensus exists on the optimal approach of this pathology. Furthermore, secondary AEF and ABF are described following both open and endovascular surgery of the thoracic aorta.

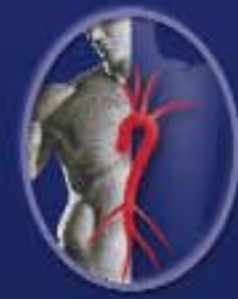**Methods.** A National Survey was conducted on voluntary basis among Italian University and Hospital Centers with an Endovascular Program. The questionnaire had two sections. The first inquired about endovascular repair of an established AEF or ABF. The second section aimed to determine the rate of AEF/ABF as postoperative complications after endovascular treatment of thoracic aortic pathology (TEVAR).

**Results.** Sixteen Centers agreed to participate and provided data on their patients. Overall, between 1998 and 2008, 1.034 patients were treated by means of TEVAR.

- 1) In 23 patients (2,2%), the indication to treatment was an AEF and/or an ABF. In 12 of these cases (52%), an associated surgical open procedure was necessary. Thirty-day mortality rate of AEF/ABF endovascular repair was 35% (8 cases).
- 2) Sixteen AEF or ABF were reported as a complication of stent-graft implantation (1,5%). In 13/16 patients, indication to TEVAR was a primary aortic pathology (complicated in 5 cases), and in 10 of these (77%) an adjunctive or secondary procedure was observed during or after TEVAR. In remaining 3/16 patients, indication to TEVAR was a secondary aortic lesion following previous open or endovascular surgery. Thirty-day mortality of post-TEVAR AEF/ABF was 69% (9 patients).

**Conclusions.** Stent-grafting for AEF and ABF represents a viable option in emergent and urgent settings. However, this procedure alone does not appear to ensure definitive and durable results and should be regarded as a “bridge” solution. Moreover, the development of an AEF or an ABF after TEVAR must be always considered by endovascular surgeons, particularly in case of complicated etiologies or secondary procedures.





'08

## THE RECENT HISTORY OF AORTIC SURGERY: FROM THE 1950s TO THE PRESENT

Angelo Argenteri

*Chair Vascular Surgery - Università degli Studi di Pavia, A.O. Maggiore di Lodi - Italy*



# THE RECENT HISTORY OF AORTIC SURGERY: FROM THE 1950s TO THE PRESENT

“Madmen break down doors,  
wise men follow them through.”  
*Persian proverb - XII<sup>th</sup> century*

No cultural or scientific evolution ever follows a straight, uniform and continuous course, but advances in lurches between intuitions, developments and second thoughts, periods of progress and periods of inertia. When a new concept emerges, it is followed by a period of stasis and critical evaluation: the concept then becomes the essence of the long process and, depending on its originality, is assimilated or rejected.[1]

This process always starts with preparatory stages, not always related to each other; indeed, they are often independent and separate, sometimes opposing each other or very distant. Even apparently extraneous events, such as socio-economic changes and movements, can concur in the birth of a new cultural or scientific development. An example of this is Impressionist art, whose birth was surreptitiously announced and whose chromatism originated from the Italian Primitive artists.

Furthermore, a mature development may be unable to make the break through into a new cultural or scientific acquisition along orthodox lines, but does so through serendipity: an intuition occurring in the right person, who is in the right place at the right moment.

All these considerations can be applied to aortic surgery, which appeared as a new concept in surgery, but whose primordial bases can be traced back as far as three centuries ago.

In a period in which a disease triggered only reactions but not a search for solutions, some real Titans of medicine made the first imperceptible steps towards the future: Amboise Parè (1510-1590) with his vascular ligatures, Valsalva (1666-1723) and his pupil Morgagni (1682-1771) with their post-mortem descriptions of thoracic and abdominal aneurysms, John Hunter (1728-1793) who first understood the need to block the dilation of aneurysms by ligating them, Scarpa (1747-1832) with his pupil Porta (1800-1875) who introduced the concept of aortic dissection, Laennec (1781-1826) with his first semiological use of a phonendoscope in aneurysmal disorders, Cooper (1768-1841) who ligated an aortic aneurysm distally and triumphantly proclaimed “*Gentlemen, I have the pleasure of informing you that the aorta is now hooked upon my finger*”, Corradi (1836-1902) who with an electrical mechanism tried to induce thrombosis in the aneurysmal sac forerunning future intravascular treatment, Doppler (1803-1853) with his physics, Roentgen (1845-1923) with his X-rays and Scipione Riva Rocci (1867-1937) with his invention of the sphygmomanometer.[2,3,4,5,6]

All of these, unwittingly, were points along the line of the development of aortic surgery; a line that became stronger at the beginning of the XX century and then fully defined and codified in the middle of the last century. The XX century was a period of major political, socio-economic and geo-ethnic changes, industrial revolutions and discoveries that were to transform human life; aeroplanes, cars, artificial fibres, new means of communication, atomic energy, computers and female emancipation are just a few examples. It was also the century of devastating wars, which tragically provided the cases for learning and development in the newborn field of vascular surgery from which aortic surgery was to gain further impulse.

New developments were fundamental in the infancy of aortic surgery: the inventions of cerebral angiography in 1927 by Moniz (1874-1955) and aortography in 1929 by Reinaldo dos Santos (1880-1970), both Portuguese, angiocardiology also in 1929 by the German Forssman (1904-1979), the first clinical use of heparin in 1940 by the American Murray (heparin

Fig 1



Fig 2



Fig 3

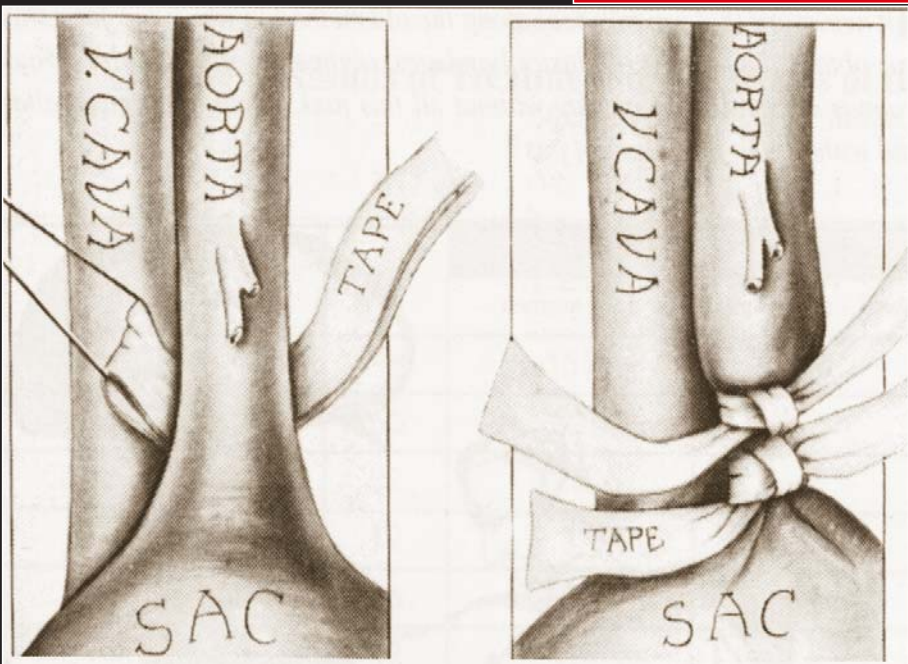


Fig 1  
A. Carrel.

Fig 2  
A. Carrel on the  
“Time” cover.

Fig 3  
Proximal ligation of aortic  
aneurysm by R. Matas.

had been discovered in 1916 by McLean, a young student in Howell's laboratory), the development in 1953 of the catheter bearing his name by the Swede Seldinger (1921-1998), the clinical use of the Doppler effect in 1959 by the Japanese Satomura, computed axial tomography conceived by Hounsfield and Cormack in 1968, and Lauterbur's development of nuclear magnetic resonance technology in 1973.[5]

The embryogenesis of aortic surgery took place at the beginning of the century: the Verne of vascular surgery, Alexis Carrel (1873-1944) from Lyon, appeared on the scene. Carrel, a meteor in the galaxy of surgery, was a larger than life character, an eclectic and innovative person, polyhedral and humanist, as well as egocentric (he never wanted the names of any of his collaborators on his publications).

He was the pioneer of a new surgical philosophy. He understood that a surgeon should not limit himself to manual procedures, but apply his knowledge to the search for why. He devised the technique of vascular anastomosis and his research on cell cultures earned him a Nobel Prize in 1912.[7,8] His studies on various aspects of the vasculature, many at the basis of aortic surgery, are surprising: the use of cryopreserved arteries as vascular substitutes, the replacement of an artery by a segment of vein and its arterialisation, surgery of the thoracic aorta, heart valve operations, the use of the vena cava in surgery of the abdominal aorta, heart transplantation, extracorporeal circulation (in collaboration with C. Lindberg, the transatlantic aviator).[9,10,11,12,13,14] He was even the forerunner of endoprosthetic treatment of thoracic aneurysms, experimenting with permanent intubation of the thoracic aorta.[15]

He knew that he was clever but his egocentricity matched his greatness: *"I am a creator of techniques, others must apply them"*.

His life was equally turbulent. In 1904 he accompanied a young women with severe tuberculous peritonitis to Lourdes and witnessed her healing; this led to his conversion and he published a book on the event (the protagonist is a young doctor called Lerrac, his own name written backwards). The violently antireligious radical socialism of the time did not forgive his unconditioned acceptance of a miracle and his career was slowed. He, therefore, left France, first for Canada and then for the United States where he was to remain until 1939, apart from a period in the French army during the First World War. On his return to his native country in 1941 he was the driving force behind the creation of the *"Fondation française pour l'étude des problèmes humaines"*, in line with his eugenic philosophy that the duty of science is to free mankind of diseases and aid spiritual progress. This position was to be the basis of his book *"Man, The Unknown"*.

France was under German occupation; Carrel believed fervently in his foundation and managed to obtain generous financial support from the collaborationist Vichy regime. This fact was to be held against him, and following the Liberation he was accused of collaborationism. This was the start of a gloomy period and ostracism; furthermore, he had developed coronary artery disease. On the 5<sup>th</sup> November, 1944 the Liberation Committee went to arrest him at his home, but no-one answered; at 8 p.m. the free French radio falsely announced that Carrel had fled to avoid being condemned as a collaborator: he had, in fact, died nine hours earlier of a myocardial infarction.[16] [Fig. 1, 2]

It was hoped that endosaccular thrombosis could be used as a treatment for aneurysmal aortic pathologies. Rudolph Matas (1869-1954) first experimented with thrombosis induced by wiring and electrolysis and then passed to proximal ligation of the neck of the aneurysmal sac; for a long time this was to be the only proposable treatment, and was also carried out by W.S. Halsted (1852-1922) and E.T. Kocher (1841-1917).[2,17,18] It should be said that ligation had already been attempted on a thoracic aneurysm by T. Tuffier (1857-1929) and H. Kummel (1852-1927).[2] [Fig. 3]

Meanwhile, René Leriche (1879-1955) was studying aortic disease caused by stenotic occlusion, defining the symptoms of the pathology that was take his name as *"Leriche's syndrome"*, and foresaw its treatment with grafting: *"the ideal treatment of arterial thrombosis is the replacement of the obstructed segment with a vascular graft"*. [19,20]

Leriche, from Roanne, started his career at Lyon as an assistant to Poncet and as an external pupil of Jaboulay, who was Carrel's mentor. Carrel also worked in Poncet's service and a firm friendship grew up between Leriche and Carrel. Poncet realised the capacities of his young pupil and encouraged him to visit other schools of surgery: Leriche studied at Venice under Giordano, at Berne under Kocher where he was surprised by the pedantry of the Swiss who changed his linen gloves six times during a single operation, and at Leipzig under Trendelenburg.

Having become an associate professor, Leriche joined his friend Carrel in the United States who introduced him to various surgeons: Murphy and Graham at Chicago, the Mayo brothers at Rochester, and Halsted at Baltimore. At the Rockefeller Institute in New York he got to know Flexner, who never lost an occasion to criticise the Latin art of improvisation when undertaking new surgical techniques *"you in France want to cook an omelette in a top hat"*.

In 1924 he was invited to direct the surgery service at Strasbourg where he established an internationally renowned school of vascular surgery; his students included Fontaine, Kuntlin, Arnulf, Joao dos Santos, and DeBakey.[Fig. 4]

He continued to travel, maintaining contacts with the major schools of surgery; in London the President of the Royal College of Surgeons, Sir Moynihan, showed him a flask containing a piece of perforated small bowel belonging to Napoleon. Moynihan explained that *"Napoleon did not die from gastric carcinoma. But England did not want the truth to be known, for fear of being believed negligent and responsible for the death of the Emperor"*. As a good Frenchman, Leriche tried, unsuccessfully, for years to bring this reliquary back to French soil; it was eventually destroyed during the bombardments of London.

When Leriche retired in 1941, he was succeeded by his former pupil R. Fontaine (1899-1979), who classified the stages of lower limb peripheral vascular disease. He passed his retirement in his home Clos Bel Horizon at Cassis, in the calanques near Marseille, where he died of pulmonary oedema.[Fig. 5, 6]

In the 1940s, radical treatment of aneurysms was still not envisaged; attempts were, therefore, made to prevent their expansion by wrapping the mass with materials such as cellophane, fascia lata, omentum, or polyvinyl sponges, hoping that the peri-arterial fibrosis thus induced would prevent further growth of the aneurysm.[21,22,23] The technique was mod-



ified in the light of research by Page on kidneys experimentally wrapped to induce hypertension as a result of arteriolar thrombosis. The results were disappointing.

One famous victim of this method was Albert Einstein (1879-1955). In December 1948 Einstein developed abdominal pain and was diagnosed as having a large abdominal aneurysm; he was operated on by R. Nissen at Brooklyn Jewish Hospital in New York. Since lateral isolation of the mass was difficult because of peri-aortic fibrosis, Nissen decided to limit the cellophane wrapping to only the anterior surface and, after three weeks, Einstein was discharged. On April 12<sup>th</sup>, 1955 Einstein again presented with symptoms related to his aneurysm and on the 15<sup>th</sup> of the same month was admitted to Princeton Hospital where F. Glenn, a surgeon at the Cornell Medical Center in New York, offered him radical treatment (which, by then, had been in use about 5 years). Einstein refused: *"I want to go when I want. It is tasteless to prolong life artificially. I have done my share, it is time to go. I will do it elegantly"*. He died three days later of a rupture.

Blakemore rediscovered intrasaccular thrombosis, which he induced through the use of endoluminal wires and the passage of a 100 Volt current. The results of 11 cases so treated (of which two were thoracic aortic aneurysms) were disastrous: ten ruptured.[24] Nevertheless, Blakemore persisted with the method and in 1952 presented his experience of 365 cases at the Congress of the Southern Association.[25]

The knowledge about aortic aneurysmal pathologies was almost sufficient, but, having discarded ligation and thrombosis, it was becoming clear that radical treatment was likely to be the only truly effective solution, although this still remained a nebulous option. The words of Bigger, at the Congress of the American Surgical Association in 1940, are telling: *"Judging from the literature, only a small number of surgeons have felt that direct surgical attack upon aneurysms of the abdominal aorta was justifiable, and it must be admitted that the results obtained by surgical intervention have been discouraging"*.[26]

There seemed to be a standstill, which was also a reflection of the period; the whole world was emerging from a war that had obliterated, for winners and losers alike, every spiritual and material force. But, as history teaches us, such times are always followed by a period of regenerating vigour. In the context of aortic surgery, the melting-pot was Europe, the scene of recent events.

In 1941, at Ann Arbor, Alexander resected an 18-cm long aneurysm from an area of aortic coarctation in an 19-year old. Alexander excised the aneurysm without restoring the continuity of the vessel and bound the two proximal and distal aortic stumps with sutures on cotton tape.[27]

He was followed in Europe by C. Craaford (1900-1984), a surgeon from Sweden, who treated aortic coarctation in two patients, aged 12 and 27 years old, restoring vasal continuity with a T-T anastomosis of the stumps.[28]

The ideal pathway was, by now, clear: the pole star guiding further developments was the replacement of the aneurysmatic or stenotic part of the aorta by a new segment. The problem remained of identifying the material that could best replace the segment of artery. This aspect had already been under investigation for a considerable time and there was still

Fig 4



Fig 4  
R. Leriche's group  
in Strasbourg:  
R. Leriche,  
M. E. DeBakey,  
J. Kunlin,  
J. C. Dos Santos,  
R. Fontaine.



Fig 5




Fig 6

Fig 5  
R. Leriche:  
drawing by his friend  
H. Matisse.

Fig 6  
R. Leriche  
autobiography.

the scepticism expressed twenty years early by Leriche, on the 5<sup>th</sup> December 1923 at the Academy of Surgery during his conclusions on the aortic bifurcation syndrome: *“the ideal treatment of occlusion of aortic bifurcation would be excision of the occluded part of the vessel and reestablishment of arterial continuity if at all possible. The problem is that, unfortunately, this ideal will probably never be achieved”*.

One of the people searching for a suitable graft material was a young French surgeon, Jacques Oudot (1913-1953). Oudot worked at the Hotel Dieu in Paris and dedicated himself enthusiastically to experimental surgery. From the end of the 1700s there had been an anatomy theatre in rue du Fer Moulin where all unclaimed corpses from Parisian hospitals were sent for anatomical studies; later the theatre became the site of real dissection training for young surgeons under the direction of Farabeuf first and then of Tillaux (whose statue is at the entrance). In the early 1990s, a small centre of experimental surgery was added; it was there that Oudot passed his free time.[Fig. 7]

After a period in Boston, Oudot devoted himself entirely to vascular surgery, studying possible vascular replacements. He was joined in 1949 by a young intern, J. Natali, who was later to be the head of an important French school of surgery. Oudot believed in homografts and, using Topostatin (thrombin), experimentally induced thrombosis of the aortic trifurcation in dogs (the internal iliac artery originates from a common branch in dogs) in order to then replace the thrombosed segment with refrigerated canine aortic grafts (preserved in Tyrode and Hanks’ solution). He started these experiments in 1950 on about twenty animals, but the mortality rate was high; by the end of the year, Oudot had more experience and the survival of animals with a patent homograft reached 80%. The experiments were continued in the following year and operated animals could survive for about a decade. The results were described in Natali’s doctoral thesis.[29,30]

Oudot’s labours were not in vain: in November 1950 he was referred a 51-year old woman with aortic obstruction and trophic lesions of the left leg. Oudot felt ready and understood that the moment had arrived: on the 14<sup>th</sup> November he prepared the aortic bifurcation, via an extraperitoneal route, and anastomosed a homograft to the aorta and both iliac arteries. The right iliac anastomosis was difficult, as expected, but the immediate post-operative recovery was acceptable. The right femoral pulse was absent, but the patient was asymptomatic. The control angiography on the third day did not show the right branch. The patient did, however, remain asymptomatic and was discharged. In the following May she developed symptoms in the right leg. Oudot re-operated on the 8<sup>th</sup> May, carrying out the first cross-over, using a homograft anastomosed between the external iliac vessels and tunnelled anteriorly to the bladder. The patient died three and a half years later; during the post-mortem, the graft was found to be thrombosed.

On the 16<sup>th</sup> May of the same year he repeated the operation with immediate success. In the following two years he was to operate on another 11 patients of whom 4 died early. An angiographic control of one case demonstrated that the graft was patent after nine years.[31]

Oudot had opened the way with homografts and others followed him immediately: De-

Bakey, in the United States, reported 22 cases in 1954, and Rob and Cockett, both in England, reported, respectively, 13 and 12 patients in 1956.[32,33,34]

Oudot, an experienced mountaineer, adored climbing and was proposed as a doctor in the first French expedition to conquer Annapurna, which means “the goddess of plenty” in Sanskrit, a mountain 8091 m high in the Nepalese Himalayas. The expedition leader was M. Herzog, with his team comprising the mountaineers J. Couzy, M. Schatz, L. Lachenal, G. Rebuffat and L. Terray and the film director M. Ichac.

On the 3<sup>rd</sup> June, 1950 Herzog and Lachenal reached the peak; this was the first ‘8000 m’ conquered by man. Both Herzog and Lachenal developed frostbite in their hands and feet; Lachenal had to have his forefeet amputated. Oudot assiduously provided intra-arterial injections of acetylcholine and novocaine.[35] [Fig. 8]

Oudot’s passion for the mountains was to prove fatal: in 1953 while he was driving to Chamonix for a climb, he had a car accident and was admitted to a small hospital where he was found to have a ruptured spleen. The local surgeon, daunted by his illustrious patient, who was more famous for his ascension of Annapurna than for his scientific merits, adopted a waiting policy that was fatal for Oudot.

With Oudot 1950 became the year of three world firsts: the aortic homograft, the cross-over, and the conquest of Annapurna.

Unfortunately, his experimental work on liver transplants and the use of homografts in surgery of the aortic arch were never published.

The pillars of Hercules at the time were aortic aneurysms; remembering the period, D. Cooley was to say *“I also recall the insanity and trepidation that surgeons experienced in approaching such lesions [aortic aneurysms] especially when rupture was threatening”*. [36]

The French school was in a moment of grace: Charles Dubost (1914-1991), a forty-year old surgeon, made the definitive response to Carell’s prediction *“Therefore, we must find a method which enables repair of the aortic wall after a partial or complete resection”* [13], when he became the first surgeon to treat an abdominal aneurysm successfully. Dubost was born in Saint Gaultier in India where his grandparents had emigrated. The family soon returned to France where his father opened a pharmacy in the Latin quarter. After the war, during which he served as a medical sub-lieutenant in the artillery, he returned to Paris where the leading surgeons of the time were Henri Mondor and François Maximilien de Gaudard d’Allaines. Dubost started to work with D’Allaines.[Fig. 9]

D’Allaines was a man and surgeon of great style; he was a member of one of the oldest noble families of France and, when he could, he returned to the family chateau in Chalon sur Saone in Borgogna (if you can, visit the nearby intact hospital from the 1300s). There he was to die tragically, after his retirement, thrown from a horse while inspecting his estate.

Dubost had an innate elegance with an undeniable ‘physique du role’. The understanding between master and pupil was immediate. D’Allaines had correctly guessed the surgical trends of the time, including the neonatal cardiovascular surgery. He encouraged his disciple towards this surgery and, in 1947, invited A. Blalock (1899-1964) from Baltimore and his pupil H. Bahnson to Paris at the Hopital Broussais to operate on some cases of Fallot’s



tetralogy. Blalock, who was a pupil of Halsted at John Hopkins, had developed, together with the paediatrician Helen Brooke Taussig, a treatment for Fallot's tetralogy. D'Allaines also provided Dubost with a laboratory of experimental surgery in the same hospital.[Fig. 10]

In 1950 Dubost operated on an aneurysm of the ascending aorta: *"After having opened my patient's chest, I found a large saccular aneurysm of the ascending aorta, the neck of which was 6 cm long. I decided then to attempt to resect the aneurysm and to suture the aortic wall. Using a Satinsky clamp, I was able resect the aneurysm and suture the two edges of the aortic wall, using separate U-stitches completed by a continuous suture. The recovery was uneventful and the patient survived for many years"*.

On the 29<sup>th</sup> March 1951, the much awaited moment arrived. Dubost was to wrap a bulky abdominal aneurysm in a 50-year old man; clinically the patient presented with a pulsatile mass in the left para-umbilical region. The right femoral pulse was weak and the left one was absent; these clinical findings were confirmed by oscillography (Doppler studies were still far in the future). The patient had a history of a myocardial infarction 1 year previously. Aortography revealed a fusiform aneurysm with a short neck; the left iliac artery was occluded and there were two aneurysmal dilatations at the origin of the right iliac artery; the inferior mesenteric artery was not opaque. Dubost considered that wrapping was not an appropriate management, particularly because of the occlusion of the left iliac artery and swiftly decided for resection with insertion of a homograft performed via a retroperitoneal thoracoabdominal access with the division of eleven ribs. His descriptions is exemplary: *"That was reason why I decided to try to perform a resection of the aneurysm associated with an endarterectomy of the left common iliac artery, and re-establish the continuity of the aorta using a human aortic graft. I performed this operation on March 29, 1951 using a left thoracoabdominal approach. Retraction of the peritoneal sac disclosed an enormous aneurysm extending from the origin of the renal arteries to the common iliac arteries. Control of the aneurysm was obtained by a clamp placed proximally to it, immediately below the renal arteries. Both external and internal iliac arteries were controlled. Both common iliac arteries were section and then the aneurysm dissected from below upwards. The stripping was troublesome near the common iliac veins and inferior cava, which were adherent in places to the aneurysmal sac, a fragment of which had to be left in some places. The lumbar vessels were sectioned without ligation. The inferior mesenteric artery did not bleed from the proximal cut end but did spurt blood from the peripheral end. The aneurysm, entirely freed, was turned upwards and sectioned 2 cm from the clamp on the aorta. The cut end of the aorta proximally and the cut end of the right common iliac artery peripherally were trimmed in order to interpose the graft (14 cm in length, taken from the thoracic aorta of a 20-year old girl 3 weeks previously). The superior anastomosis of the aortic graft was carried out with 5-0 silk. Since we did not have a Y shaped graft, it was necessary to make an end-to-end anastomosis between the graft and the right common iliac artery. The obstruction in the left common iliac artery was removed by endarterectomy and, after section of the internal iliac artery, which was itself blocked, it was anastomosed to the side of the graft immediately above the other anastomosis. After removal of the clamp, the three anastomoses were clearly patent, and the femoral pulses were felt to be equal on*

Fig 7



Fig 8

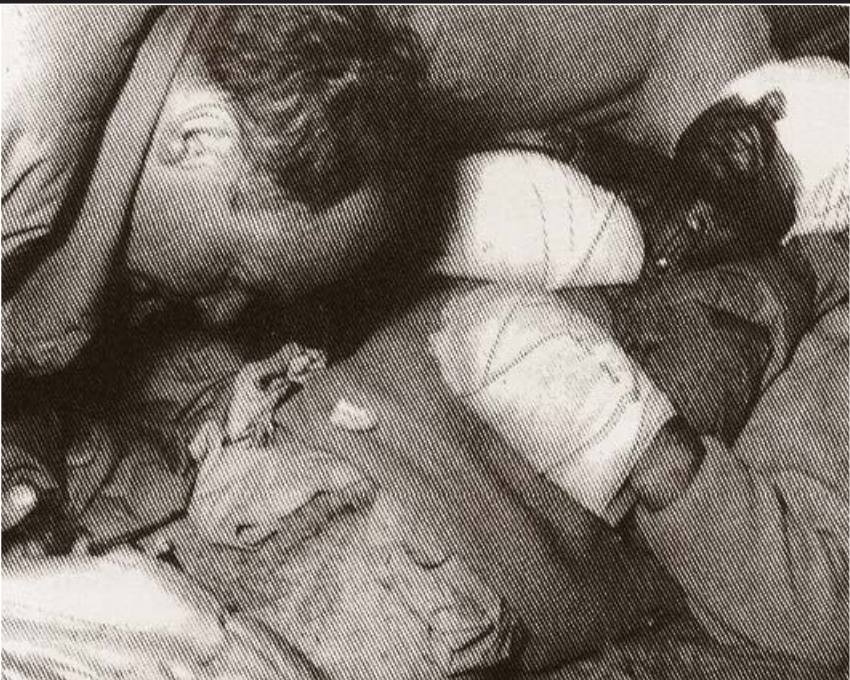

Fig 9



Fig 7  
J. Oudot.

Fig 8  
J. Oudot on  
Annapurna provided  
L. Lachenal with femoral  
intra-arterial injection.

Fig 9  
C. Dubost.

*both sides*". The patient lived for another 8 years and eventually died, in England, of a myocardial infarct.

This success was like a stone thrown into a pond; DeBakey named this type of surgery as "*Dubost's operation*".[37,38] [Fig. 11]

In the same year, Dubost carried out the first kidney transplant in Europe, which was unsuccessful because of rejection. The donor had not given his consent, since he was a criminal who had been guillotined the day before at the Santé. This fact upset Dubost, who saw it as a premonitory sign and decided not to carry out any other kidney transplants personally.

In 1955 he was the author of another European 'first', when he repaired an interventricular defect in a 6-year old child using extracorporeal circulation.

In 1963 Dubost succeeded his master D'Allaines at the head of the Service of Cardiovascular Surgery at the Hopital Broussais, which became named after Leriche. His first collaborators were to become leading surgeons: Blondeau, Claude d'Allaines, Guilmet, Soyer, Piwnica, and Carpentier.

In 1968 he carried out the first heart transplant in Europe: the recipient was a Dominican friar, Damien Boulogne, who survived for 18 months. After the first transplant in the world, performed by C. Barnard (1922-2001) on the 3rd December, 1967, Dubost just beat Henry from Marseilles in the European enterprise. Both had been incited by De Gaulle who, in line with his idea of the grandeur of France, wanted the record to be French.

Dubost retired in 1982 and died in 1991 of bladder cancer at the Hopital Saint Michel in Paris. Even in death he knew how to distinguish himself from others, being buried in the Passy cemetery, an aristocratic necropolis in the shadow of the Eiffel Tower, together with the couturiers Patou and Givenchy, Guerlin, the artist Manet, the industrialists Renault and Dadasault, the composer Debussy, and Fernandel.

For historical rigour, it should, however, be remembered that about one month before Dubost, in the United States N. Freeman (1903-1975) had unsuccessfully treated an abdominal aneurysm using an autologous common iliac vein and that 27 days earlier Schafer had operated on an abdominal aneurysm using a homograft, maintaining the distal aortic perfusion with a polyethylene tube during the clamping.

The pillars of Hercules had finally been crossed: as often occurs in sport, a new record is followed by immediate attempts to equal it – not only out of emulation but also because of the awareness that it is possible. Indeed, in a short period the operation was repeated by Julian (25<sup>th</sup> October, 1952), Brock (5<sup>th</sup> November, 1952), DeBakey (6<sup>th</sup> November, 1952) and Bahnson (14<sup>th</sup> February, 1953). A retroperitoneal access was used, except by DeBakey, who first used the transperitoneal approach.[39,40,41,42,43,44]

Anaesthetic, reanimation and cardiologic supports were still limited and Dubost himself considered that the indication for aneurysmectomy should be limited to "*easy cases*": "*Re-section remains a major intervention and carries with it important risks. It should only be undertaken in the case of a relatively young patient, in good cardiovascular condition, able to support a long intervention, with perhaps considerable haemorrhage. Very large aneurysms, vertebral erosions and above all signs of fissuration appear to us to be contraindications.*"

Dubost's belief was, however, soon to be shown to be false; almost immediately the first operations of ruptured aneurysms were performed by Bahnson (13<sup>th</sup> March, 1953), Gerbode (24<sup>th</sup> March, 1954), Cooley (26<sup>th</sup> April, 1954) and Javid (21<sup>st</sup> December, 1954).[45,46,47,48]

Meanwhile, in the context of obstructive stenotic lesions, homografting was accompanied by endarterectomy, devised by the Portuguese surgeon Joao Cid Dos Santos (1907-1975), son of Reynaldo, the originator of aortography. Dos Santos started his training at Strasbourg under Leriche where, together with his friend Kunlin (1904-1991), he conceived the method. On the 27<sup>th</sup> August, 1946 he performed the first endarterectomy, of the left iliac-femoral axis in a 66-year old patient, using an old silver ophthalmic spatula.

The technique spread: E. Bazy in Francia, E.J. Wylie (1918-1982) in the United States and J. Vollmar (1923-2008) in Germany, became the standard-bearers of aortic thrombo-endarterectomy.[49] The method, albeit with alternating fortune, found its supporters, but its use in aortic surgery waned and it remained indicated only for selected cases.

While aneurysms were no longer held in awe and the surgical techniques were becoming consolidated, the problem remained the homografts. The difficulties in obtaining such grafts and the emerging understanding that they could degenerate undermined their use.[50]

The search for a substitute for homografts started and it was a young American of Dutch origin, Arthur Bostwick Voorhees (1921-1992), who first broke the ground. Voorhees was born in Moorestown and, in 1946, joined A.H. Blakemore's group at Columbia Presbyterian Hospital in New York. Blakemore sensed the young man's capacities and directed him towards research. As Voorhees himself was to say: "*Dr. Blakemore encouraged and supported my flight of medical and surgical fantasy*".[Fig. 12]

Voorhees reached the winning post through serendipity: in 1947 he started animal experiments on mitral valve replacement using a homologous inferior vena cava valve. The implantation technique required the preparation of new, artificial chordae tendineae in silk. In the spring of 1948, during an examination of the heart of one of the sacrificed animals, he observed one of the silk threads of the chordae tendineae floating in the ventricular chamber, colonised and covered by a material that macroscopically resembled endocardium. He immediately had an intuition: "*As an outgrowth of this observation it was conceived that if an arterial defect were bridged by a prostheses constructed of a fine mesh cloth, leakage of blood through the wall of the prosthesis would be terminated by the formation of fibrin plugs and would thus allow the cloth tube to conduct arterial flow.*" [51] The search for an alloplastic vascular substitute that could be endothelialised was started immediately.

Meanwhile, in 1948 Voorhees, was assigned to Brooke Army Medical Center in San Diego, Texas to work on a project on plasma expanders; he did not abandon his earlier research and experimented with tubes made of nylon from the parachutes at the air base. Once back with Blakemore, he met J.W. Blunt, a young orthopaedic surgeon who was working on synthetic tendons and had a reasonable knowledge of plastic fibres. Voorhees described the characteristics of the ideal material to him: "*The cloth must be strong, inert, stable, of the right porosity, supple, and yet easily traversed by a fine needle*".

Blunt suggested Vinyon-N, produced by The Union Carbon and Carbide Corp. for spin-



makers; the company gave him some 144x90 sheets of the material and Voorhees started his research, supported by a new resident, A. Jaretzki. The results in the sacrificed animals were better than hoped: even some time after the implant, the graft remained patent and microscopic examination of the endoluminal surface revealed *"multiple layers of flattened cells and collagen fibres strikingly similar to the architecture of the normal aorta with notable absence of elastic and smooth muscle elements"*.

The findings were reported at the Congress of the Society for Cardiovascular Surgery at New York in 1952.[52] There was, however, no experience in humans. A few months later a 68-year old patient with a ruptured abdominal aneurysm was admitted as an emergency to Columbia Hospital, when Blakemore was the surgeon; having clamped the aorta, he was informed that an aortic homograft was not available (!!!?). Voorhees promptly left the operating theatre and prepared a Vinyon-N graft which, once sterilised, was implanted. When the aorta was unclamped, the graft was found to be functional, but the patient died 30 minutes later of a myocardial infarct; the post-mortem showed that the graft was permeable. For the following cases it was still Voorhees himself who manually prepared the grafts using an Italian sewing machine belonging to his wife, Margareth; the machine was a fixed item in the operating theatre and the staff called it *"Mag's Necchi"*. The first results of a series of 17 cases were reported, with a peri-operative mortality rate of 8%.[53]

Voorhees' fertile mind was exploited in other research activities of the group: the probe for tamping oesophageal varices, hepatic regeneration, the dynamics of portal hypertension and the potential use of laser in vascular treatment. Affected by severe respiratory failure, he had to retire at the age of 61 and died in 1992 of lung cancer.

Vinyon-N had various defects and industry, showing clear interest, proposed other fibres with more favourable physical characteristics: orlon, teflon, nylon and dacron. Encouraged by industry and swayed by personal preferences, the surgeons used the various different materials proposed and results of the first series were reported. The prostheses were quickly shown to be superior to homografts and became the decisive factor in the adolescence of aortic surgery.

In 1955 Edwards developed, together with J. Tapp, a chemist from Chemstrand Corporation, the concept of crimping, while DeBakey in collaboration with T. Edmann, an engineer from Philadelphia College Textile and Science, devised a machine able to weave a bifurcated prosthesis in Dacron. L. Sauvage, Deterling, Julian, Shumacker, Szilagyi, Haimovici and Wesolowski went on to make various modifications to the porosity and type of weft of the material.[54,55]

Meanwhile, in the context of stenotic occlusive lesions, in 1955 a British surgeon, F. Cockett, performed the first aorto-bifemoral by-pass.[55]

A report from the Committee for Study of Vascular Prostheses in 1956 concluded: *"Dacron and teflon were the most satisfactory materials for use at that time, because Vinyon-N was no longer commercially available and because both nylon and Orlon exhibited significant loss of tensile strength over time"*.[56]

The use of prostheses in aortic surgery became almost universal; however, the choices

Fig 10



Fig 11

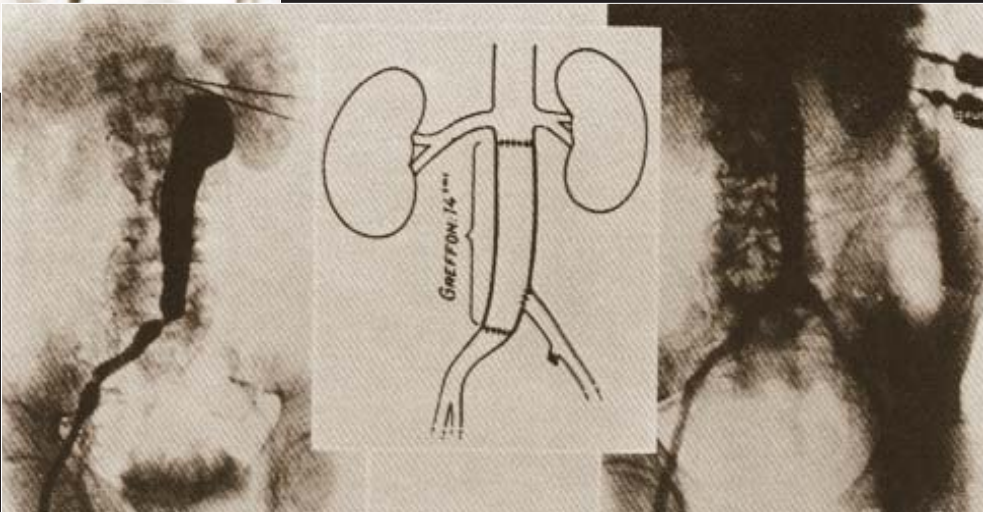


Fig 12



Fig 10  
Left to right:  
H. Bahnson, C. Dubost,  
F. M. de Gaudard d'Allaines.

Fig 11  
Pre and post operative  
angiography  
*"Dubost's operation"*.

Fig 12  
A. B. Voorhees.

were not always dictated by scientific and/or clinical evidence. Deterling's comment on the subject was interesting: *"It seemed almost heretical that the introduction of cloth as a vascular replacement allowed people with practically no background in the field to go to Macy's and ask a clerk, what's the best thing for an aorta?"*. [57]

Aortic surgery, thanks also to diagnostic, anaesthetic and pharmacological advances, was entering its adulthood. In 1953 extracorporeal surgery was introduced into clinical practice by J. Gibbon, who used it in the treatment of an interatrial defect.

This was start of golden age; from the old continent of Europe, the cradle of aortic surgery with Leriche, Oudot and Dubost, the axis shifted notably to the United States, in particular to Houston in Texas. Houston, with it two charismatic surgeons – DeBakey and Cooley, was, for a long time, to be the Mecca of surgery.

M.E. DeBakey (1908-2008) was born at Lake Charles; his grandparents, Dabaghy, were Maronite Lebanese immigrants whose surname became Americanised. DeBakey gained his first surgical experience in Europe, first under Leriche at Strasbourg and then with Kirschner at Heidelberg. He returned to the United States to work with Alton Oschner. During the Second World War he was actively employed as a surgeon: the period was stimulating for DeBakey, who was already showing his intuitive and organizational talents. He was among the protagonists of the creation of the earliest front-line surgical support units, the precursors of the mobile army surgical hospitals (MASH) in the Korean war. His training in vascular surgery enabled him to study vascular battle injuries and his work with Simeone was to become a classic. [58] [Fig. 13]

He arrived at Baylor University at Houston in 1948 where, together with D. Cooley, he was to achieve various world firsts in the field of cardiac and vascular surgery. The marriage of these two minds was to be a lodestar for the whole of cardiovascular surgery. D. Cooley (1920) is a Texan who learned the rudiments of surgery from Brock in London, then trained under Blalock at Baltimore and finally at Houston. The union that developed between these two great surgeons was to give rise to innovative and fundamental aspects for all vascular surgery.

DeBakey was technical and organizational whirlwind and a perfectionist to the point of pedantry. He could not bear people who did not understand things immediately and also hated people who spoke softly. It is a natural fact that first fiddles do not accept their equals and, furthermore, with time the difference in age between the two became less important. In 1953, the union with Cooley began to show flaws and, soon after, their ways separated. The definitive and explosive break, however, came in 1969 as a result of a fight (with legal consequences and all the tone of a spy-story) over the primogeniture of the artificial heart. [Fig. 14]

DeBakey, besides having a fervid imagination, was a technically perfect surgeon; world-famous people from all spheres came to him for their operations. The Duke of Windsor had a abdominal aortic aneurysm which, although small, had a bulky blister; DeBakey said that surgery was indicated and carried out the operation. Since then, this type of aneurysm has been called "Duke's size". [Fig. 15]

The semiological palpatory manoeuvre (forgotten by many students with the arrival of

echoDoppler investigations) in the epigastrium in the differential diagnosis between a pararenal and a subrenal aneurysm carries his name: DeBakey's sign.

Old age brings wisdom: finally, on the 7<sup>th</sup> November 2007, Cooley, then 87 years old, and DeBakey, 99 years old, shook hands again.

At the age of 97, DeBakey had found himself on the other side of the fence, with a dissecting aneurysm of the thoracic aorta. The operation necessary was certainly one at high risk and, furthermore, DeBakey had left a letter in which he refused *a priori* any attempt at reanimation should he be in a coma. His disciples therefore asked for advice from the Ethical Committee which (as usually occurs when such a Committee is asked to give a yes or no answer) did not know what to suggest. DeBakey's condition worsened and his pupils decided to do what their master had taught them: they operated. The intervention, carried out by G. Noon, was successful and DeBakey was to die at the age of 99 years old.

Numerous surgeons, not only Americans, were raised in the Texan school and were to leave their mark on aortic surgery; E.S. Crawford (1922-1992) is just one example.

By now aortic surgery was entering adulthood and flourishing throughout Europe as well: it became the pride of the emerging groups of vascular surgeons, still working within the setting of general surgery; subsequently in some countries, at different times and in different ways, vascular surgery was to cut the umbilical cord linking it to general surgery.

In Italy the first cases of aortic surgery were performed in the mid-1960s by Malan at Milan, Cevese at Padua, Stefanini at Rome and Zannini at Naples.

E. Malan (1910-1978) gave charisma to the new discipline; initially a pupil of A. Dogliotti (1877-1965) at Turin, he then moved to Parma, Genoa and, finally, to Milan, where he worked in the Zonda building of the Polyclinic; for some years "the Zonda" was synonymous with vascular surgery and various important groups developed there, including the one of U. Ruberti. Its name has also been passed down to us by Hemingway in "Farewell to arms": the structure, built thanks to a gift from the brothers Enrico and Emilio Zonda and inaugurated in May 1915, received the wounded during the First World War, including Hemingway in 1917. In 1969 Malan carried out the first Italian kidney transplant. He understood the importance of the scientific autonomy of the new discipline and in 1967 was among the promoters and founders of the Italian Society of Cardiac and Vascular Surgery along with Cevese, DeBlasi, Donatelli, Lanzara, Provenzale, Scirè, Venturini, Valdoni and Zannini. [Fig. 16, 17]

He was able to look ahead and in 1973, in a surprisingly topical manner, promoted, together with Mantegazza, Rector of the State University of Milan, the Italo-Chinese Medical Association. Furthermore, he understood the future of transplants and their related complications; in 1976, together with Confortini and Sirchia, he organized the NIT (Nord Italian Transplant).

Affected by stenotic failure of a bicuspid aortic valve he was forced to undergo a valve replacement in 1978; he asked his friend DeBakey at Houston to operate, where he unfortunately died peri-operatively.

The intuitions of these various Masters gave fruit; very soon aortic surgery was differentiated according to the different pathologies (aneurysmal, obstructive stenotic, dissecting) and sites: abdominal aorta, thoracic aorta (arch and descending), thoraco-abdominal. The



techniques improved and the indications expanded, in particular thanks to the refinements of the materials used and anaesthetic, reanimation and cardiologic expertise.

When the evolution of aortic surgery seemed to have been completed and it had reached complete maturity if not senility, a new scenario was opened: endovascular techniques. The ‘restyling’ of aortic surgery was profound and it offered a new image of itself.

ABDOMINAL AORTA

Until the end of the 1960s, the standard technique for surgery of aneurysms was that devised by Dubost with complete resection of the aneurysmal sac and the use of a prosthetic graft. However, in 1966 O. Creech, in DeBakey's group, simplified the technique and made it safer. Using a combination of the technique introduced by Matas (endoaneurysmorrhaphy) and that employed by Dubost, he placed the graft inside the sac without then resecting the aneurysm.[59] The technique was to be adopted universally.

In the years following DeBakey's seminal operation in 1952, the most commonly used route of access was transperitoneal; in 1963, C. Rob, a British surgeon, returned to the original technique, exalting the retroperitoneal access, given the less exacting post-operative recovery.[60] This access was to be modified in 1980 by Williams, from Baltimore, with the mobilisation of the left kidney in cases of pararenal or suprarenal aneurysms.[61]

The problem of patients at risk in the 1960s was still causing trouble; in the context of less invasive procedures, Sir Cooper's attempt of a century earlier was reconsidered. In 1965 Blaidell proposed ligation distal to the common iliac arteries combined with axillo-bifemoral bypass. The technique, labelled as “*non-resective therapy*”, was based on the hope of thrombosis of the sac; further experiments were to be conducted in the 1980s but again with very disappointing results as most of them ruptured.[62]

In the middle of the 1960s reports of the first continuous series appeared: DeBakey reported a peri-operative mortality rate of 9% among 1449 patients operated electively. The European series were smaller; a combined series from St. Mary's Hospital in London and the University Clinic at Heidelberg was limited to 61 patients between 1950 and 1959. The multicentre French study from 1960 to 1967 included 203 cases.[63,64,65] In an American review of cases treated between 1952 and 1969 the mortality rate was 16.1% among 653 cases of elective surgery and 54.4% among the 824 ruptured cases.[66]

By the 1980s the operation had become routine in specialised centres, with a clear improvement in results: the mortality rate associated with elective surgery did not exceed 5%.

At the end of the 1980s, the relevant co-morbidities were clearly identified: the presence of one or more risk factors increased the mortality-morbidity rate by 15%. For the first time other factors influencing the outcome were analysed: the surgeon's experience, the number of cases treated annually in the centre, the quality of post-operative care.

At the end of the XX century the mortality-morbidity rate of elective surgery was not

Fig 13



Fig 13  
M.E. DeBakey and J. Kunlin  
in Strasbourg: photograph  
with dedication.



Fig 14  
M.E. DeBakey and D. Cooley.

Fig 14



Fig 15

Fig 15  
Left to right: Wally Simpson,  
the Duke of Windsor and  
M. E. DeBakey in Houston.

greatly different from that in the 1980s; however, in these 20 years the indication for surgery had been extended to many patients previously considered inoperable.[67]

In contrast, in cases of rupture, although the mortality rate remains high, the meta-analyses provide reason for more optimism: from 1954 to the present, there has been a constant reduction of 3.5% per decade, for an estimate of 41% in 2000.[68]

In the 1990s, aortic surgery also joined the bandwagon of less invasive surgery: in 1993 the Canadian Y.M. Dion first performed aortic surgery via laparoscopy.[69] This was followed, at the beginning of 2000, by the first clinical experience with robotic aortic surgery.[70]

Endovascular treatment appeared on the scene.

Following the intuitions of C. Dotter (1920-1985) endovascular treatment had already been used in other settings and became indicated also for aortic pathologies; the acronym EVAR (endovascular aneurysm repair) was applied to its usage for aortic aneurysms.

It should be said immediately that it was a Russian, N. Volodos (1935) from Karkov, who pioneered its clinical usage in the aorta. In 1985 Volodos positioned an endograft in an iliac percutaneous transluminal angioplasty and in the same year used endografting to treat a post-traumatic aneurysm of the descending aorta (the patient was to live for 17 years). Both operations were reported in a Russian journal in 1986 but were made known in the Anglo-Saxon literature only in 1991. Thus Volodos was the first surgeon to translate the concept of aortic endografting into practice.[71,72] [Fig. 18]

On the 6th September, 1990 J. Parodi (1942), a surgeon from Buenos Aires, used EVAR to treat H. Coira, a 75-year old patient with considerable co-morbid problems that prohibited the use of open surgery. The endoprosthesis used was a straight Dacron graft and the caudal stent landed proximally in the bifurcation without involving the iliac vessels. Parodi had been experimenting his idea for about ten years in animals; in the construction of the endoprosthesis he was helped by Sommers, an Argentinean war company producing materials for missiles, for the stents and for the body of the prosthesis by H. Barone an Argentinean industrialist. In the same year Parodi treated another patient, but was forced to convert the operation into open surgery.[73]

On the 23<sup>rd</sup> November, 1992 Parodi carried out the first EVAR in the United States in Veith's Service at New York; he was assisted by an Argentinean radiologist, Schonholz, by Barone, and by Veith and Cynamon themselves. The expenses for the three Argentines' journey and stay in New York were covered by the Hilton Foundation, at the request of Veith. The prosthesis was assembled by Barone and the stents by Sommers Argentina, after complicated negotiations with Johnson & Johnson. Veith had, in fact, asked Johnson & Johnson for their wide bore Palmaz stents, which were suitable for the endoprosthesis but required urgent approval from the FDA and Johnson & Johnson feared that this could have a negative effect on the imminent approval of its Palmaz coronary artery stents.[Fig. 19]

The first American EVAR was followed immediately by both favourable comments and criticisms; the remarks of J. Bergan are significant: *"Dr. Parodi and his colleagues have simplified aortic surgery. Thus their work is truly artistic as well as scientific."*

Parodi continued his clinical experience and, in 1995, reported the results of the first

series of 50 cases; in the presence of an iliac aneurysm he used a straight aorto-iliac endoprosthesis with occlusion of the aneurysmal iliac artery and cross-over.

It is, however, rare that aneurysmal disease affects only one segment of the aorta and/or only one iliac vessel: it soon became clear that only 10% of aortic aneurysms were suitable for EVAR treatment with a straight endoprosthesis. A bifurcated endograft, first implanted in October 1993 by T.A.M. Chuter, was therefore designed.[74]

Industry's interest in EVAR was marked: efforts were made to translate every idea into clinical practice, but some solutions were found to be not feasible or remained in the stage of experimental studies. One part of the surgical world held back and watched, sometimes bewildered by the pressure of proposals from industry. Indeed, from an initial, very superficial position that a easy solution was available for everyone and applicable to all aortic aneurysms, it quickly became clear that the method was profoundly influenced by the morphology and characteristics of the lesion of the aneurysmal mass. Furthermore, an initially overlooked medico-legal aspect emerged; the use of this method was conditional on the possibility of immediate conversion to open surgery and could, therefore, only be performed in centres with such experience.

Although the systems were at that time still rather large, industry managed to miniaturise them; second-generation endoprostheses began to appear. EVAR became a routine treatment: in 2002 alone, 17,000 endografts were implanted in the USA and 14,000 in Europe.[75]

The first avoidable complications also began to emerge: most were related to the lack of experience of the surgical team and poor selection of the patients. Other elements for an optimal learning curve and factors affecting the outcome of EVAR were clearly identified: the necessary number and frequency of the procedures performed were defined as a minimum of 55 cases per year with a frequency of at least one procedure every ten days.[76]

Endoleak seemed to be the immediate and long-term Achilles' heel of EVAR: in 1997 White codified and classified endoleaks in relation to aetiology and topography.[77] In 1999, G. Gilling-Smith, a British surgeon, studied the state of persistent pressure within the sac after EVAR; he gave this the name of "endotension" and classified three levels.[78]

In order to counteract type I endoleaks, an Australian group devised and developed an endograft with a suprarenal stent [79] and, in 2001, went further, with the first clinical applications of fenestrated endoprostheses incorporating the renal orifices and the superior mesenteric artery.[80]

By now EVAR had gained clinical acceptance and some of its initially nebulous indications had been well codified. The results of the first comparative studies against open treatment, prospective studies and randomised trials began to appear: among all these various studies, the multicentre, European EUROSTAR study on 3.075 patients, EVAR in England, DREAM in The Netherlands, ACE in France and OVER in the USA are worth particular note.

The method was even extended to the treatment of ruptured aneurysms in some pilot centres, Montefiore at New York, Nottingham, Ulm, Zurich, Eindhoven, where its feasibility was demonstrated, albeit conditional on full availability of the technology and experience of the centre: *"...a ruptured AAA endovascular service requires a great deal of organization and is only likely to be possible at major vascular centres"*. [81]



THORACIC AORTA

Following the earliest anecdotal case reports of thoracic aortic surgery by Alexander in 1944 and Craaford in 1945, it was DeBakey who carried out the first radical treatment of a thoracic aneurysm in 1953.[27,28,82]

This was the start of a period of surgery that was undoubtedly more stimulating than that of abdominal aortic surgery: the problems were more numerous and the successive techniques more varied. Indeed, the variety of techniques was also a reflection of the different features of each of the districts of the thoracic aorta, each with its particular and different problems; the repercussions of clamping on the brain, intercostal region, viscera and kidneys constitute just one example. This was a less well understood field and led to a discovery that from the middle of the 1950s was to be of continuous relevance. The problems related to this type of surgery also necessitated the availability of better means and greater experience, making this a sort of elite surgery for many years.

In his operation, DeBakey used a Dacron graft to treat an aneurysm of the descending aorta; the clamps were in place for 45 minutes without any spinal or visceral protection. Describing the operation to V. Bjork, DeBakey was later to say: *“we didn’t know at the time that you ran the risk of spinal cord ischaemia, you see. We found that out later.”*

The group working at Houston began to become the reference pole for thoracic aortic surgery; once again it was DeBakey who, in 1961, classified aortic dissections into four types depending on their extent and site and then, in 1963, made the first classification of thoracic aneurysms, again into four types.[3,4]

In 1956, the Houston group was also the first to treat an aneurysm of the ascending aorta and then, the following year, an aneurysm of the ascending aorta and aortic arch.[83, 84]

In the former case a homograft with implantation of the brachiocephalic and left common carotid arteries was used, while in the latter a Dacron graft was employed with a temporary Ivalon shunt between the ascending and descending aorta with side branches to the carotid vessels and implantation of the supra-aortic branches.

In 1962 DeBakey published the results of a first series of 52 cases of aneurysms of the aortic arch, reporting a perioperative mortality rate of 42%.

In cases of valvular involvement, the aortic arch and valve were managed separately; the technique was, however, simplified in 1968 by Bentall who introduced a valved tube.[3]

At the beginning of the 1970s two other classifications of dissecting aneurysms were made: the Stanford classification into types A and B depending on the dissecting segment and Dubost’s classification into four groups based on the topography of the initial intimal lesion.[4]

It was in surgery of the descending thoracic artery that the need to protect the spinal cord, kidneys, heart and viscera was becoming particularly obvious. Various proposals were made.

Adams, in 1955, was the first surgeon to try to resolve the problem and he did so in an ingenious manner by using a homograft between the ascending and descending aorta dur-



Fig 16



Fig 17

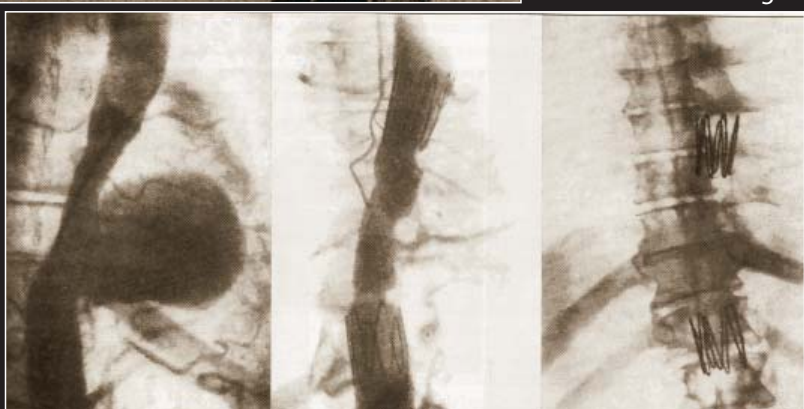


Fig 18



Fig 19

Fig 16  
Left to right:  
J. C. Dos Santos,  
M. E. DeBakey,  
A. M. Dogliotti,  
C. G. Cotta,  
E. Malan.

Fig 17  
Right to left:  
U. Ruberti and his pupil  
A. Otero.

Fig 18  
TEVAR by N. Volodos  
in 1985.

Fig 19  
J. C. Parodi.

ing the treatment of an aneurysm of the descending aorta; the homograft acted as an external shunt and remained as the new aortic channel after resection of the aneurysm.[85]

Moderate hypothermia was introduced and, in April 1953, Hardin used surface hypothermia during the treatment of a thoracic aortic aneurysm with a homograft.[86]

In 1957, F. Gerbode devised a form of extracorporeal circulation, activated by a roller pump, between the left atrium and a femoral vessel; this was baptised ‘left heart bypass’ and was used in the treatment of a post-traumatic aneurysm.[87]

In 1963, V. Gott had the idea of using a heparin-treated polyvinyl shunt with a diameter of 9 mm, with branches for the TSA, from the ascending aorta to the descending aorta; the system was simple, but its use was not free of risks, particularly those related to embolism and dissection.[88]

In 1970 Dixon introduced the Bio Medicus pump, a left heart bypass system powered by a centrifugal pump with a heat exchanger with derivations for the selective perfusion of visceral and renal branches.[89]

In 1973 E.S. Crawford simplified DeBakey's technique from 1958 for the treatment of thoraco-abdominal aneurysms. The principle of the technique has since remained essentially unchanged: the graft anastomosed proximally T-T within the sac is anastomosed L-T with the endoluminal intercostal, visceral and renal orifices. Sequential clamping in a caudal direction enables perfusion of the vessels at completion of each anastomosis, thus decreasing the periods of ischaemia. Crawford described his initial experience with 84 cases of which 38 were treated with an external shunt and 46 with a shunt: the survival rate was 91% in cases without a shunt and 75% in the group in which a shunt was used. The incidence of paraplegia was lower in the group treated without a shunt.[90]

It was also Crawford who, in 1991, one year before his death, introduced a new classification of thoraco-abdominal aneurysms into four types according to their extension and topography.[91]

Spinal cord ischaemia remained the most feared complication of this surgery. The proposed monitoring systems included Crawford's suggested use of somatosensory evoked potentials (SSEPs) and motor evoked potentials (MEPs) in 1988 and cerebrospinal fluid drainage as protection. Such drainage was first used clinically by the Japanese Miyamoto in 1960; given its simplicity and reliability, cerebrospinal fluid drainage was to become one of the most widely used systems.[92]

As regards dissections, the treatment of choice remained replacement with a graft and gluing of the walls with gelatine resorcin formalin glue. In 1979 A. Carpentier, from Dubost's group, suggested a ventral aortic prosthesis originating from the ascending aorta and anastomosed distally to the abdominal aorta with an extra-anatomic tract. This idea was, in fact, not new, having been proposed about twenty years earlier by Shumaker.[4]

In 1999 Svensson, one of Crawford's pupils, proposed a new classification of dissections of the aortic arch into five classes based on the topography and different involvement of the layers of the vessel's walls, while in 2000, the French surgeon E. Kieffer, a pupil of Natali, proposed another classification of aneurysms of the descending thoracic aorta.[4,93]

Once again it was the group from Houston that pioneered treatment of aneurysmal disorders extending throughout the aorta. In 1975 Nef reported the first case of extensive replacement of the arch, thoracic aorta and the whole abdominal tract; after about ten years Crawford reported on 32 cases, while the German, H.G. Borst devised a technique allowing the treatment to be carried out in two

phases: during the replacement of the arch with implantation of the TSA, the distal segment of the prosthesis was left floating in the descending aorta and was used in a second, later operation for the treatment of the downstream segment of the aorta. The free segment in the aorta resembled a proboscis and Borst baptised it the “elephant's trunk”.[94]

The potential of endovascular treatment was applied to the thoracic aorta; it was M.D. Dake from the group at Stanford who first treated, in 1992, an aneurysm of the thoracic aorta with an endoprosthesis.[95]

The first steps were taken, particularly in cases of post-traumatic aneurysms which are not infrequent in this context. In 1996, M. Kato carried out the first hybrid repair: in an aneurysm of the third segment of the arch including the left subclavian, he excluded, with an antegrade stent graft, an aneurysm in the distal part of the arch and anastomosed the proximal aortic stump, next to the origin of the left common carotid artery, to the stent graft.[96]

The subsequent modification was simple and efficient: retrograde endografting of the aneurysm and in cases, not tolerated, of covering the left subclavian or left common carotid, extra-thoracic bypasses (carotid subclavian, carotid – retro-oesophageal carotid) or subclavian and carotid implants (almost completely abandoned with the advent of endovascular surgery) were brought back into use.

Meanwhile, five landing zones for safe anchorage of the endograft were identified in the arch.

Thoracic aortic surgery had received a new lease of life: many previously untreatable thoracic conditions became manageable with endovascular treatment.

## CONCLUSIONS

And so I have reached the present. The future of aortic surgery remains unknown, but some predictions can be made. This has been only an excursus, but I beg forgiveness with the help of Georges Duhamel (1884-1966): *“Ainsi que tous les gens sérieux, je ne crois pas à la vérité historique mais je crois à la vérité légendaire”*.



1. Kuhn T. The structure of scientific revolution. University of Chicago Press. 1962

2. Argenteri A, DeAmicis P, Curci R. Aneurismi toraco addominali. Un percorso storico. G Ital Chir Vasc 2002;9:1-46

3. Argenteri A, Odero A Jr, Bianchi G. Patologia dell’aorta toracica: le radici. In: Patologia dell’Aorta Toracica. Ed. Pratesi C, Pulli R. Minerva Medica 2005:21-31

4. Argenteri A, Odero A Jr, Bianchi G. Gli aneurismi disseccanti: appunti storici. In: Aortic Surgery “How to do it”. Ed. Chiesa R, Melissano G. HSR 2004: 1-11

5. Argenteri A, Corbetta R, Arici V. La storia della diagnostica vascolare. In: Il Monitoraggio in Chirurgia Vascolare. Ed. Pedrini L. Alfa Wassermann 2000: 21-43

6. Argenteri A, Medicine through time. In: Aortic Surgery “How to do it” II. Ed. Chiesa R, Melissano G, Alfieri O. HSR 2006: 120-132

7. Carrel A. Au sujet de la conservation des arteres en cold storage. Comp Rendu Soc Biol1907;62:1178-84

8. Carrel A. La technique des anastomoses vasculaires. Lyon Med 1902; 98:859-64

9. Carrel A, Guthrie CC. Uniterminal and biterminal venous transplantations. Surg Gynecol Obst1906;2-266

10. Carrel A. Resultats eloignés des trasplantation des veines sur les arteres. Rev Chir 1910;XVL: 987-94

11. Carrel A. Experimental surgery of the thoracic aorta by the method of Meltzer and Bauer. JAMA 1910;54:28-9

12. Carrel A. Experimental operations on the orifices of the heart. Ann Surg 1914;60: 1-8

13. Carrel A. Graft of the vena cava on the abdominal aorta. Ann Surg 1910;52:642-9

14. Carrel A. Latent life of arteries J Exp Med 1910;12:460-86

15. Carrel A. Results of the permanent intubation of the thoracic aorta. Surg Obst Gynecol 1912;15:245-8

16. Argenteri A, Curci R. Alexis Carrel. Vascular Update 2000;4:7-14

17. Matas R. Ligation of the abdominal aorta. Ann Surg 1925;81:457

18. Matas R. Aneurysm of the abdominal aorta at its bifurcation into common iliac arteries. A pictorial supplement illustrating the history of Corinn D, previously reported as the first recorded instances of cure of an aneurysm of the abdominal aorta by ligation. Ann Surg 1940;112:909

19. Leriche R. Des obliterations hautes (obliterations de la terminaison de l’aorte) comme cause des insuffisances circulatoires des membres inferieurs. Bull Mem Soc Chir. December 1928

20. Leriche R, Morel A. The syndrome of thrombotic obliteration of the aortic bifurcation. Ann Surg 1948;127:193-8

21. Pearse HE. Experimental studies of the gradual occlusion of large arteries. Ann Surg 1940;112: 923-37

22. Abbot OA. Clinical experiences with the application of polythene cellophane upon aneurysm of the thoracic vessels. J Thorac Surg 1949;18:435-61

23. Poppe JK, De Olvera HR. Treatment of syphilitic aneurysm by cellophane wrapping. J Thorac Cardiovasc Surg 1946;15:185-95

24. Blakemore AH, King BG. Electrothermic coagulation of aortic aneurysms. JAMA 1938;111:1821-7

25. Blakemore AH, Voorhees AB. Aneurysm of the aorta. Review of 365 cases. Angiology 1954; 5: 209–31

26. Bigger IA. The surgical treatment of aneurysm of the abdominal aorta. Review of the literature. Ann Surg 1940;112: 879

27. AlexanderJ, Byron FX. Aortectomy for thoracic aneurysm. JAMA 1944,126:1139- 45

28. Craaford C, Nylin G. Congenital coartaction of the aorta and surgical treatment. J Thorac Surg 1945;14:347-61

29. Natali J. Hommage à Jacques Oudot pour le 50e de la première greffe de la bifurcation aortique. Chirurgie 1999;124:488-54

30. Natali J. Chirurgie de la bifurcation aortique. Etude experimentale et clinique. These Paris 1952

31. Oudot J. La greffe vasculaire dans les thomboses du carrefour aortique. Presse Med 1951; 59:234-6

32. DeBakey ME. Les greffes d’aorte. 56me Congres Francais de Chirurgie. Presse Univ France 1954:264-6

33. Cockett FB. Obliteration du carrefour aortique (syndrome de Leriche) Minerva Cardioangiolo 1957;5:143-7

34. Rob C. Obliterations of the aortic bifurcation. Surgical treatment. Minerva Cardioangiolo 1957;5:110-6

35. Oudot J. Observations physiologiques et cliniques en haute montagne. Presse Med 1951;59:297-300

36. Cooley D. Early development of surgical treatment for aortic aneurysms: personal recollections. Texas Heart Inst J 2001;28:197-9

37. Dubost C, Allary M, Oeconomos N. A’ propos du traitement des anevrysmes de l’aorte. Ablation de l’anevrisme. Retablissement de la continuité par greffe d’aorte humain conservée. Mem Acad Chir 1951;77: 381-3

38. Dubost Ch, Allary M, Oeconomos N. Resection of aneurysm of the abdominal aorta: reestablishment of the continuity by preserved human arterial graft, with results after five months. Arch Surg 1952; 64:405-8

39. Freeman NE, Leed FH. Vein inlay graft in the treatment of aneurysm and thrombosis of the abdominal aorta. Angiology 1951;2: 579-87

40. Schafer PW, Hardin CA. The use of temporary polythene shunts to permit occlusion, resection, and frozen homologous graft replacement of vital vessel segments; a laboratory and clinical study. Surgery 1952;31:186-99

41. Julian OC, Growe WJ, Dye WS, Olwin J, Sadove MS. Direct surgery of arteriosclerosis. Ann Surg 1953;138:387-403

42. Brock RC. Discussion on reconstructive arterial surgery. Proc R Soc Med 1953;46:115-30

43. DeBakey ME, Cooley DA. Surgical treatment of aneurysm of abdominal aorta by resection and restoration of continuity with homograft. Surg Obst Gynec 1953;97: 257-66

44. Bahnson HT. Considerations in the excision of aortic aneurysm. Ann Surg 1953; 138:377-86

45. Bahnson HT. Treatment of abdominal aneurysm by excision and replacement by homograft. Circulation 1954;9:494-503

46. Gerbode F. Ruptured aortic aneurysm a surgical emergency. Surg Gynec Obst 1954; 98: 579

47. Cooley DA, DeBakey ME. Ruptured aneurysm of abdominal aorta: excision and homograft replacement. Postgrad Med 1954;16:334-42

48. Javid H, Dye WS, Grove WJ, Julian OC. Resection of ruptured aneurysm of the abdominal aorta. Ann Surg 1955; 142: 613 - 23

49. Dos Santos JC. Leriche memorial pictures. From embolectomy to endarterectomy or the fall of a myth. J Cardiovasc Surg 1976; 17:113-28

50. DeBakey ME, Creech O Jr, Cooley DA, Halpert B. Structural changes in human aortic homograft. Arch Surg 1954; 69: 472-82

51. Voorhees AB. The origin of the permeable arterial prosthesis: a personal reminiscence. Surg Round 1988;2:79-84

52. Voorhees AB, Jaretzki A, Blakemore AH. The use of tubes constructed from Vinyon N cloth in bridging arterial defects: a preliminary report. Ann Surg 1952; 135:332-6

53. Blakemore AH, Voorhees AB. The use of tubes constructed from Vinyon N cloth in bridging arterial defects; experimental and clinical. Ann Surg 1954;140:324-34

54. Haimovici H. Ideal arterial graft. An unmet challenge – scope and limitations. Surgery 1982;92:117-9

55. Barker WF. Clio: the arteries. Austin 1992

56. Creech O, Deterling RA, Edwards S. Vascular prostheses: report of the committee for study of vascular prostheses of the Society for Vascular Surgery. Surgery 1957; 41:62- 80

57. Deterling RA. Commentary. In: Fundamentals of Vascular Grafting. Eds. Wesoloki SA, Dennis C. New York. McGraw Hill Book 1963: 365

58. DeBakey ME, Simeone F. Battle injuries of the arteries in World War II. An analysis of 2471 cases. Ann Surg 1946;123:534-42

59. Creech O. Endo aneurysmorrhaphy and treatment of aortic aneurysm. Ann Surg 1966; 164: 935-46

60. Rob C. Extraperitoneal approach to the abdominal aorta. Surgery 1963; 53:87-9

61. Williams GN, Ricotta J, Zinner M. The extended retroperitoneal approach for treatment of extensive atherosclerosis of the aorta and renal vessels. Surgery 1980; 88: 846-55

62. Blaisdell FW, Hall AD, Thomas AN. Ligation treatment of an abdominal aortic aneurysm. Am J Surg 1965; 109: 87-9

63. DeBakey ME, Crawford SE, Cooley D. Morris GC, Royster TS, Abbot WP. Aneurysm of abdominal aorta. Analysis of results of graft replacement therapy one to eleven years after operation. Ann Surg 1964;160:622-39

64. Rob CG, Vollmar JF. Die chirurgie der bauch-aorta. Ergebnisse Chir Orth 1959; 42: 569-54

65. Blondeau P. Chirurgie de l’aorte sous renale. J Chir (Paris) 1967;94:183-98

66. Gore I, Hirst AE Jr. Arteriosclerotic aneurysms of the abdominal aorta: a review. Prog Cardiovasc Dis 1973;16:113-50

67. Hallin A, Bergqvist D, Holmberg L. Literature review of surgical management of abdominal aortic surgery. Eur J Vasc Endovasc Surg 2002;22:197-204

68. Bown MJ, Sutton AJ, Bell PRF, Sayers RD. A meta analysis of 40 years of ruptured aneurysm repair. Br J Surg 2002; 89:714-30

69. Dion YM, Kathouda N, Roulaue C, Aucoin A. Laparoscopic assisted aortobifemoral by pass. Surg Laparosc Endosc1993;3:425-9

70. Wisselink W, Cuesta MA, Gracia C, Rauwerda JA. Robot assisted laparoscopic aortofemoral by pass for aorto iliac occlusive disease: a report two cases. J Vasc Surg 2002; 36:1079-82

71. Volodos N, Shekhanin VE, Karpovich IP, Troyan VI. A case of distant transfemoral endoprosthesis of the thoracic aorta using a self-fixing prosthesis in traumatic aneurysm. Grudn Khir [in Russian] 1988;6:84-6

72. Volodos N, Karpovich IP, Troyan VI, Kalashnikova YV, Shekhanin VE, Neoneta AS, Ustinov NI, Yaconenko LF. Clinical experience of the use of self-fixing synthetic prostheses for remote endoprosthetics of the thoracic and the abdominal aorta and iliac arteries through the femoral artery and as intraoperative endoprosthesis for aorta reconstruction. Vasa Suppl 1991;33:93-5

73. Parodi JC, Palmaz JC, Barone HD. Transfemoral intraluminal graft implantation for abdominal aortic aneurysm. Ann Vasc Surg 1991;5:491- 9

74. Chuter TAM, Green RM, Ouriel K, Fiore WM, DeWeese JA. Transfemoral endovascular aortic graft placement. J Vasc Surg 1993;18:185-7

75. Becquemin JP. Evar: new developments and extended applicability. Eur J Vasc Endovasc Surg 2004; 27: 453-5

76. Lobato AC, Rodriguez J, Dietrich EB. Learning curve for endovascular abdominal aortic aneurysm repair: evaluation of a 277-patient single center experience. J Endovasc Ther 2002;9:262-8

77. White GH, Yu W, May J, Charfour X, Stephen MS. Endoleak as a complication of endoluminal grafting of abdominal aortic aneurysm: classification, incidence, diagnosis and management. J Endovasc Surg 1997;4:152-68

78. Gilling Smith GL, Martin J, Sudhindran S, Gould DA, Mc Williams RG. Endotension after endovascular aneurysm repair: definition, classification, and strategies for surveillance and intervention. J Endovasc Surg 1999;6:305-7

79. Lawrence Brown MM, Hartley D, MacSweeney STR, Kelsy P, Ives FJ, Holden A, Gordon M, Goodman MA, Sieunarine K. The Perth HLB bifurcated endoluminal graft system – development and early experience. Cardiovasc Surg 1996; 4:706 –12

80. Anderson JL, Berce M, Hartley DE. Endoluminal aortic grafting with renal and superior mesenteric artery incorporating graft fenestration. J Endovasc Ther 2001; 8:3-15

81. Hinchliffe RJ, Braithwaite BD, Hopkinson BR. The endovascular management of ruptured abdominal aneurysm. Eur J Vasc Endovasc Surg 2003;25:191-201

82. DeBakey ME, Cooley DA. Successful resection of aneurysm of thoracic aorta and replacement by graft. JAMA 1953;152:673-6

83. Cooley DA, DeBakey ME. Resection of entire ascending aorta in fusiform aneurysm using cardiac by pass. JAMA 1956;162:1158-9

84. DeBakey ME, Crawford ES, Cooley DA, Morris GC. Successful resection of fusiform aneurysm of aortic arch with replacement by homograft. Surg Gynec Obst 1957;105:657-84

85. Adams H. Shunt graft with resection for aneurysm of the aortic arch. JAMA 1955; 159:1195-7

86. Hardin CA, Reismann KR, Dimond EG. The use of hypothermia in the resection and homologous graft replacement of the thoracic aorta. Ann Surg 1954;140:720-3

87. Gerbode F, Bambridge M, Osborn JJ, Baillot R, Dotigny L. Traumatic thoracic aneurysm. Treatment by resection and grafting with the use of an extracorporeal by pass. Surgery 1957;42:975-85

88. Gott VL, Whiffen SD, Dutton RC. Heparin bonding on colloidal graphite surfaces. Science 1963;142:1297-8

89. Dixon CM, Magovern GJ. Evaluation of the Bio Pump for long term cardiac support without heparinization. J Extracorp Technol 1982;14:331-6

90. Crawford ES, Rubio PA. Reappraisal of adjuncts to avoid ischemia in the treatment of aneurysms of descending thoracic aorta. J Thorac Cardiovasc Surg 1973;66:693-704

91. Crawford ES, Svensson LG, Kenneth RH, Shenaq SS, Coselli JS, Safi HJ. A prospective randomized study of cerebrospinal fluid drainage to prevent paraplegia after high risk surgery on the thoracoabdominal aorta. J Vasc Surg 1991;13:36-46

92. Miyamoto K, Ueno A, Wada T, Kimoto S. A new and simple method of preventing spinal cord damage following temporary occlusion of the thoracic aorta by drainage of the cerebrospinal fluid. J Cardiovasc Surg 1960;1:188-97

93. Kieffer E, Fukui S, Chiras J, Koskas F, Bahnini A, Cormier E. Spinal cord arteriography. A safe adjunct before descending and thoracoabdominal aortic aneurysmectomy. J Vasc Surg 2002;35:262-68

94. Borst HG, Walterbusch G, Schaps D. Extensive aortic replacement using elephant trunk prosthesis. Thorac Cardiovasc Surg 1983;13:37-40

95. Dake MD, Semba CP, Rubin CD, William DM, Miller DC. Endovascular stent graft treatment of thoracic aortic aneurysm. Radiology 1993;189:364

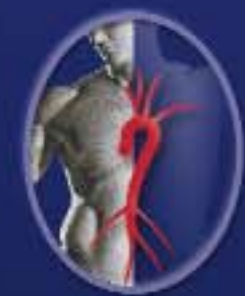96. Kato M, Ohnishi K, Kaneko M, Ueda T, Kishi D, Mizushima D, Matsuda H. New graft-implanting method for thoracic aortic aneurysm or dissection with a stented graft. Circulation 1996;94 (suppl. II): 188-93

224

AORTIC SURGERY AND ANESTHESIA “HOW TO DO IT” III

DECEMBER 2008

225



'08

The Chairmen of the International Congress Aortic Surgery and Anesthesia “How to do it” III gratefully acknowledge the following companies for their partnership.

ALBERTO ASPESI & C.
ARTI GRAFICHE COLOMBO
CENTRO COORDINAMENTO INTERCLUB
DIES GROUP
HULKA-VEA
MOMO DESIGN
NUMERO UNO MILANO
OLIO CARLI
ROCCA DI CASTAGNOLI
ROSSOCORSA
SAN CARLO Gruppo Alimentare
SIDI SPORT
TECHNOGYM

The Chairmen of the International Congress Aortic Surgery and Anesthesia “How to do it” III would like to thank the following companies for their generous and continuing support.

AB MEDICA	GLAXOSMITHKLINE
ABBOTT	GLORIA MED
ASTRAZENECA	INNOVATIVE MEDICAL TECHNOLOGIES
BAXTER	INVATEC
B. BRAUN	JOHNSON & JOHNSON MEDICAL
BIOTRONIK	JOTEC
BOEHRINGER-INGELHEIM	LEMAITRE
BOLTON MEDICAL	LUSOFARMACO
BOSTON SCIENTIFIC	MAQUET
CARDIOSERVICE	MEDTRONIC ITALIA
CEA	SANOFI-AVENTIS
CEPHALON	SEDA
COOK MEDICAL	SEROM MEDICAL TECHNOLOGY
CORDIS	S.I.D.EM.
COVIDIEN	SORIN GROUP
DATASCOPE	ST. JUDE MEDICAL
DISTREX	TELEFLEX MEDICAL - ARROW
EDWARDS LIFESCIENCES ITALIA	VASCUTEK, a TERUMO Company
ETHICON PRODUCTS	VYTECH HEALTH
EV3	W.L. GORE & ASSOCIATI