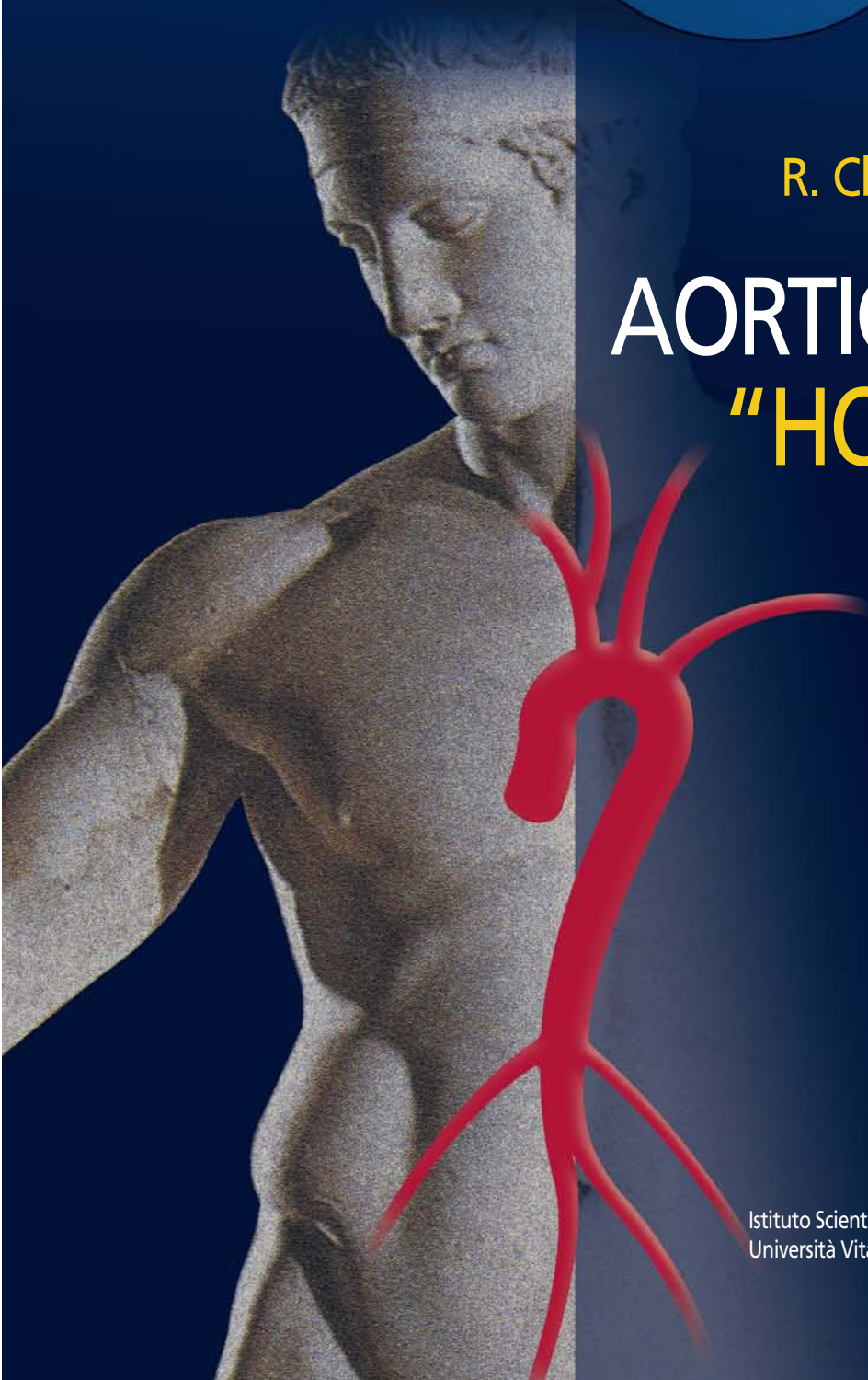


2006

R. Chiesa, G. Melissano, O. Alfieri

# AORTIC SURGERY "HOW TO DO IT" II



This book is dedicated to the many people afflicted with disease of the aorta, to those who had the courage to submit to the operations illustrated [...]

*"Diseases of the aorta"*  
*E. Stanley Crawford, M.D.*  
*John L. Crawford, M.D.*  
*Williams & Wilkins, 1984*



'06

Scientific Board

**Prof. Roberto Chiesa, Dr. Germano Melissano, Prof. Ottavio Alfieri**

*Vita-Salute San Raffaele University, Milano - Italy*

Graphic lay-out and art direction

**Antonio Fortarezza**

*Fortarezza & Harvey, Milano - Italy - info@fortarezza.it*

Artistic elaboration of the original pictures

**Dr. Fabio Massimo Calliari**

*San Raffaele Scientific Institute, Milano - Italy*

With the cooperation of

D. Astore, D. Baccellieri, L. Bertoglio, C. Brioschi, F.M. Calliari, C. Carone,  
A. Carozzo, G. Casiraghi, R. Castellano, B. Catenaccio, F. Cavenago, E. Civilini,  
D. De Dominicis, L. Dordoni, G. Esposito, R. Fiori, A. Kahlberg, D. Logaldo,  
S. Magrin, F. Maisano, P. Manzoni, E.M. Marone, M. Marrocco Trischitta,  
R. Mennella, M. Messina, J. Nzeпа Batonga, T. Quattrocchi, S. Segreti, F. Setacci,  
S. Spelta, L. Torracca, Y. Tshomba, A. Zangrillo  
*San Raffaele Scientific Institute, Milano - Italy*

Published and printed in Italy by

**Arti Grafiche Colombo s.r.l.**

ISBN 88-902063-4-9

First published - December 2006

**R. Chiesa, G. Melissano, O. Alfieri**

# AORTIC SURGERY "HOW TO DO IT" II

Some classic thinkers theorised that man's soul dwelt in the blood system rather than in the brain or heart, probably associating the notion of spirit with that of dynamism. We are aware that, while not taking up any space, our soul is present in every capillary of our body, and that without our soul, none of our thousands of genes could be considered alive.

Here there lies the innovation of our prof. Roberto Chiesa – innovation both in research and practice that, along with prof. Ottavio Alfieri, he has now brought to S. Raffaele with great and innovative therapeutic success. It is thus with the utmost satisfaction that I am now presenting this book by Roberto Chiesa, a “San Raffaele supporter from the very beginning”. This book has been edited in collaboration with prof. Ottavio Alfieri – another genuine San Raffaele supporter; a book into which the soul of such profound San Raffaele inspiration is transfused for a simple, learned reading: state-of-the-art techniques relying up innovative, non-invasive and fast methods.

We want people to live a long time, in perfect health, and that in their veins there flows, plentiful and rich, the blood of optimism, creativity and sacredness. Sacred, in fact, is man, sacred is his life, sacred is his blood. May nobody waste it! May nobody contaminate it! May all treat and love him, because in blood there resides the never-ending flow of love, of God's love; God himself, thus!

sac. prof. Luigi Maria Verzé

Qualche pensatore classico ha ritenuto che l'anima dell'uomo potesse avere sede nella circolazione sanguigna piuttosto che nel cervello o nel cuore, probabilmente perché associava il concetto di spirito con quello della dinamicità. Sappiamo che, pur non occupando spazi, l'anima è presente in ogni capillare del nostro soma e senz'anima neppure uno delle nostre migliaia di geni potrebbe considerarsi vivo.

Ecco la novità del nostro prof. Roberto Chiesa, la novità nella ricerca e nella prassi che, ora unitamente al prof. Ottavio Alfieri, ha portato nel S. Raffaele con grande e nuovo successo terapeutico.

È con grande soddisfazione, quindi, che presento questo volume di Roberto Chiesa, “Raffaeliano della prima ora”.

Un volume redatto in collaborazione con il prof. Ottavio Alfieri - altro Raffaeliano DOC - dove l'anima di così intimo sapore Raffaeliano, viene trasfusa per una lettura semplice e dotta: tecniche avanzatissime con metodiche innovanti, minimamente invasive e veloci.

Vogliamo che gli uomini vivano a lungo ed in salute perfetta e che in loro scorra frequente e turgido il sangue dell'ottimismo, dell'amore, della creatività e della sacertà.

Sacro, infatti, è l'uomo, sacra la sua vita, sacro il suo sangue.

Nessuno lo sprechi! Nessuno lo inquinì!

Tutti lo curino e lo amino perché nel sangue c'è flusso perenne d'amore, l'amore di Dio; Dio, quindi!

sac. prof. Luigi Maria Verzé  


---

# FOREWORD

**W**e are delighted that the second International Congress Aortic Surgery "How to do it", organised at San Raffaele Scientific Institute in Milano, is now taking place.

*The key features of this event are:*

- 1. the synergy among vascular and cardiac surgeons;*
- 2. video presentations, concisely allowing the audience to focus on the surgical details;*
- 3. a selected Faculty of prominent international experts;*
- 4. wide-ranging topics from open to endovascular techniques, from chronic to acute and emergency pathology of all the aortic districts;*
- 5. a stimulating exchange of ideas involving an audience with more and more attendees from both Europe and overseas.*

*We are pleased to welcome all participants, real protagonists of this meeting, to our Institute, to which we are grateful for the kind hospitality.*

*Special thanks go to Dr. Raffaella Voltolini, General Manager of Vita-Salute San Raffaele University, for the help offered to us in organising this congress.*

*We would also like to thank all the Colleagues who were prompt in sending us their abstracts, Dr. Fabio Massimo Calliari for the artistic elaboration of the original pictures, Mr. Antonio Fortarezza for the art direction. Without them this book would not have been published.*

Roberto Chiesa  
Germano Melissano  
Ottavio Alfieri

---

INDEX

SAN RAFFAELE DEL MONTE TABOR FOUNDATION13

HISTORY	15
ACTIVITIES	17
NEW PROSPECTS	20

THE FIRST EDITION23

SCIENTIFIC ABSTRACTS27

FACULTY28

OPENING LECTURE29

THE ANEURYSMATIC PATIENT	John A. Elefteriades	30
--------------------------	----------------------	----

SESSION I - Aortic Valve, Ascending Thoracic Aorta33

ALTERNATIVE METHODS FOR AORTIC VALVE REPLACEMENT	Francesco Maisano	34
AORTIC VALVE PRESERVATION FOR ANEURYSMATIC AND NON-ANEURYSMATIC DISEASE	Hans Joachim Schäfers	36
ANEURYSMS OF THE ASCENDING AORTA: SURGICAL TECHNIQUES	Ottavio Alfieri	38
IS THERE A PLACE FOR AORTOPLASTY IN MODERN AORTIC SURGERY?	Francis Robicsek	40
REDO SURGERY ON THE ASCENDING AORTA: TREATMENT OF RETRO-STERNAL PSEUDOANEURYSMS BY PORT-ACCESS TECHNIQUES	Francesco Musumeci	42
AORTIC SURGERY IN MARFAN PATIENTS	Marc Schepens	44
TYPE A AORTIC DISSECTIONS	Maurizio Cotrufo	46

SESSION II - Thoracic Aorta: Dissection and Trauma49

ENDOGRAFTS FOR COMPLICATED TYPE B DISSECTIONS	Martin Malina	50
ENDOVASCULAR TREATMENT OF CHRONIC TYPE B AORTIC DISSECTION	Rossella Fattori	52
TYPE I THORACO-ABDOMINAL AORTIC ANEURYSM IN CHRONIC TYPE B DISSECTION: OPEN REPAIR USING COSELLI PROSTHESIS - CASE REPORT	Attilio Odero	54
ACUTE AORTIC SYNDROME	Christoph A. Nienaber	56
ENDOGRAFTS IN AORTIC RUPTURE	Claudio Novali	58

SESSION III - Aortic Arch61

ASCENDING AORTA ENDOVASCULAR REPAIR	Roy K. Greenberg	62
CEREBRAL PROTECTION DURING AORTIC ARCH SURGERY	Lucia Torracca	64
OPEN SURGERY OF THE AORTIC ARCH	Roberto Di Bartolomeo	66
HYBRID PROCEDURES FOR AORTIC ARCH ANEURYSMS: MARSEILLE EXPERIENCE	Patrice Bergeron	68

RESULTS OF ENDOGRAFTING OF THE AORTIC ARCH IN DIFFERENT LANDING ZONES	Roberto Chiesa	70
ENDOVASCULAR REPAIR OF ANEURYSMS INVOLVING THE PROXIMAL AORTIC ARCH	Timothy A.M. Chuter	72

SESSION IV - The Thoraco-Abdominal Aorta75

ELECTIVE SURGICAL MANAGEMENT OF DESCENDING THORACIC AORTIC ANEURYSMS IN THE ENDOVASCULAR ERA	Edouard Kieffer	76
ENDOVASCULAR TREATMENT FOR DESCENDING THORACIC ANEURYSMS	Luigi Inglese	78
OPEN SURGERY FOR TYPE I AND II THORACOABDOMINAL AORTIC ANEURYSMS WITH THE BRANCHED COSELLI GRAFT	Joseph S. Coselli	80
HYBRID APPROACH TO THORACOABDOMINAL AORTIC ANEURYSMS IN PATIENTS WITH PRIOR AORTIC SURGERY	Germano Melissano	82
ENDOVASCULAR REPAIR OF THORACOABDOMINAL AORTIC ANEURYSMS	Timothy A.M. Chuter	84
ENDOVASCULAR TREATMENT OF THORACOABDOMINAL AORTIC ANEURYSMS WITH BRANCHED ENDOGRAFTS: CLEVELAND EXPERIENCE	Roy K. Greenberg	86

SESSION V - AAA Open Surgery89

OPEN SURGICAL TREATMENT OF ABDOMINAL AORTIC ANEURYSM	Carlo Setacci	90
OPEN SURGICAL TREATMENT OF TYPE IV THORACOABDOMINAL AORTIC ANEURYSMS	Joseph S. Coselli	92
OPEN SURGICAL TREATMENT FOR INFLAMMATORY AAA	Andrea Stella	94
OPEN SURGICAL TREATMENT OF AORTO-ENTERIC FISTULAS	Giancarlo Bracale	96
PARARENAL AORTIC ANEURYSMS: A TEN-YEAR EXPERIENCE USING OPEN SURGERY	Fabien Koskas	98
OPEN SURGICAL TREATMENT FOR ILIAC AND HYPOGASTRIC ANEURYSMS	Carlo Pratesi	100

SESSION VI - AAA Endovascular Surgery103

EVAR WITH AORTO-MONO-ILIAC GRAFTS	Vicente Riambau	104
THE VASCULAR INNOVATION ENDOGRAFT IS EFFECTIVE AND DURABLE EVEN IN HIGHLY COMPLEX ANATOMY AND CHALLENGING AAAs	Takao Ohki	106
ENDOVASCULAR REPAIR OF RUPTURED AAA: HOW WE DO IT	Jean-Pierre Becquemin	108
FENESTRATED ENDOGRAFTS	Richard McWilliams	110
ENDOVASCULAR TREATMENT OF AORTO-ILIAC ANEURYSMS WITH THE HELICAL BRANCH ENDOGRAFT	Stéphan Haulon	112
LATE ENDOVASCULAR REOPERATIONS AFTER EVAR FAILURE	Piergiorgio Cao	114
LATE OPEN CONVERSIONS AFTER EVAR FAILURE	Dieter RaitheI	116

MEDICINE THROUGH TIME119

by Prof. Angelo Argenteri	
AMBOISE PARÉ (1510-1590)	120
GIOVANNI BATTISTA MORGAGNI (1682-1771)	126
THÉOPHILE RENÉ MARIE HYACINTHE LAENNEC (1781-1826)	132



'06

*SAN RAFFAELE DEL MONTE TABOR*  
FOUNDATION





*Lay of the Foundation stone. October 1969*



*Main entrance of the San Raffaele Scientific Institute*

The “history” of San Raffaele began in 1950 when Cardinal Schuster, Archbishop of Milano, called Don Luigi Maria Verzé from Verona to “build a Christian hospital”.

Don Luigi started his activity in the health care field by devoting himself to the education and professional training of teenagers from the city outskirts and to the caring of the aged, both ill and self-sufficient.

The Association *Centro Assistenza Ospedaliera San Romanello* was set up on August 5<sup>th</sup> 1958 with the specific task of creating a teaching hospital, which was conceptually new.

On 5<sup>th</sup> July 1960, Cardinal Giovanni Battista Montini blessed the blueprint model and works started in January 1968 in Segrate, just outside Milano.

On October 24<sup>th</sup> 1969 the Mayor of Milano and the Mayor of Segrate laid the Foundation stone of the hospital. On April 30<sup>th</sup> 1970 the Association *Centro Assistenza Ospedaliera San Romanello* created the



*Centro San Romanello del Monte Tabor* Foundation, a privately owned ecclesiastic board, entrusting it with the construction of San Raffaele Hospital.

On October 31<sup>st</sup> 1971 the first patient was admitted.

Thanks to an inter-ministerial decree the Foundation was later recognized as a *Istituto di Ricovero e Cura a Carattere Scientifico*.

On June 14<sup>th</sup> 1973 the President, Professor Luigi Maria Verzé, and the Chancellor of the University of Milano, Professor Giovanni Schiavinato, signed a didactical-scientific cooperation agreement; on its basis San Raffaele became a University Centre for the Faculty of Medicine and Surgery with a School of Medical Humanities.

During this period, highly advanced technical laboratories were built for specialized branches of clinical research.

The second block of San Raffaele Hospital was officially opened in 1980. The DIMER (Department for Physical Medicine and Rehabilitation) was opened in 1985.

The third block was opened in 1986.

The fourth block (the International Heart Centre) and the main building of the Neurosciences were opened in 1991.

In the early nineties was founded the Department of Biotechnology (DIBIT), the centre for scientific, basic and clinical research.

In 1996 was opened the Vita-Salute San Raffaele University and its Faculty of Psychology, enlarged in 1998 with the Faculty of Medicine and Surgery.

In 2004 were laid four important foundation stones: the second Biotechnology Department (DIBIT2), the Department of Maternal and Child Health, the new Emergency Department and the hotel to lodge patients' relatives.

In 2005 opened the nursery-school reserved to employees' children and in 2006 the first building of DIBIT2 for Laboratory Medicine (Laboraf) was inaugurated.



*The fourth block (International Heart Centre)  
Headquarters of Vascular and Cardiac Surgery Departments*



*The new hotel reserved to patients' relatives*

The *San Raffaele del Monte Tabor* Foundation, founded in 1971 by Luigi Maria Verzé, is an organization that includes many activities:

**San Raffaele Scientific University Institute**

Built in 1971, today it is one of the biggest hospital in Italy, with about 3.400 employees and 1.068 beds.

In 2005:

- over 55,000 hospitalizations;
- over 6 millions of out-patient services;
- over 21,000 surgeries performed;
- over 50,000 Emergency Department's accesses.

The Institute is a national centre for Biotechnology, Molecular Medicine and Bio-images.



Department of Biotechnology (DIBIT)

Founded in 1992 with more than 400 researchers, it is the biggest private Italian centre of biomedical research. It is one of the most qualified centres in Europe for scientific, basic and clinical research in different fields: Gene Therapy, Immunology and Infectious Diseases, Genomics, Neuroscience and Molecular Biology.

In 2005 were published 666 scientific articles, with a total impact factor of 3412.

San Raffaele Turro Hospital

It is owned and managed from 1998 by the *San Raffaele del Monte Tabor* Foundation. Besides the Psychiatric Departments, there are the Neurology and Urology Departments, with altogether 314 beds, the Clinical Psychology Service, several diagnostic and rehabilitation services and research laboratories as well.

Vita-Salute San Raffaele University

A hospital dedicated purely to health care is a thing of the past. The hospital of the present and of the future has to be “intelligent”, that is a place of multidisciplinary culture and science, which is active in the support of human life. This fully defines the Vita-Salute (Life and Health) San Raffaele University where scientific research goes hand in hand with humanistic culture, and where the teaching is at the service of the individual. Vita-Salute San Raffaele University was built on the solid foundations of the San Raffaele Scientific Research Hospital, which is a structure that embodies both experimental and humanistic philosophies.

At the Vita-Salute San Raffaele University various opportunities are



Dibit2 building

1/2/3) Main entrance of the San Raffaele Scientific Institute  
"Good Samaritan" square and fountain

4) Dibit2 building

5/6) São Rafael Hospital - Salvador de Bahia



offered. The Faculty of Psychology follows the general-cognitive and the experimental-clinical lines of thought.

The Faculty of Medicine and Surgery proposes courses in Medicine and Surgery and in Biotechnology, both with strong scientific connotations, where the students go on ward rounds from their very first year.

Moreover in 2002 was created the Faculty of Philosophy and in 2005 was inaugurated the Degree Course in Sciences of Communication. Besides, the University Courses in Nursing and in Physiotherapy offer advanced teaching together with intense practical clinical training. In addition to these courses the Vita-Salute San Raffaele University also houses a number of Medical Training Programmes.

Editorial issues

Kos, monthly magazine of medicine, culture and human science; l'Ala, medicine and health magazine; essays and specialised publications on psychology, culture and philosophy.

San Raffaele in the world

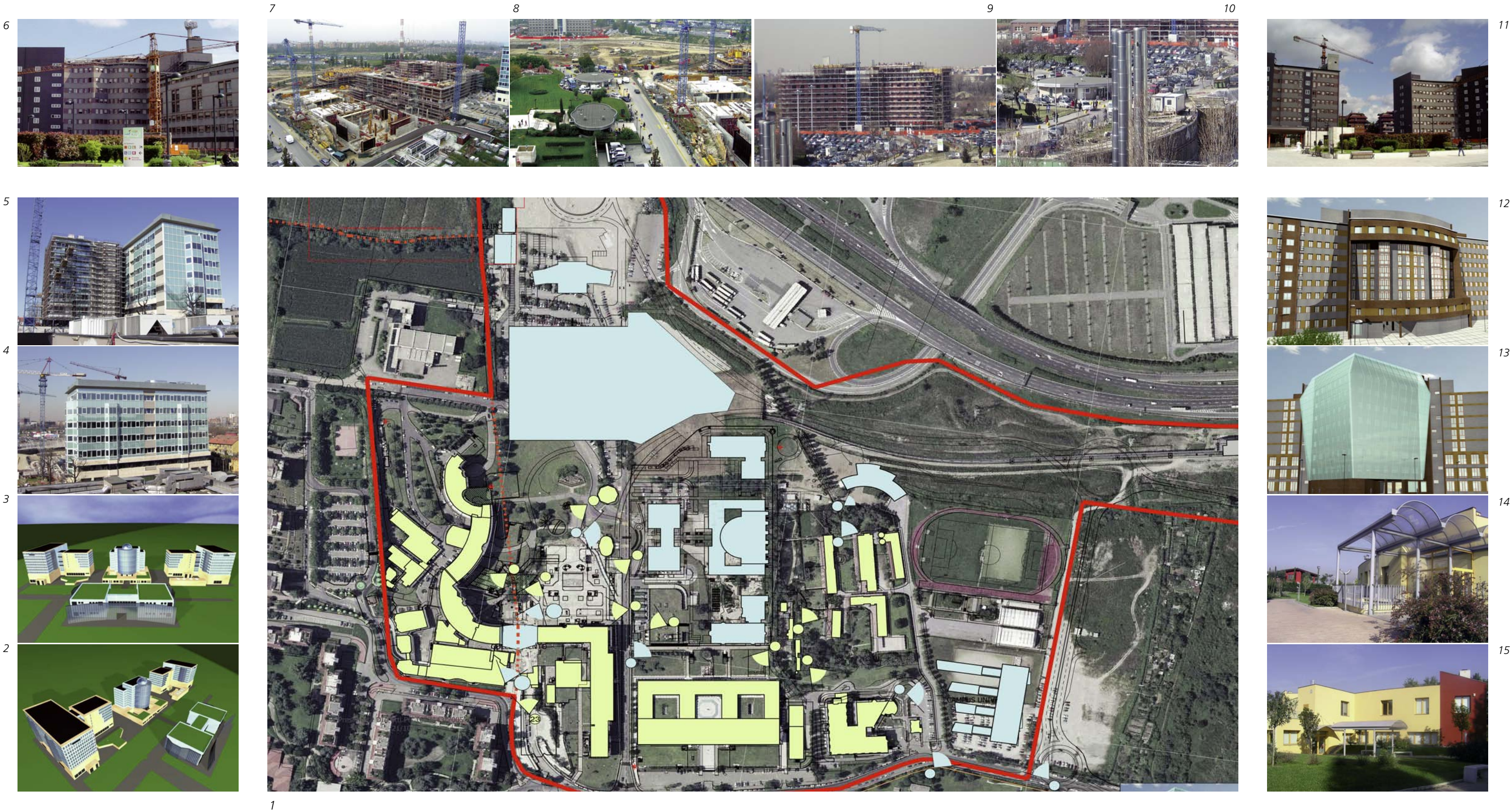
The San Raffaele Foundation operates internationally with AISPO (Italian Association for People's Solidarity) a non-profit association created in 1984 and recognised by the Italian Foreign Office as a non government organization (ONG) suited for the implementation of international health and educational cooperation programs.

Moreover it owns the *São Rafael Hospital* a clinical establishment in Brazil, which introduced in Salvador de Bahia the idea of “general hospital”, able to give an integrated assistance to the patients; for this reason it is at the forefront of internal organisation, technology level and standard of the care.



NEW PROSPECTS

- 1) Comprehensive plan
- 2/3) Digital graphic illustrations of the new buildings reserved to the second Biotechnology Department (DIBIT2) and to Vita-Salute San Raffaele University
- 4/5) The DIBIT2 building in course of construction
- 6) Works in progress in the area of the San Raffaele Scientific Institute
- 7/8) Works in progress in the area of the DIBIT2 building
- 9/10) Works in progress in the area of the hotel reserved to patients' relatives
- 11/12/13) Works in progress in the area of the San Raffaele Scientific Institute: picture of the building site and digital graphic illustrations of the new departments
- 14/15) Pictures of the nursery-school reserved to the employees' children







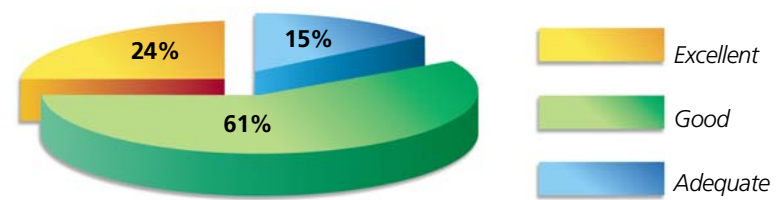
'06

THE FIRST EDITION

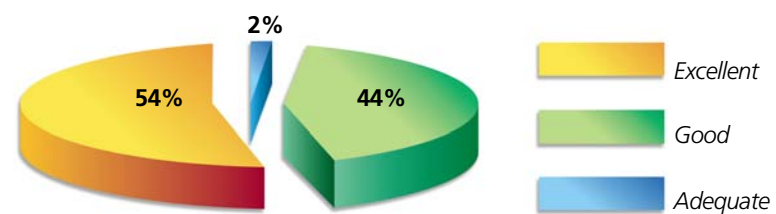


Thanks to the high scientific level of the lectures and to a stimulating exchange of ideas, the over 1.000 participants who have attended the congress, coming from several countries of Europe and overseas, have positively evaluated the meeting.

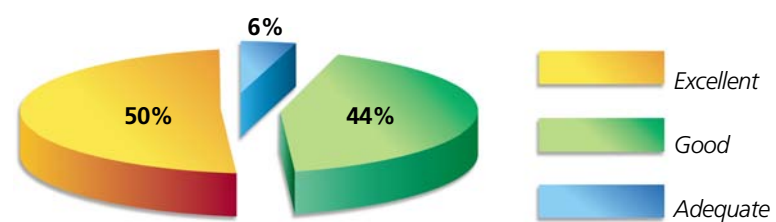
### Relevance of the topics discussed



### Educational quality of the congress



### Efficacy of the congress for the continuous medical education

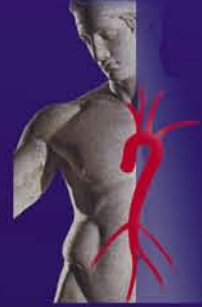

Participants' countries of origin	(%)
Spain	50.0
France	25.0
Italy	10.0
Germany	10.0
Other countries	5.0

Italy	88,90
Belgium	2,95
France	2,75
The Netherlands	1,20
Brasil	1,00
Poland	1,00
Germany	0,60
Spain	0,60
USA	0,40
Norway	0,20
Greece	0,20
Portugal	0,20







'06

## SCIENTIFIC ABSTRACTS

Giorgio Agrifoglio, MILANO - ITALY
Ottavio Alfieri, MILANO - ITALY
Carlo Antona, MILANO - ITALY
Angelo Argenterì, LODI - ITALY
Xavier Barral, SAINT ETIENNE - FRANCE
Jean-Pierre Becquemin, PARIS - FRANCE
Fabrizio Benedetti-Valentini, ROMA - ITALY
Patrice Bergeron, MARSEILLE - FRANCE
Giuseppe Bianchi, ROMA - ITALY
Giorgio Biasi, MONZA (MI) - ITALY
Paolo Biglioli, MILANO - ITALY
Stefano Bonardelli, BRESCIA - ITALY
Giancarlo Bracale, NAPOLI - ITALY
Alain Branchereau, MARSEILLE - FRANCE
Piergiorgio Cao, PERUGIA - ITALY
Luigi Chiariello, ROMA - ITALY
Roberto Chiesa, MILANO - ITALY
Timothy A.M. Chuter, SAN FRANCISCO - CA - USA
Joseph S. Coselli, HOUSTON - TX - USA
Maurizio Cotrufo, NAPOLI - ITALY
Luigi de Luca Tupputi Schinosa, BARI - ITALY
Ruggero De Paulis, ROMA - ITALY
Giovanni Deriu, PADOVA - ITALY
Roberto Di Bartolomeo, BOLOGNA - ITALY
Vincent M. Dor, MONTECARLO - MONACO
John A. Elefteriades, NEW HAVEN - CT - USA
Rossella Fattori, BOLOGNA - ITALY
Livio Gabrielli, MILANO - ITALY
Tiziano Gherli, PARMA - ITALY
Pierluigi Giorgetti, ROZZANO (MI) - ITALY
Bruno Gossetti, ROMA - ITALY
Roy K. Greenberg, CLEVELAND - OH - USA
Adalberto Grossi, MILANO - ITALY
Stéphan Haulon, LILLE - FRANCE
Luigi Inglese, S. DONATO MILANESE (MI) - ITALY
Edouard Kieffer, PARIS - FRANCE
Fabien Koskas, PARIS - FRANCE
Jean-Georges Kretz, STRASBOURG - FRANCE

Jon Largiadèr, ZURICH - SWITZERLAND
Karaoglan Liberato de Moura, SALVADOR - BA - BRASIL
Armando C. Lobato, SAO PAULO - SP - BRASIL
Giovanni Lorenzi, LECCO - ITALY
Francesco Maisano, MILANO - ITALY
Martin Malina, MALMO - SWEDEN
Enrico M. Marone, MILANO - ITALY
Attilio Maseri, MILANO - ITALY
Richard G. McWilliams, LIVERPOOL - UK
Germano Melissano, MILANO - ITALY
D. Craig Miller, STANFORD - CA - USA
Francesco Musumeci, ROMA - ITALY
Christoph A. Nienaber, ROSTOCK - GERMANY
Claudio Novali, CUNEO - ITALY
Attilio Odero, PAVIA - ITALY
Takao Ohki, TOKYO - JAPAN
Domenico Palombo, GENOVA - ITALY
Adamastor Humberto Pereira, PORTO ALEGRE - RS - BRASIL
Giuseppe Raimondo Pistolese, ROMA - ITALY
Carlo Pratesi, FIRENZE - ITALY
Maurizio Puttini, MILANO - ITALY
Dieter Raithe, NUREMBERG - GERMANY
Vincenzo Rampoldi, S. DONATO MILANESE (MI) - ITALY
Guido Regina, BARI - ITALY
Vicente Riambau, BARCELONA - SPAIN
Francis Robicsek, CHARLOTTE - NC - USA
Ugo Ruberti, MILANO - ITALY
Hans Joachim Schäfers, HOMBURG - GERMANY
Marc Schepens, NIEUWEGEIN - THE NETHERLANDS
Carlo Setacci, SIENA - ITALY
Marco Setti, BERGAMO - ITALY
Carlo Spartera, L'AQUILA - ITALY
Francesco Speziale, ROMA - ITALY
Francesco Spinelli, MESSINA - ITALY
Andrea Stella, BOLOGNA - ITALY
Domenico Tealdi, S. DONATO MILANESE (MI) - ITALY
Lucia Torracca, MILANO - ITALY



SCIENTIFIC ABSTRACTS

OPENING LECTURE

THE ANEURYSMATIC PATIENT - John A. Elefteriades

# THE ANEURYSMATIC PATIENT

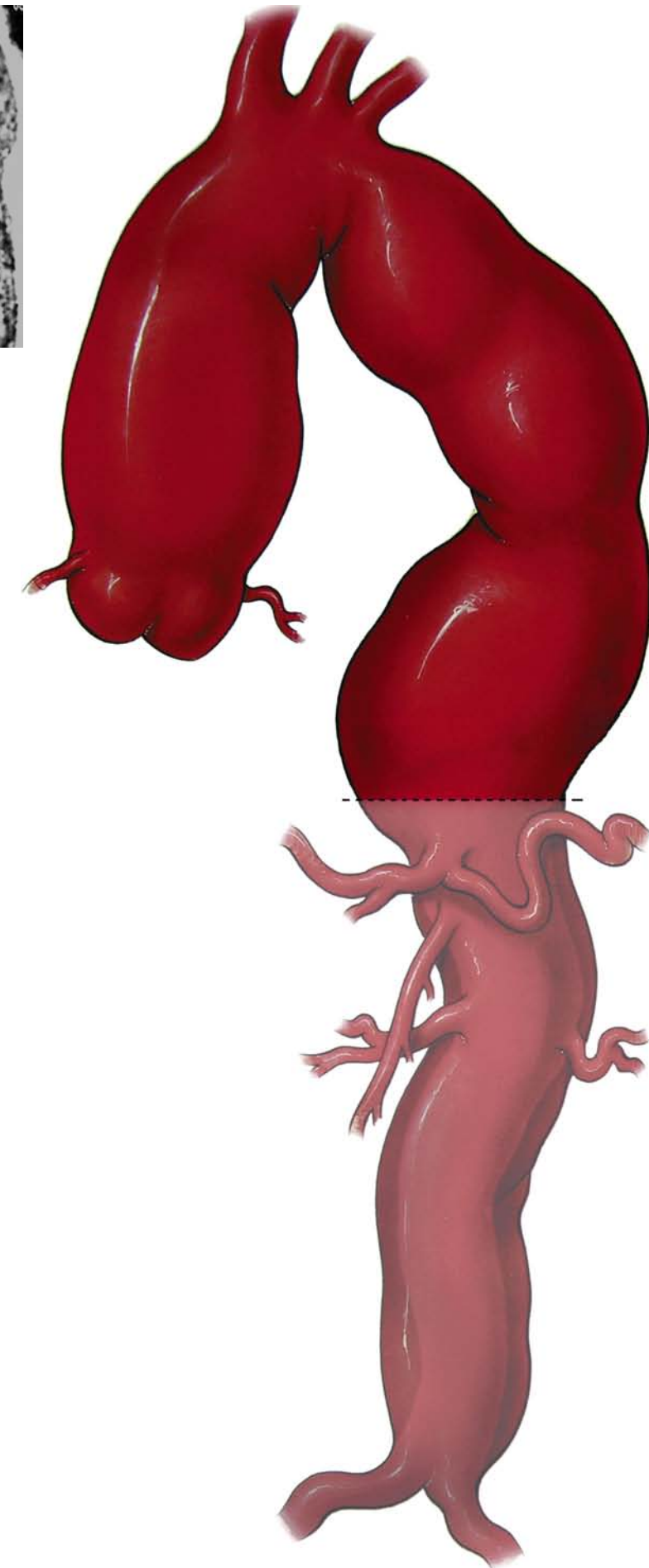
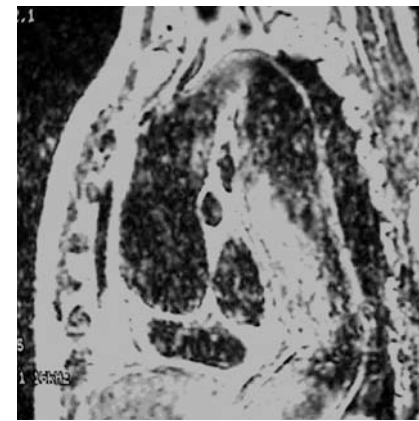
**John A. Elefteriades**

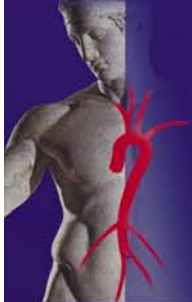*Yale University School of Medicine, New Haven - CT - USA*

We are recognizing increasingly that there is a category of patient with diffuse enlargement of the aorta, involving all segments, either at the same time or over long-term follow-up. It is apparent that these patients suffer from diffuse weakness of the aortic tissues. We will examine the following issues regarding these aneurysmatic patients:

- When do these patients rupture or dissect?
- What are the patterns of aneurysm cross-over between sites?
- What causes this diffuse “Aneurysmatic” disease?
- Is there any medical rx for these patients?
- Can we improve our predictive models?
- What brings on the acute events?

We will find that: The time of rupture or dissection can be predicted fairly well. There are distinct patterns of cross-over between aneurysms in various organs and vascular distributions-both within the same patient and among affected family members. Insights into the pathophysiology of aneurysm formation are most cogent regarding this group of aneurysmatic patients. Medical managements are beginning to emerge which promise to prevent enlargement and progression of the aorta in the aneurysmatic patient. There is ample room for improvement in our models predicting aneurysm behavior-using mechanical measurements and biomarkers. We are also beginning to understand what causes a dissection or rupture event to occur at one specific point in time; this usually involves transient hypertension from exertion or emotion.





'06

SCIENTIFIC ABSTRACTS

SESSION I - Aortic Valve, Ascending Thoracic Aorta

*President:* Maurizio Cotrufo  
*Chairmen:* Luigi Chiariello, Vincent Dor  
*Discussants:* Carlo Antona, Ruggero De Paulis, Tiziano Gherli

ALTERNATIVE METHODS FOR AORTIC VALVE REPLACEMENT	Francesco Maisano
AORTIC VALVE PRESERVATION FOR ANEURYSMATIC AND NON-ANEURYSMATIC DISEASE	Hans Joachim Schäfers
ANEURYSMS OF THE ASCENDING AORTA: SURGICAL TECHNIQUES	Ottavio Alfieri
IS THERE A PLACE FOR AORTOPLASTY IN MODERN AORTIC SURGERY?	Francis Robicsek
REDO SURGERY ON THE ASCENDING AORTA: TREATMENT OF RETRO-STERNAL PSEUDOANEURYSMS BY PORT-ACCESS TECHNIQUES	Francesco Musumeci
AORTIC SURGERY IN MARFAN PATIENTS	Marc Schepens
TYPE A AORTIC DISSECTIONS	Maurizio Cotrufo

# ALTERNATIVE METHODS FOR AORTIC VALVE REPLACEMENT

**Francesco Maisano**

*San Raffaele Scientific Institute, Milano - Italy*

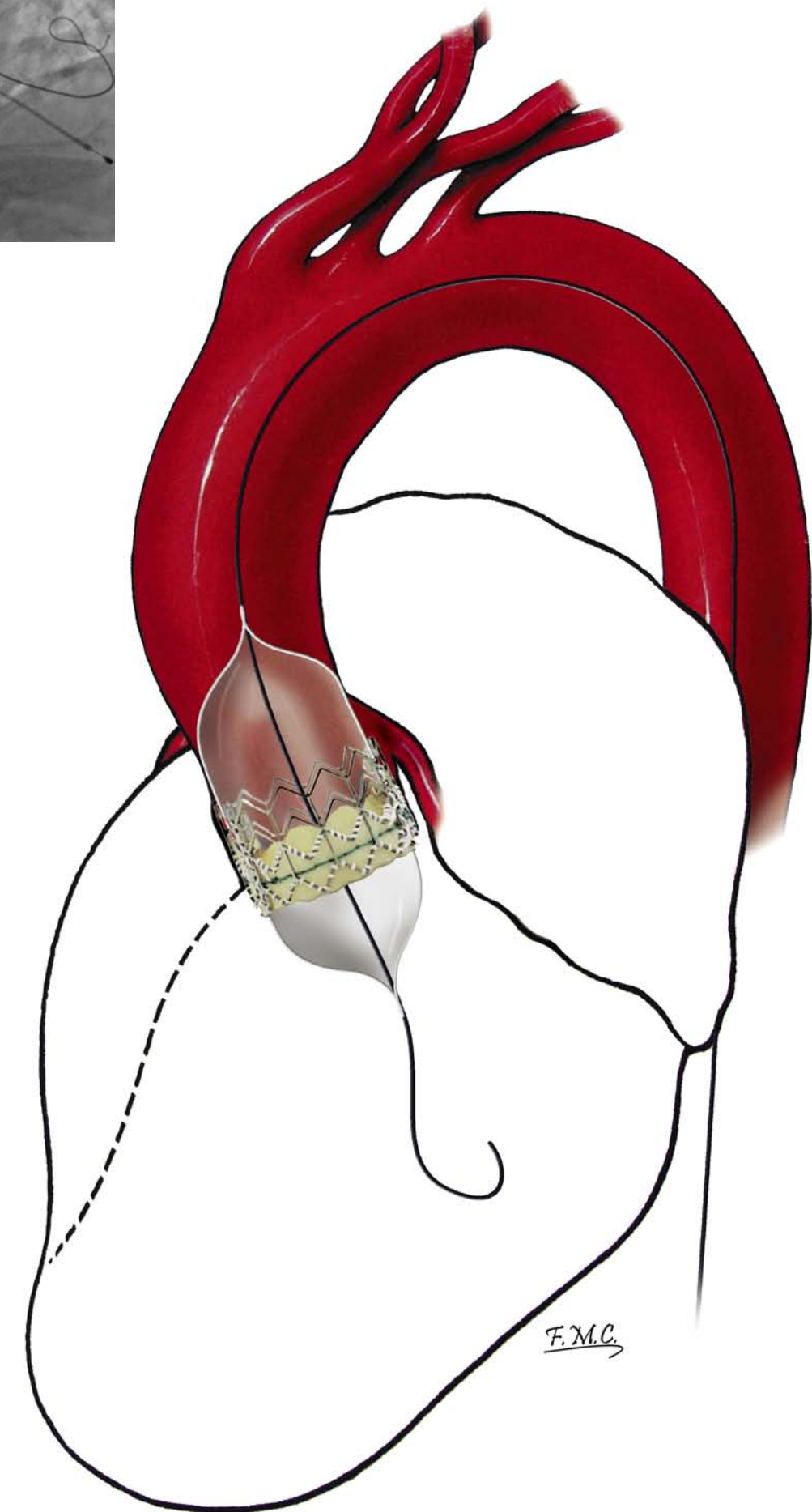
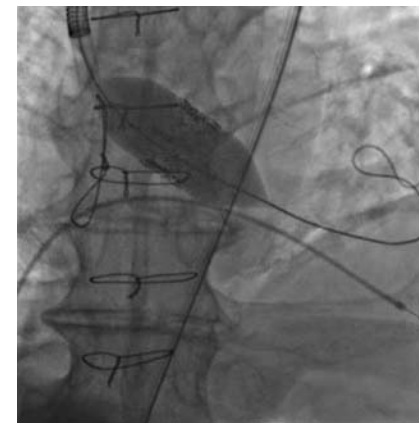
New percutaneous valve interventions (PVIs), in which heart valve replacement and repair products are delivered to the heart using catheter-based techniques, are under development and initial clinical trials. As an addition to existing aortic balloon dilatation procedures, transcatheter replacement products to treat aortic disease are being developed.

The transcatheter procedure can be carried out with three possible approaches. The antegrade approach, requires a femoral vein cannulation and a transeptal puncture to reach the valve from the left ventricle. In the retrograde approach, the aortic valve is reached via the arterial tree through a femoral artery puncture. The third approach is still antegrade, but the insertion site is the apex of the left ventricle, exposed with a small thoracotomy. With either approach, the aortic valve is predilated, and the valved stent is placed under fluoroscopic guidance, using the calcium on the leaflets as a reference.

As these new procedures are on their way towards clinical practice, the role of the cardiac surgeon in PVIs is under discussion. Most cardiac surgeons are not going to be involved in transcatheter procedures, because of lack of skill and the access to the required equipment, as well as because of a fundamental skepticism.

Then, two possible scenarios are emerging. One option is that, similarly to the change (or chance) occurring in vascular surgery for aortic endovascular stent grafting, cardiac surgeons will adapt their skills and organize the operating rooms with fluoroscopy, getting access to this promising field of cardiovascular medicine. On the other hand, surgeons may remain conservative and leave the field to interventional cardiologists, who will yet have to adapt to new procedures and to new diseases.

As a matter of fact, it appears evident that, at this stage, there are few specialists ready for such procedures. Moreover, introduction of PVIs is going to strongly involve other specialties including echocardiography, anesthesiology and intensive care. These procedures will need a team-work approach, at least in an initial phase. Whatever the organizational scenario, PVIs are going to strongly influence the treatment of valve heart disease in the next 5 to 10 years.





# AORTIC VALVE PRESERVATION FOR ANEURYSMATIC AND NON-ANEURYSMATIC DISEASE

Hans Joachim Schäfers

University Hospital of Saarland, Homburg/Saar - Germany

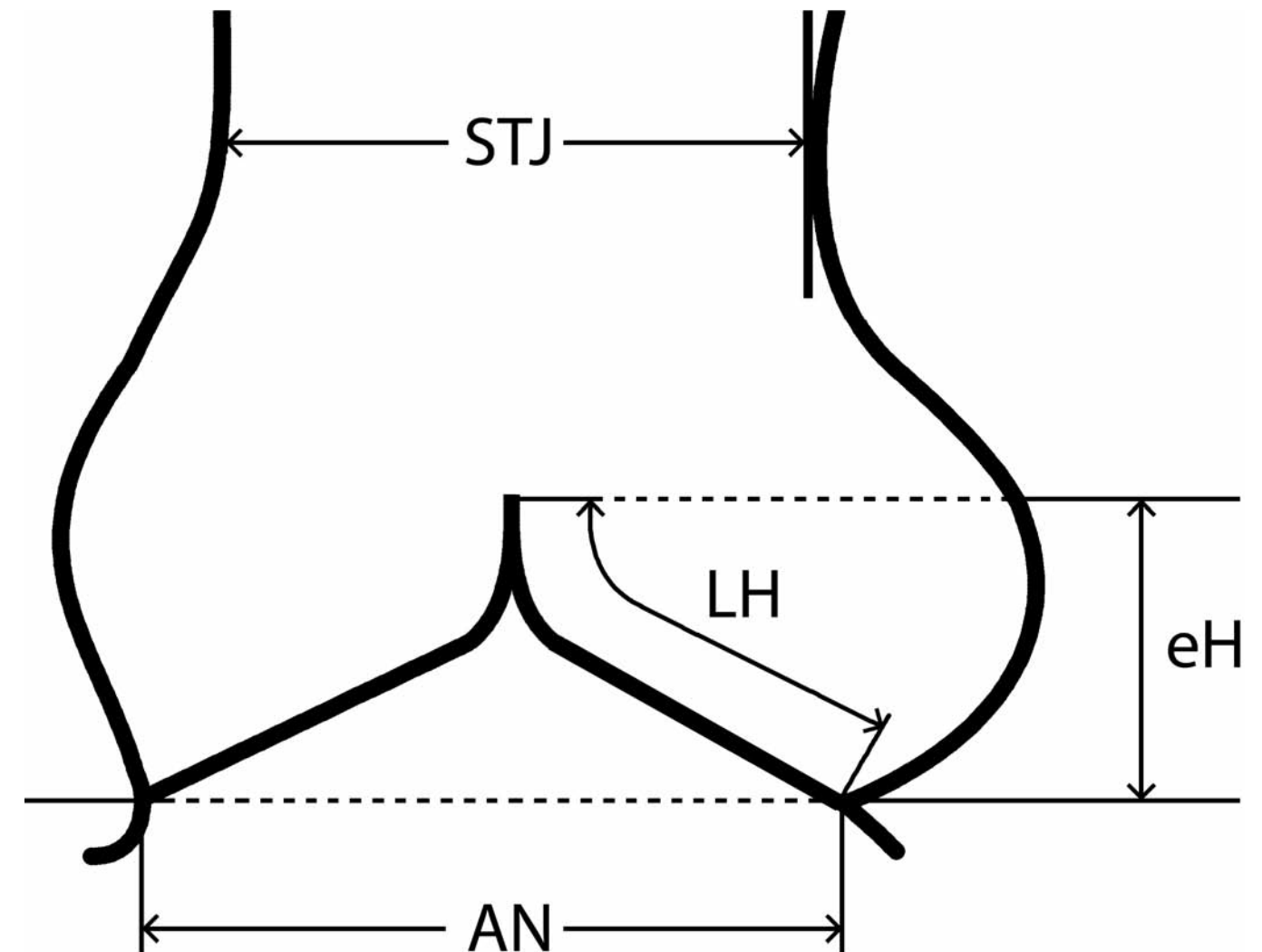
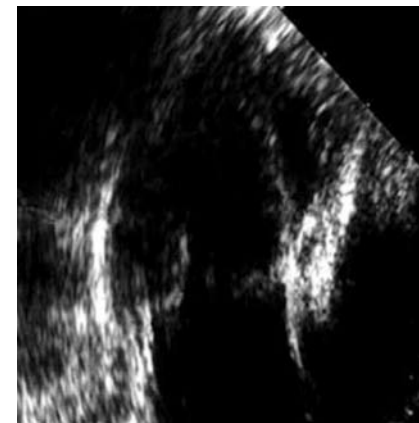
Background: Besides valve reimplantation aortic root remodeling is a surgical option for patients with dilatation of the aortic root and aortic valve regurgitation if prosthetic replacement of the valve is to be avoided. The goal of the procedure is restoration of a normal configuration of root and valve by eliminating dilatation of sinuses and sinutubular junction. Ideally it results in normal systolic and diastolic aortic valve function. Root remodeling appears appropriate when the aortoventricular junction is not markedly dilated (<30 mm). Commonly, sinuses (>45 mm) as well as the sinutubular junction are significantly enlarged (>32 mm or >38-40 mm by TEE).

Technique: After cardioplegic arrest the aorta is transected above the commissures. We always measure the diameter of the aortoventricular junction and chose the vascular graft 1 to 2 mm smaller. Careful inspection of the aortic valve is important in order to define cusp pathology (prolapse, fenestrations, calcium). After the root is mobilized and the sinuses excised the graft is prepared with 3 symmetric incisions to accommodate the commissures. The length of the incisions is kept ~ 20% less than estimated, and sinus-shaped tongues are created. We always start suturing in center of a sinus (e.g. left) and continue towards the commissures. The incisions in the graft may be extended as needed. After the 3rd sinus is finished the aortic valve is inspected again. Measurement of height difference between insertion and free margin of a cusp helps to identify prolapse. If prolapse is found (in most instances), it is corrected by plication of the cusp margin or triangular excision of cusp tissue. Reimplantation of the coronary arteries and connection of the graft to the aorta are performed in routine fashion.

Results: From October 1995 until April 2006, 262 patients (mean age was  $60 \pm 15$  years) underwent root remodeling for aortic root aneurysm. Cusp pathology was additionally corrected in 158 patients (60.3 %). Follow-up was complete in 99%.

Hospital mortality was 3.8% (10/262; elective surgery: 3.2 %; emergency surgery: 7 %). Freedom from AI > II was 91% at 5 and 90% at 10 years. Eight patients required reoperation (5 replacements, 3 patients re-repairs). Freedom from reoperation was 96% at 5 and 10 years, freedom from valve replacement 98% at 5 and 10 years.

Conclusion: Root remodeling leads to good reconstitution of aortic root and valve geometry if cusp geometry is corrected in addition.



# ANEURYSMS OF THE ASCENDING AORTA: SURGICAL TECHNIQUES

**Ottavio Alfieri**

*San Raffaele Scientific Institute, Milano - Italy*

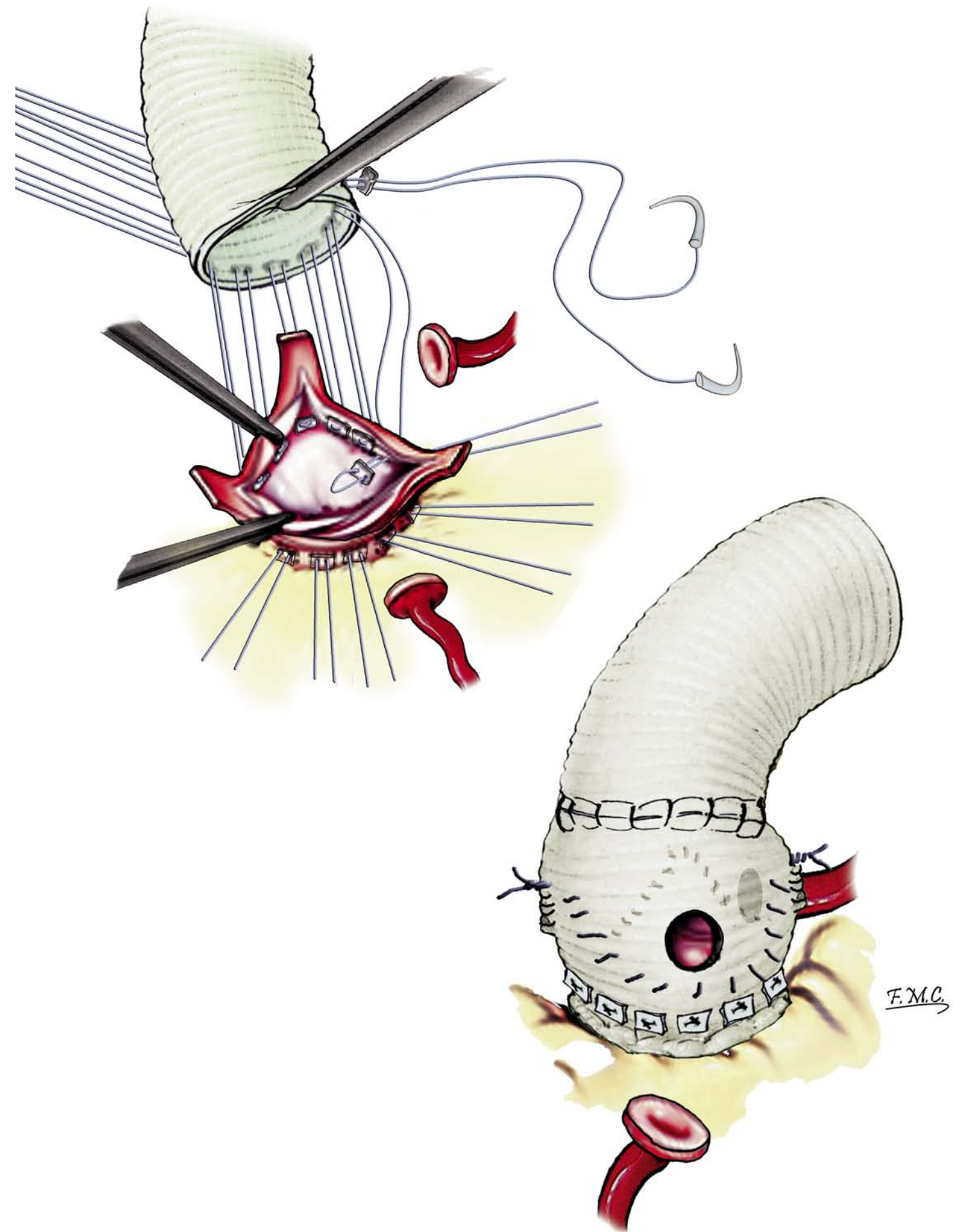
The surgical options to treat aneurysms of the ascending aorta are different, according to the involved portion of the ascending aorta, to the extension of the aneurysm and to the anatomical and functional features of the aortic valve.

The isolated replacement of the ascending aorta above the coronary ostia is carried out when only the tubular portion of the ascending aorta is dilated, while the sinuses of Valsalva and sino-tubular junction are not involved by the aneurysmatic process. This situation is frequently observed in presence of a bicuspid aortic valve. In such a context the aortic valve can be left alone if adequately functioning. Alternatively the bicuspid aortic valve can be repaired or replaced, according to the anatomy and to the mechanism responsible for the dysfunction.

When the aneurysmatic dilatation is involving the root of the ascending aorta including the sinuses of Valsalva and consequently the coronary ostia are dislocated in relation to the plane of the aortic valve, the most common surgical procedures are: the Bentall operation (in presence of an organic disease of the aortic valve) or the David operation (when the aortic valve is morphologically normal). This latter operation is illustrated in the figure, where the preservation of the native aortic valve implanted inside a dacron graft is shown. The tubular dacron graft is fixed at the base of the aortic root with separated U stitches and the coronary ostia are sutured to the graft.

The David operation can be extended also to patients with an aortic valve presenting morphological changes easily amenable to surgical repair.

When the ascending aorta aneurysm is distally extended, selective cerebral perfusion and hypothermia are used, as in aortic arch surgery.



# IS THERE A PLACE FOR AORTOPLASTY IN MODERN AORTIC SURGERY?

**Francis Robicsek**

*Carolinas Medical Center, Charlotte - NC - USA*

**Objective:** Reduction ascending aortoplasty (RAA) is a controversial procedure. Some believe that it may be appropriately applied whenever the anatomical features are favorable. Others suggest that it should be restricted to those who are unacceptably high-risk for more radical procedures and there are also those who believe that RAA should not be applied at all. The purpose of the paper is to draw conclusions on the applicability of RAA in modern cardiovascular surgery.

**Methods:** The issue was examined in the mirror of the authors' own experiences, by review and scrutiny of the literature available on the subject and by conducting an extensive survey of the profession.

**Results:** We found that given proper indications, i.e. "post-stenotic" dilatations of <6 cms diameter, absence of cystic medial necrosis and a technique, which decreases aortic diameter to <3.5 cms, non-reinforced RAA, done concomittantly with aortic valve replacement appears to be a simple and safe procedure, with low morbidity and mortality and with rare late complications. External reinforcement may extend the scope of indication for RAA to AscA's associated with aortic regurgitation and to those with primary structural aortic wall disease with comparable results. Experience also has shown that late complications may be further reduced by proper proximal anchoring and extending the wrap past the origin of the innominate artery.

**Conclusions:** We conclude that RAA is certainly "alive". While it doesn't appear to be an extremely popular operation, about half of the surgeons who responded believe it to be justified. Regardless of which modality is used, lifetime monitoring of ascending aortic size is essential and so advised. Because of recent, sporadic reports of "under-the-wrap" aortic wall atrophy and rupture, the issue of reinforcement of RAA needs continued re-evaluation.





# REDO SURGERY ON THE ASCENDING AORTA: TREATMENT OF RETRO-STERNAL PSEUDOANEURYSMS BY PORT-ACCESS TECHNIQUES

**Francesco Musumeci**

*Azienda Ospedaliera "San Camillo - Forlanini", Roma - Italy*

F. Musumeci, D. Maselli, G. Casali

**Introduction:** Redo surgery of the ascending aorta is very challenging when a retro-sternal pseudoaneurysm is associated to aortic regurgitation and/or diseased descending aorta. The risk of entering the pseudoaneurysm during sternotomy is high. Closed chest hypothermic circulatory arrest in patients with aortic regurgitation carries a risk of left ventricular dysfunction due to over-stretching of myocardial fibres. Retrograde aortic perfusion in presence of a diseased distal aorta exposes to the risk of cerebral injury.

We propose a surgical strategy based on modified Port-access techniques which allows a safe approach avoiding closed chest hypothermic circulatory arrest.

**Material and methods:** From September 1998 till December 2005 597 patients underwent replacement of the ascending aorta. 78 (13%) were redo operations, in 6 cases the indication was a post-surgical pseudoaneurysm associated to significant aortic regurgitation. In this group we identified two conditions:

Type 1: presence of an endo-clampable native or prosthetic segment of the ascending aorta with normal distal aorta

Type 2: presence of an endo-clampable native or prosthetic segment of the ascending aorta with diseased distal aorta

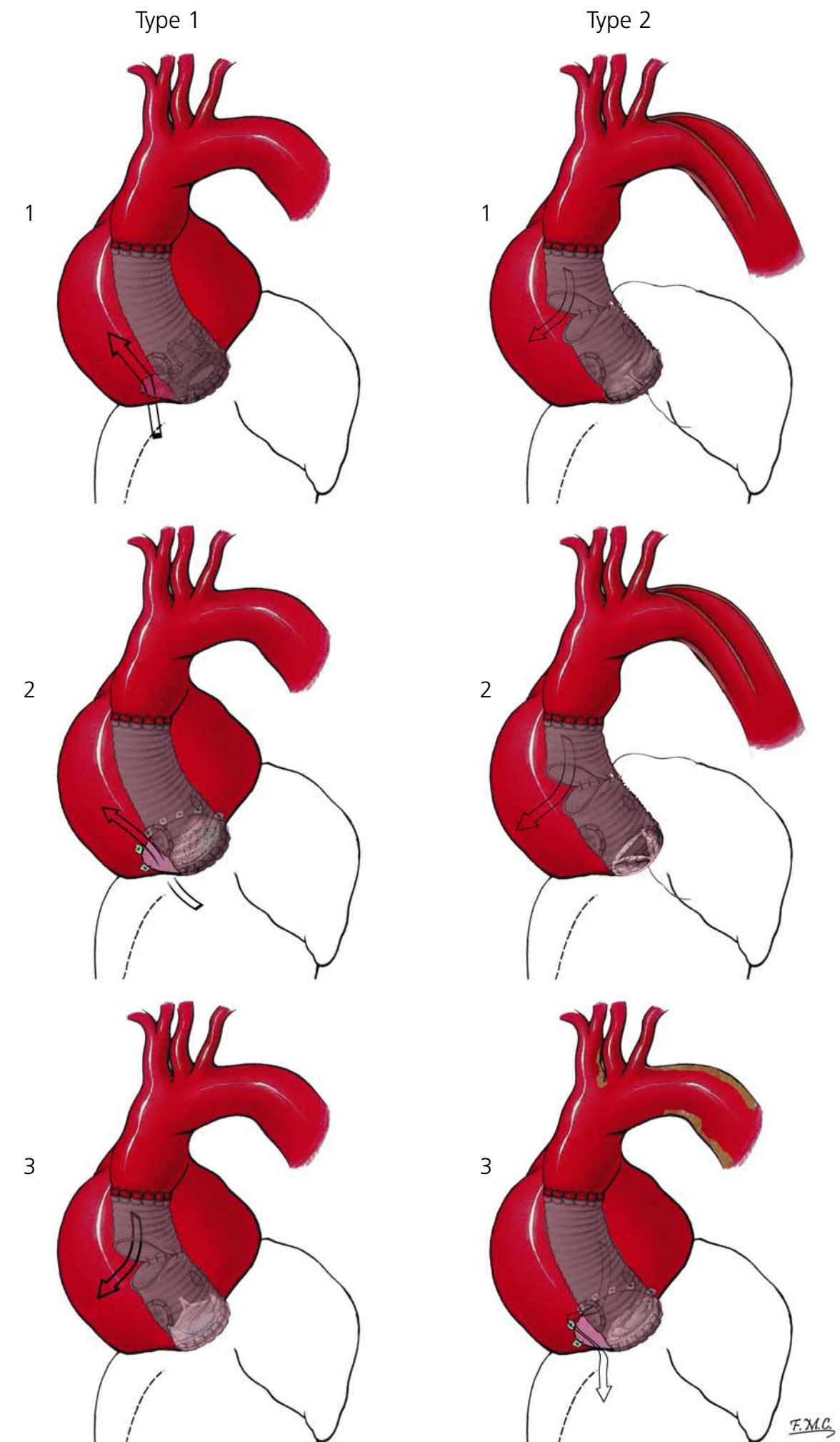
In type 1 lesions femoro-femoral CPB was used. Before sternotomy hypothermic CPB was instituted. When nasopharyngeal temperature reached 32°C the endo-clamp was inflated under TEE control. Cardiac arrest was induced by an adenosine bolus to avoid the endo-clamp displacement. Retrograde blood cardioplegia was administered with simultaneous venting of the aortic root. Once the heart was arrested sternotomy was performed and the prosthesis previously implanted dissected and controlled with conventional cross-clamping. The proximal phase was carried out while nasopharyngeal temperature was lowered to 24–28°C. The distal anastomosis was performed under circulatory arrest.

In type 2 lesions the technique was modified by using the right axillary artery for arterial return and endo-clamp insertion.

**Results:** We had no hospital death and all the patients were free from neurological complications.

**Conclusions:** The port access technique is a safe and effective option for treatment of post-surgical retro-sternal pseudoaneurysms associated to aortic regurgitation.

The modified trans-axillary approach extends the indications of port access technique to patients with diseased distal aorta.

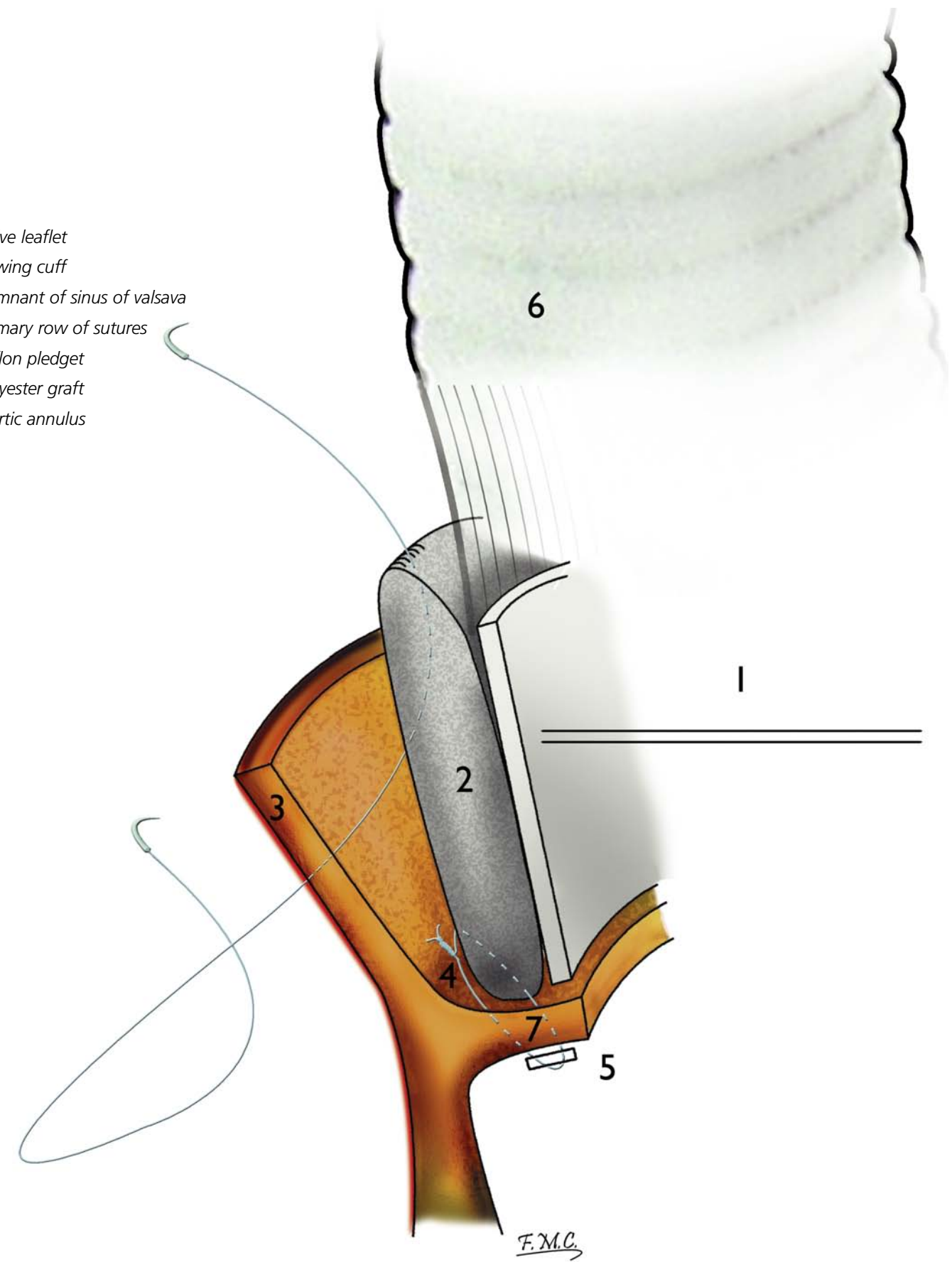


# AORTIC SURGERY IN MARFAN PATIENTS

**Marc Schepens**  
*St. Antonius Hospital, Nieuwegein - The Netherlands*

Marfan's syndrome is an autosomal dominant disorder of connective tissue characterized by abnormalities of the ocular, skeletal and cardiovascular systems. The reduction in fibrillin (a structural component of the elastin-associated microfibrils) as well as abnormalities in its structure, based on a defective gene on chromosome 14, forms the pathologic basis of the disease. Recently additional information became available concerning the pathogenesis: excessive signaling of the transforming growth factor beta (TGFB) plays an important role and can be reversed by the administration of losartan, an antihypertensive drug (angiotensin II type 1 receptor blocker). If left untreated most patients will die young mainly from cardiovascular causes such as dissection, aneurysm rupture or congestive heart failure. Due to the progressive nature of the disease, Marfan patients should be treated prophylactically before the aorta dissects or ruptures, certainly when there is a history of dissection within the family. Aneurysms of the ascending aorta reaching 4.5 cm and 5 cm for the descending thoracic (or thoracoabdominal aorta) are indications for operative repair. Life expectancy can be improved considerably by an aggressive surgical approach. Life-long aortic surveillance is mandatory and patients should avoid heavy sports and exercises. Surgical decision-making differs in Marfan patients as compared to non-Marfan patients. In general Marfan patients are younger and should be treated more aggressively because non-replaced aortic segments will continue to dilate over time threatening the patient at time of reoperation. Surgical principles are identical in Marfan patients compared to non-Marfans. However due to the extreme fragility of the aortic tissue, certain surgical guidelines are mandatory. First of all a meticulous surgical technique is mandatory. Reinforcement of all anastomotic suture lines (e.g. with Teflon or autologous pericardium) might be justified to avoid tearing of the aortic wall, bleeding or false aneurysm formation. The use of large aortic patches surrounding reimplanted side-branches (e.g. in aortic arch replacement or in thoracoabdominal replacement) should be avoided since this residual aortic tissue can dilate over time and rupture; the use of separate branched grafts is preferable. It remains an unanswered question whether a full mechanical aortic root replacement (Bentall operation) is a better option than an aortic valve sparing technique in case of aortic root pathology. The Ross procedure is contra-indicated in the Marfan. The use of aortic stent grafts seems to be feasible but future problems can be expected since aortic segments at the proximal and distal landing zones certainly will dilate causing proximal or distal endoleaks. Therefore we would use this technique only in compassionate cases or in emergent situations in which open surgery carries an unacceptable high risk. It is obvious that Marfan's should be treated in a surgical center with a wide experience in aortic surgery covering all operative options.

- 1. Valve leaflet
- 2. Sewing cuff
- 3. Remnant of sinus of Valsava
- 4. Primary row of sutures
- 5. Teflon pledget
- 6. Polyester graft
- 7. Aortic annulus



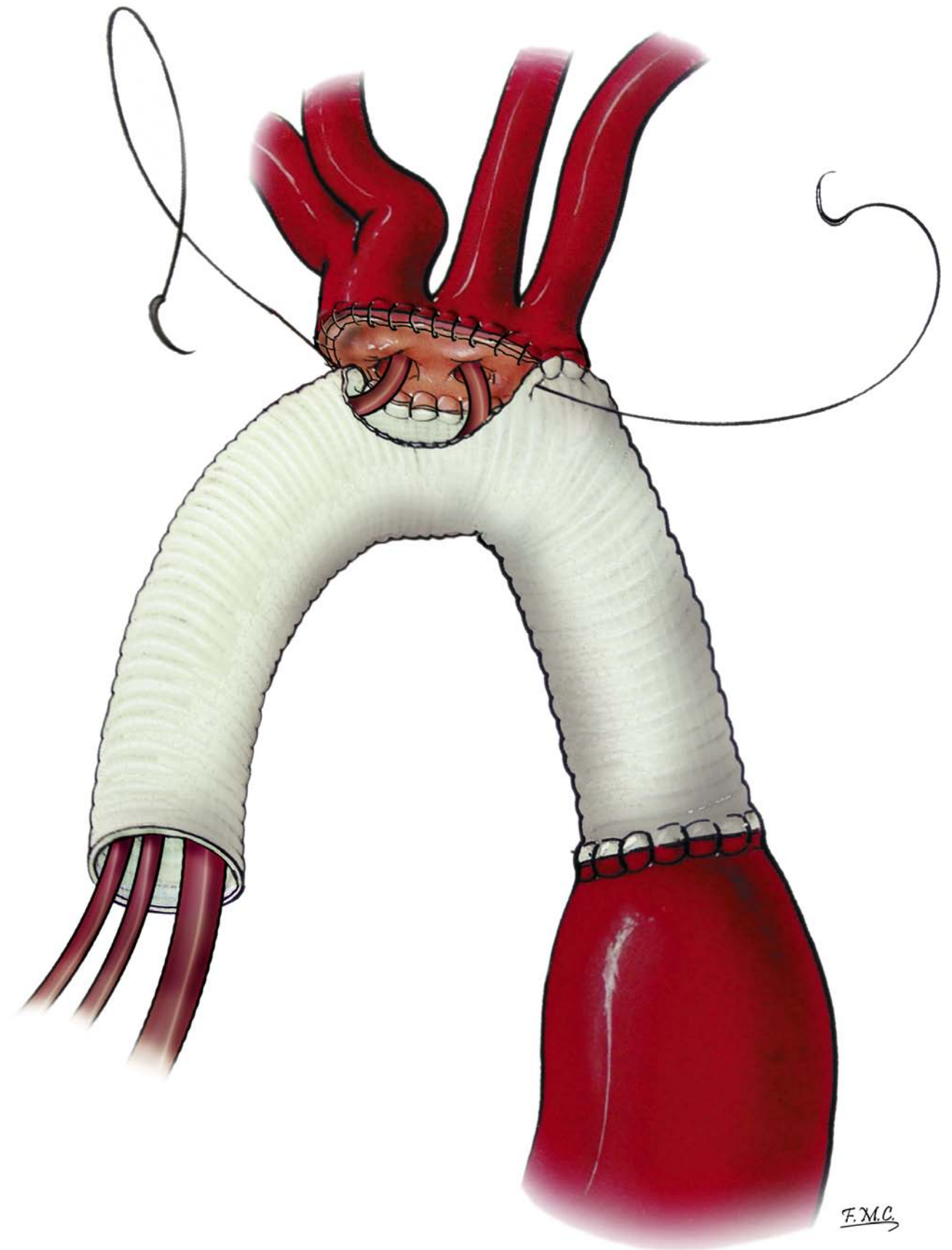


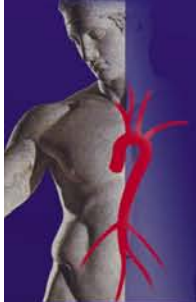# TYPE A AORTIC DISSECTIONS

**Maurizio Cotrufo**

*Second University of Napoli, Monaldi Hospital, Napoli - Italy*

The surgical approach to type A aortic dissections has gone through a long and gradual development process during the last decade, with the aim of improving the once dramatic results and this process cannot be considered concluded yet today. No more controversial is the issue of distal anastomosis, which is always performed “open”, and similarly the supporters of retrograde caval perfusion as the method for cerebral protection are today very few. On the other side, factors that are still subject to significant variations from one Author to another include the methods of perfusion and specifically the site of arterial cannulation, ranging from the ascending aorta (a recently introduced and rapidly spreading method), to the femoral artery or the axillary/subclavian artery. When this is the case, some Authors suggest the use of direct cannulation, others of graft interposition. As regards cerebral protection in aortic arch procedures, the alternative approaches used today are deep hypothermic circulatory arrest and moderate hypothermia with antegrade supra-aortic vessels perfusion, with the possibility of associated antegrade perfusion of the descending aorta, by direct endoluminal aortic cannulation. Some Authors perform cerebral protection through right axillary artery cannulation with or without concomitant left carotid cannulation versus selective cannulation of both the brachio-cephalic trunk and the left carotid artery. The French school endorses the use of biological glue for aortic wall reconstruction and closure of the false lumen, while others maintain that their toxic effect should be taken into account. The type and extension of the dissection must determine the surgical procedure to be adopted, both proximally (aortic valve resuspension versus replacement with Wheat or Bentall techniques) and distally (hemi-arch versus total arch replacement, with supra-aortic branch reimplantation, either individual or as a unit).





SCIENTIFIC ABSTRACTS

SESSION II - Thoracic Aorta: Dissection and Trauma

*President:* Fabrizio Benedetti-Valentini  
*Chairmen:* Edouard Kieffer, Domenico Tealdi  
*Discussants:* Pierluigi Giorgetti, Armando Lobato, Marco Setti

ENDOGRAFTS FOR COMPLICATED TYPE B DISSECTIONS	Martin Malina
ENDOVASCULAR TREATMENT OF CHRONIC TYPE B AORTIC DISSECTION	Rossella Fattori
TYPE I THORACO-ABDOMINAL AORTIC ANEURYSM IN CHRONIC TYPE B DISSECTION: OPEN REPAIR USING COSELLI PROSTHESIS - CASE REPORT	Attilio Odero
ACUTE AORTIC SYNDROME	Christoph A. Nienaber
ENDOGRAFTS IN AORTIC RUPTURE	Claudio Novali

# ENDOGRAFTS FOR COMPLICATED TYPE B DISSECTIONS

**Martin Malina**

*Malmö University Hospital - Sweden*

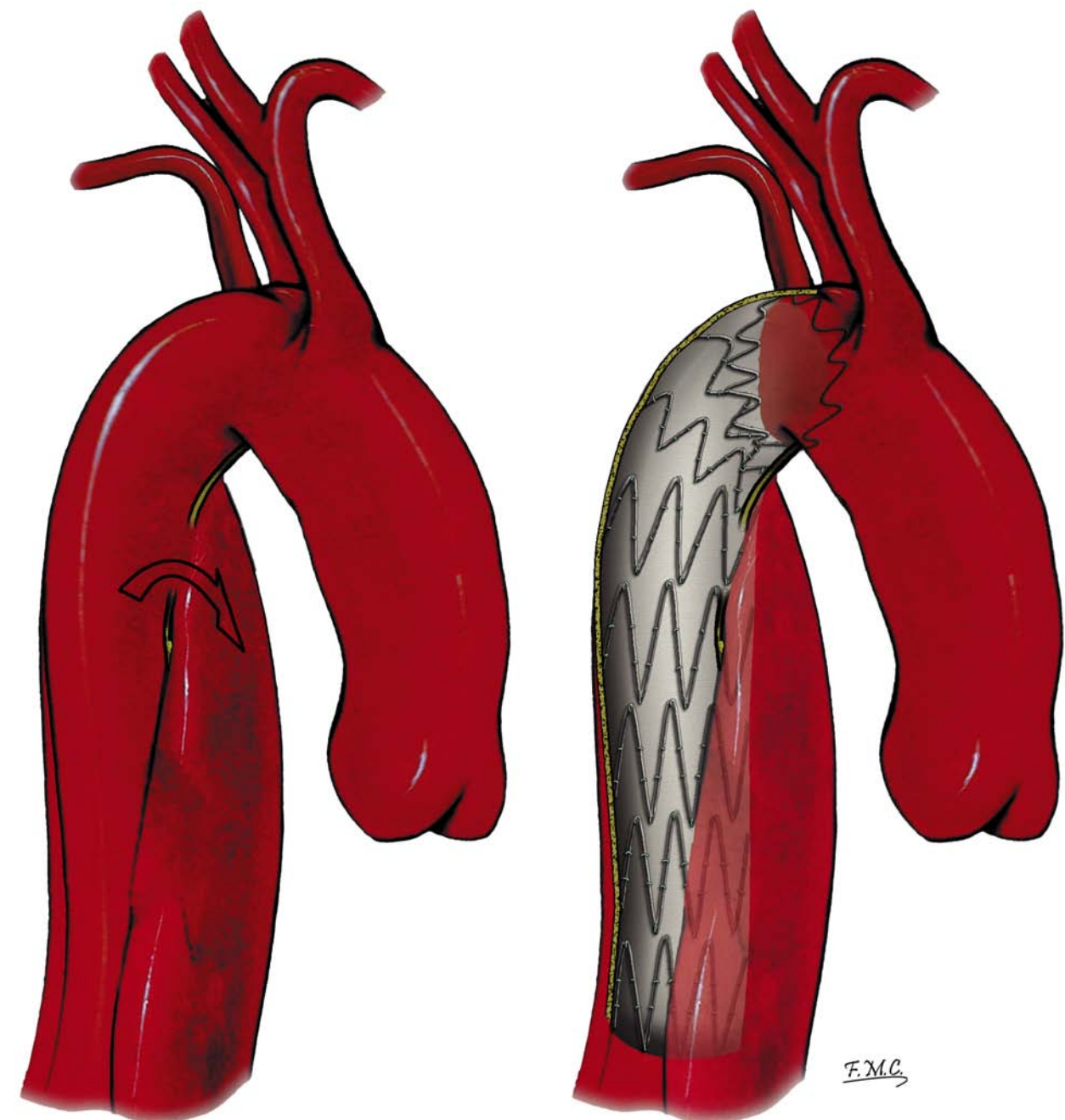
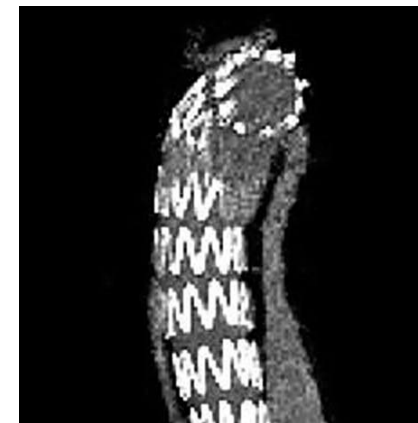
The requirements for an aortic stent graft suitable for acute type B dissection are somewhat different from the requirements for aneurysm exclusion. Migration is unlikely within the compressed true lumen because the stentgraft is supported along its entire course by firm apposition to the dissection membrane and the aortic wall.

The dissecting aorta is, however, frail and the stentgraft needs to be soft and compliant in order to avoid erosion of the aortic wall or perforation of the dissection membrane. Rigid stentgrafts with uncovered or barbed stents for fixation may cause iatrogenic perforation, retrograde dissection or additional re-entry sites. Unprovoked ballooning of the aortic stentgraft in a type B dissection must be avoided for the same reason. Proximally, the stentgraft is implanted into the non-dissected portion of the aortic arch between the left subclavian and carotid arteries unless contraindications are present.

Complications from acute type B dissection involve a) aortic rupture, b) end organ ischemia, c) hypertension, d) persistent pain and e) progression of the dissection distally along the aorta and its branches or retrograde direction into the arch beyond the left subclavian artery. All of these complications, may potentially be treated by an aortic stent graft. The rationale for this treatment is to cover the main (usually the most proximal) entry site. The aortic flow of blood is thereby directed into the true lumen and the false lumen becomes depressurised. This will usually suffice to prevent further hemorrhage in cases of rupture in spite of the fact that, by definition, persisting distal reentries provide type I endoleakage. It seems that a proximal seal is what matters. A successful proximal seal will thrombose the false lumen and prevent further aortic dilation down to the level of the diaphragme in most cases according to a recent Swedish national survey. The bronchial arteries that originate near the arch may occasionally maintain false lumen perfusion and need in that case to be embolised.

There has been some concern that visceral arteries originating from the false lumen may not always be revascularised by the aortic stent graft alone. Completion angiography to confirm perfusion of the visceral and lower limb vessels is warranted. It is noteworthy, however, that even those branches that originate from the false lumen, usually can be catheterised from the aortic true lumen without too much effort. Adequate flow may then be reconstituted instantly by stenting.

In conclusion, aortic stentgrafts improve dramatically the dismay results of open surgery in patients with complicated type B dissection.





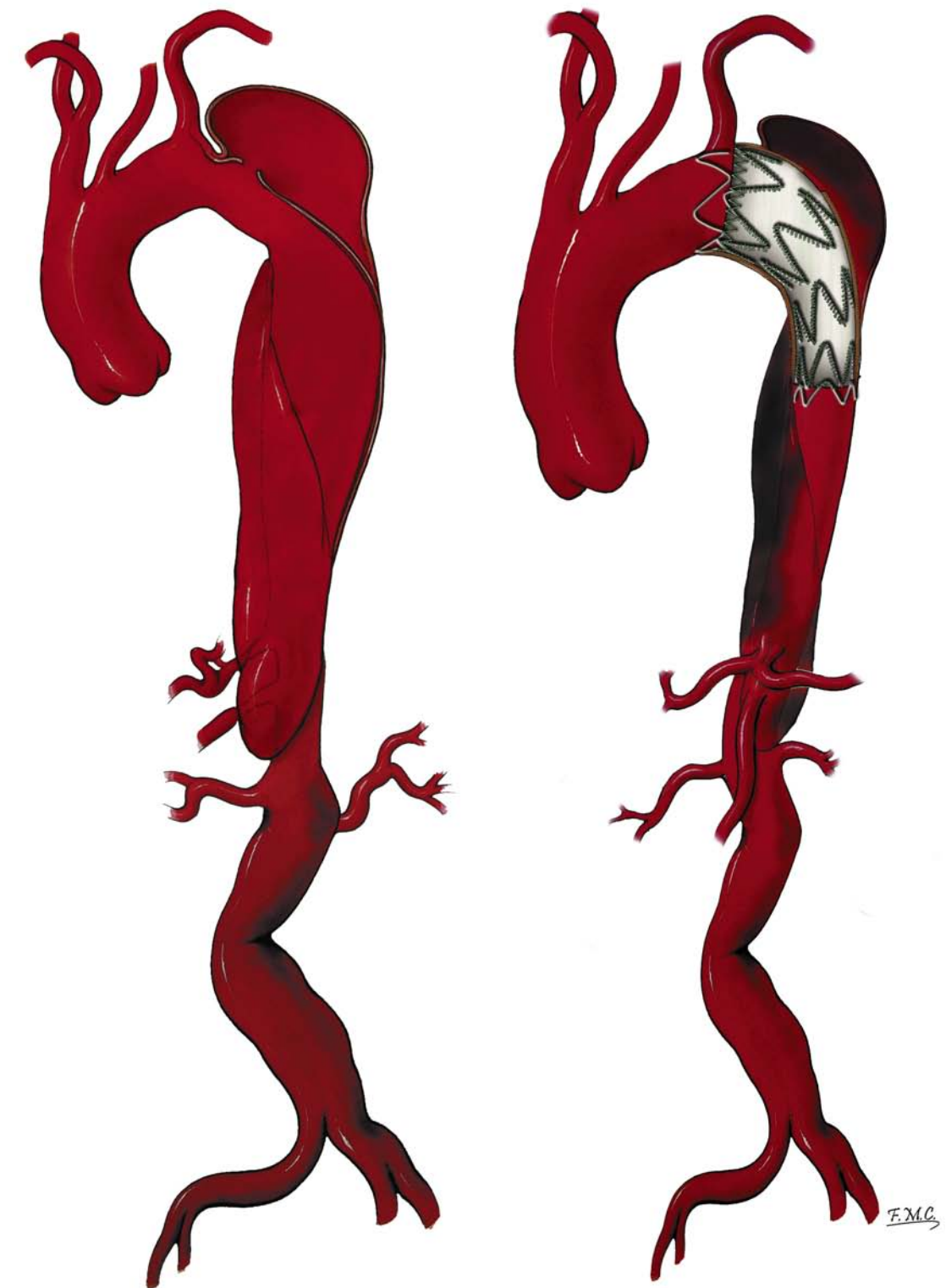
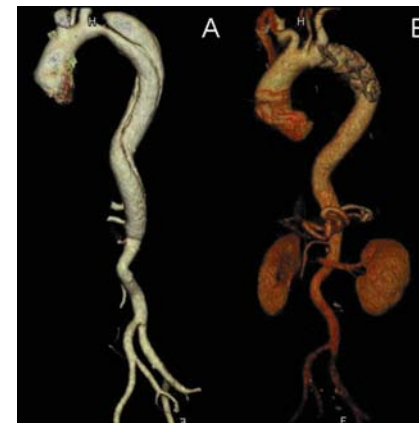# ENDOVASCULAR TREATMENT OF CHRONIC TYPE B AORTIC DISSECTION

**Rossella Fattori**

*S. Orsola-Malpighi Hospital, University of Bologna - Italy*

The optimal management of descending aortic dissection is controversial. Even though medical therapy demonstrated some early survival benefit with respect to surgical repair, no significant difference in long term outcome has been demonstrated.

Mortality is related either to retrograde progression of dissection with involvement of the proximal aorta or to expansion of the false lumen and formation of a thoracic aneurysm. Several reports in the literature analysed long-term outcome in patients with type B dissection, comparing medical with surgical therapy without evidence of a significant difference between the two groups. Five-year survival rates between 32%-72% have been reported because medical therapy alone cannot prevent the evolutive course of the disease. Recently, the development of endovascular therapy offers additional opportunity in the treatment of type B dissection as potential alternative to medical therapy and open surgical repair. The rationale of endovascular treatment of aortic dissection was originally based on evidence in the literature of protective effect of false lumen thrombosis against false lumen expansion and on the clinical observation that patients in the rare instance of spontaneous thrombosis of the false lumen have a better long-term prognosis than without it. Conversely, persistent perfusion of the false lumen has been identified as an independent predictor of progressive aortic enlargement and adverse long-term outcome. Closure of the entry tear of a type B dissection may promote both depressurisation and shrinkage of the false lumen, with subsequent thrombosis, fibrous transformation, remodelling and stabilization of the aorta. Published data confirm the technical feasibility and a relative low rate of complications with respect to surgical repair. However long-term follow-up and outcome information, in order to document the sustained benefit of endovascular repair, are still limited. With growing experience in endovascular stent-graft treatment, the spectrum of acute and midterm complications has broadened to include potentially disastrous events. Late aneurismal degeneration of the thrombosed false lumen has been reported, and also several case reports have highlighted the risk of retrograde extension of the dissection into the ascending aorta, potentially caused by stent-graft induced intimal injury. Even though extension of dissection is known event in the course of type B dissection disease, wire or sheath manipulation during the endovascular procedure could increase the risk of this dreadful complication. Continuous progress in stent-graft technology, improving morphology and flexibility, may lead to more suitable stent-graft configuration for aortic dissection. However, these unexpected complications underline the particular fragility of the aortic wall and the need of careful selection criteria and rigorous follow-up. Before the responses of controlled randomized trials it will be difficult to provide certainties on which is the best timing and treatment modality with respect to acute and chronic forms.



# TYPE I THORACO-ABDOMINAL AORTIC ANEURYSM IN CHRONIC TYPE B DISSECTION: OPEN REPAIR USING COSELLI PROSTHESIS - CASE REPORT

**Attilio Odero**

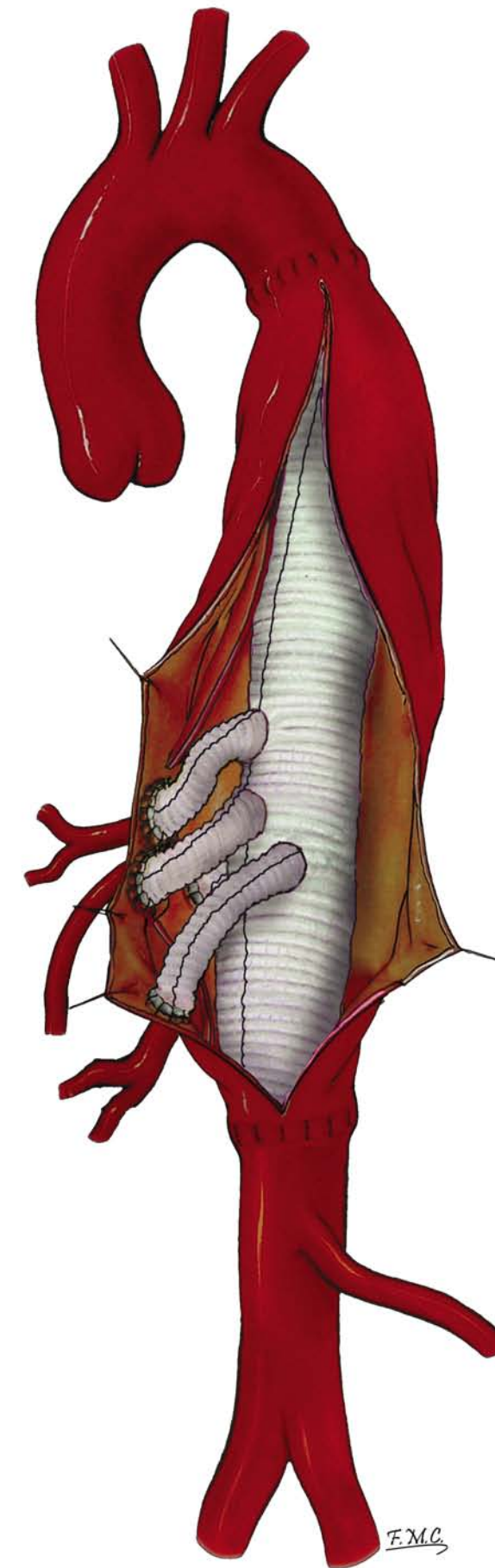
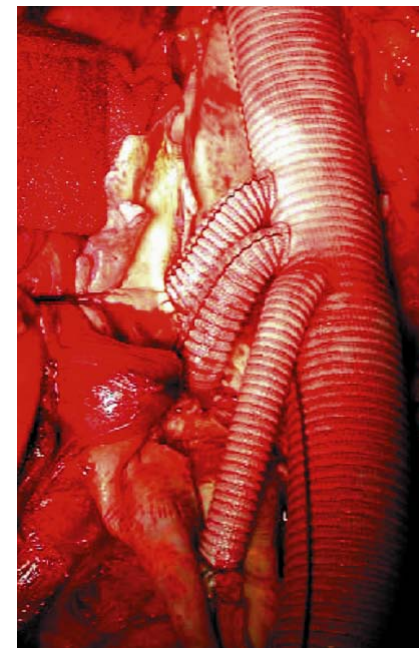
*IRCCS S. Matteo General Hospital, University of Pavia - Italy*

A. Odero, V. Arici, A. Bozzani, M. Lovotti, G. Bonalumi

**Introduction:** Incidence of thoracic and thoraco-abdominal aortic aneurysms was around 0.5% in autoptic series (Kouchoukos et al. Nejm 1997). Despite several improvements achieved in the last years, surgical repair of thoraco-abdominal aneurysms today still shows, even in specialized centers, high perioperative morbidity and mortality rates and middle and long term complications. An important concern is about complications of the visceral vessel aortic patch using the Crawford inclusion technique. Frequent complications are anastomotic pseudoaneurysms, aneurismal expansion and visceral vessel stenosis or occlusion caused by atherosclerosis progression. Introduction of a new four side branched aortic graft, developed by Coselli (Gelweave Coselli Thoracoabdominal Graft™-Vascutek-Terumo, Newmains Avenue Inchinnan Renfrewshire PA4 9RR Scotland UK), offers the perspective to decrease the complication rate. We describe a case of a post-dissection type I thoraco-abdominal aortic aneurysm repaired using the Coselli graft.

**Case Report:** V.E.L., 67 years old male, was admitted at the vascular surgical department at IRCCS Policlinico S. Matteo, Pavia, in November 2003 for type B aortic dissection with proximal retrograde aortic arch and distal right external iliac artery involvement. He underwent immediate aortic arch repair with supra-aortic artery reimplantation, except left subclavian artery. During the follow-up the patient developed a type I thoraco-abdominal aortic aneurysm, with a maximum transverse diameter of 57 mm and an asymptomatic severe stenosis of the celiac trunk. In January 2006 the patient underwent a new open repair. Through classic left thoraco-abdominal access with phrenotomy the aorta was exposed from the isthmus and distally to the inferior mesenteric artery. The Coselli graft was anastomosed in both ends with the aorta. Visceral vessels (left and right renal arteries, superior mesenteric artery and the celiac trunk) were separately anastomosed with the side branches of the prosthesis. During the operation distal aortic perfusion was upheld by femoral-femoral partial cardio-pulmonary by-pass, the cerebrospinal fluid was monitored and drained, and pulmonary pressure was measured by Swan-Ganz catheter. Postoperative course was without complications and the patient was discharged to home on the eleventh postoperative day. Five months later spiral CT showed patency of the reconstruction without any complications.

**Discussion:** Aneurysmal expansion of the visceral patch after thoraco-abdominal-aortic replacement using Crawford inclusion technique occurs at a rate of 7.5% (Dardik et al. J. Vasc. Surg. 2001), with consequent severe surgical repair problems. The use of a side branched, ready made, aortic graft offers an interesting possibility to reduce the incidence of anastomotic pseudoaneurysms and the progression of atherosclerotic damage of the visceral vessels since it often starts at their origin. Separate visceral trunk revascularisation, that doesn't require a longer time of organ ischemia, avoids the use of an atherosclerotic aortic patch and allows the revascularization of the visceral vessels far from the main site of the disease. The following possibilities of complications are by this method isolated to only involve one branch at the time. It seems like that the wide use of the Coselli graft is in order, even if, of course, its newness apply for a long term follow up.





# ACUTE AORTIC SYNDROME

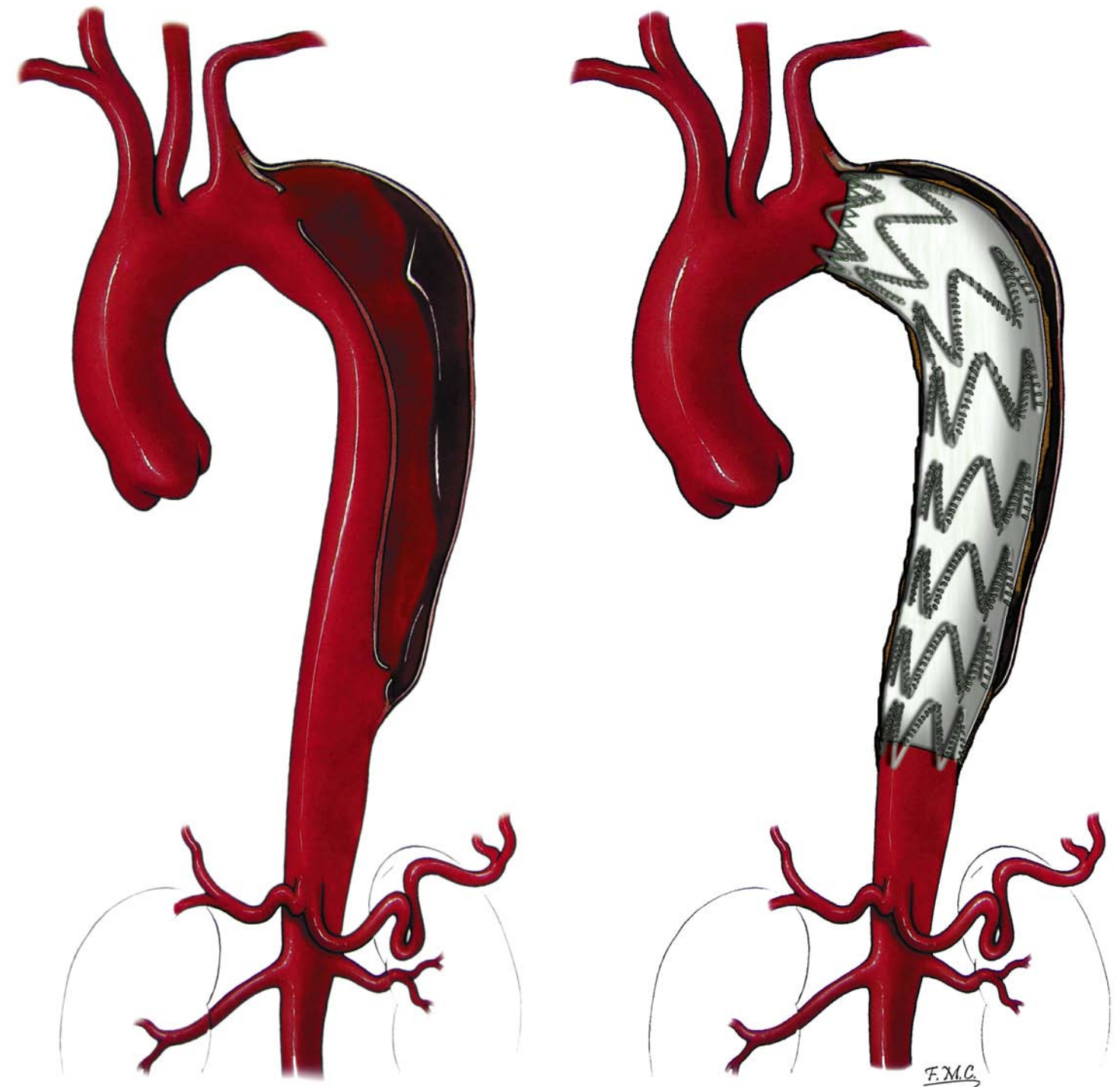
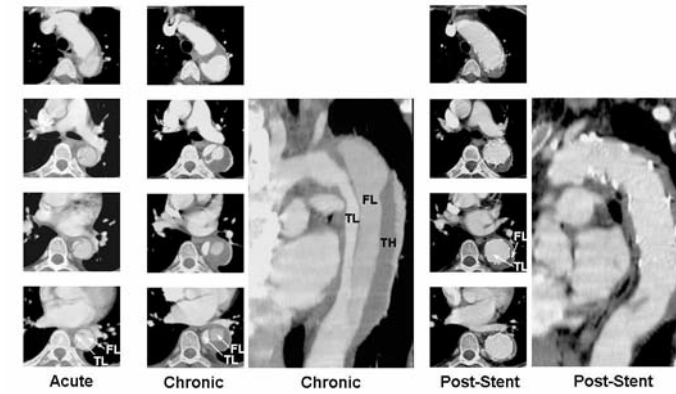
Christoph A. Nienaber

University Hospital Rostock - Germany

Elective endovascular repair of the thoracic aorta has shown reduced morbidity and mortality when compared with open surgery. The overall experience with various diagnostic approaches to acute aortic syndrome and new therapeutic methods, including the use of thoracic endovascular stent-grafts for acute pathology is increasing. Since 1998 more than 1,000 patients underwent endovascular stent-graft treatment for various types of acute aortic syndrome in the published literature, including complicated Stanford type B dissection, ruptured descending aorta aneurysms, intramural hematoma, traumatic rupture of the thoracic aorta, aortopulmonary fistula and penetrating aortic ulcer. These acute thoracic aortic syndromes were predominantly localized in the proximal descending thoracic aorta (75%). Various types of stent-grafts are currently being used.

Technical success of stent-graft deployment at the intended position is achieved in 95-97% of cases and periinterventional death is low (~5%), while hospital mortality ranges around 20% in acute aortic syndrome cases. Death rate seems to be related to the severity of disease and is higher with a compromised clinical status including malperfusion syndrome, extensive bowel ischemia and irreversible cerebral damage after resuscitation. Neurologic symptoms usually improve during hospital stay or may persisting in ~20%. Once the hospital stay is survived, patients usually are alive at one year follow-up, but new events related to comorbidity may occur. During follow-up, transposition of the left subclavian artery for malperfusion, or a second stent-graft procedure for endoleak are rare events.

The diagnosis of acute aortic syndrome is facilitated with undelayed rapid access to tomographic imaging such as CT or TEE (transesophageal echo) in the emergency department. Thoracic stent-grafting for acute aortic syndromes is feasible both in stable and in critically ill patients. Postinterventional morbidity and mortality is related to the general state of health and to the compromised preoperative clinical status, and should be factored into prognostic expectations.



# ENDOGRAFTS IN AORTIC RUPTURE

**Claudio Novali**  
*Santa Croce e Carle Hospital, Cuneo - Italy*

C. Novali, C. Rivellini, P. Scovazzi

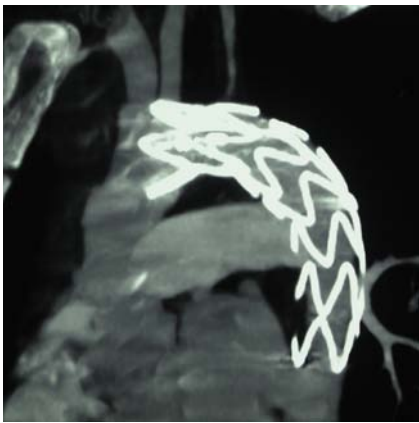
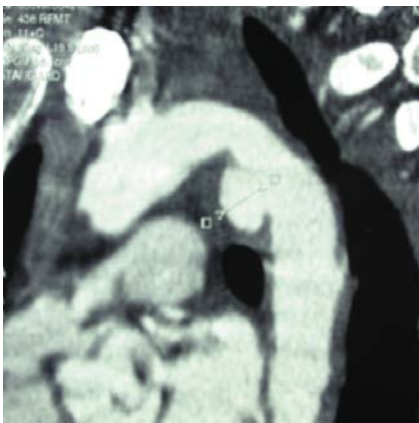
Introduction: Blunt traumatic thoracic aortic rupture is a life-threatening surgical emergency associated with high mortality and morbidity. The recent development of endovascular stent-graft prostheses offers a potentially less invasive alternative to open chest surgery, especially in patients with associated injuries (thoracic lesions in 66% of patients, orthopedic injuries in 78%, abdominal lesions in 27%, head injuries in 23%). We studied the feasibility and safety of endovascular stent graft placement for treatment of acute traumatic aortic rupture

Methods: Between 2003 and 2006 9 patients were treated emergently for acute blunt traumatic aortic rupture. All patients had a lesion limited to the isthmus, and associated injuries. Initial management included fluid resuscitation, treatment of other severe associated lesions and strict monitoring of blood pressure. Preoperative workup included chest computed tomography scan in all patients, transesophageal echography and angiography only if possible or necessary.

For endovascular treatment the devices used were the Zenith and Talent stent-graft.

Results: Stent graft placement successfully sealed the aorta in all patients with not conversion to open repair. In 3 patients the left subclavian artery and left carotid artery in 1 patient was intentionally covered with the device. The delay between trauma and endovascular treatment was 7 (range 1-18) days. No patient in this group had paraplegia. No patient died and no procedure complications occurred in this group. Lesions located at distal aortic arch may request a hybrid surgical repair, in order to preserve the perfusion of left carotid artery.

Discussion: Endovascular treatment of thoracic aortic rupture is a safe, effective and timely treatment option. Improvement of patient outcome can be achieved by delayng surgical repair until after management of major associated injuries if there are no signs of impending rupture.







'06

SCIENTIFIC ABSTRACTS

SESSION III - Aortic Arch

<i>President:</i>	G. Raimondo Pistolese
<i>Chairmen:</i>	Paolo Biglioli, Joseph S. Coselli
<i>Discussants:</i>	Luigi de Luca Tupputi Schinosa, Maurizio Puttini, Vincenzo Rampoldi
ASCENDING AORTA ENDOVASCULAR REPAIR	Roy K. Greenberg
CEREBRAL PROTECTION DURING AORTIC ARCH SURGERY	Lucia Torracca
OPEN SURGERY OF THE AORTIC ARCH	Roberto Di Bartolomeo
HYBRID PROCEDURES FOR AORTIC ARCH ANEURYSMS: MARSEILLE EXPERIENCE	Patrice Bergeron
RESULTS OF ENDOGRAFTING OF THE AORTIC ARCH IN DIFFERENT LANDING ZONES	Roberto Chiesa
ENDOVASCULAR REPAIR OF ANEURYSMS INVOLVING THE PROXIMAL AORTIC ARCH	Timothy A.M. Chuter

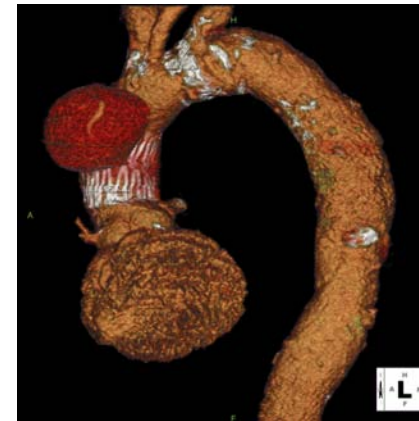# ASCENDING AORTA ENDOVASCULAR REPAIR

**Roy K. Greenberg**

*Cleveland Clinic Foundation - OH - USA*

The ascending aorta poses several challenges to repair with endovascular grafting. The proximity of the coronary arteries and aortic valve, the relatively larger aortic dimensions, and the inherent 270 degree tortuosity of the aortic arch hinder the simple extrapolation of endovascular repair of more distal aortic pathology to the ascending aorta. In this light, several adjuncts have allowed for the treatment of some types of ascending aortic aneurysms to be treated. Specifically, the incorporation of:

- 1) delivery system modifications
- 2) the ability to stop antegrade cardiac flow indefinitely during device deployment
- 3) techniques for crossing the aortic valve
- 4) catheter and wire manipulation within the left ventricle
- 5) the assessment of valvular cardiac function intraprocedurally have helped to make such repairs possible. The video presentation will highlight these techniques.





# CEREBRAL PROTECTION DURING AORTIC ARCH SURGERY

Lucia Torracca

*San Raffaele Scientific Institute, Milano - Italy*

The evolution of the ascending aorta and arch surgery raised the problem of cerebral protection during periods of interruption of the physiological antegrade blood flow.

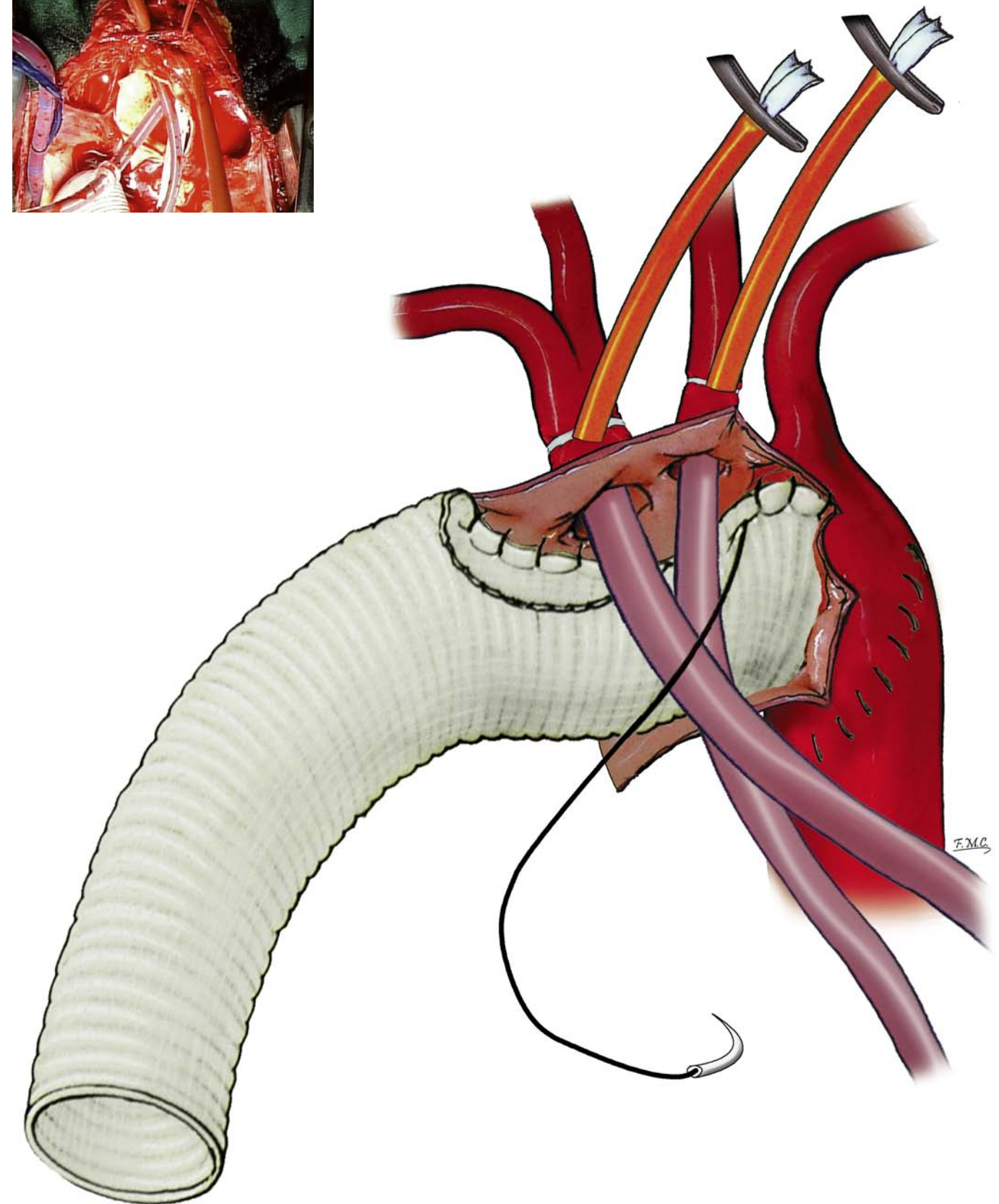
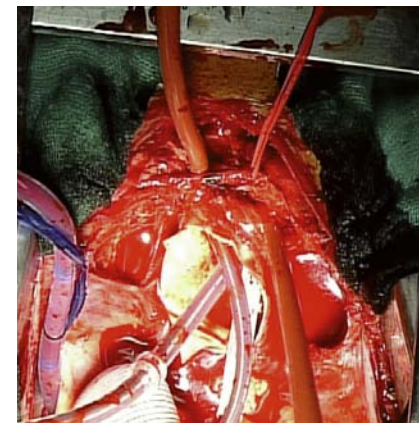
Brain damage can be due to global hypoperfusion secondary to interruption of the flow in the arch vessels or to embolization of particulate material during surgery.

Three different surgical techniques are currently used for cerebral protection. The hypothermic circulatory arrest (HCA) was introduced at the beginning of open heart surgery as an alternative to extracorporeal circulation and then extensively applied to aortic arch surgery. The mechanism of cerebral protection during HCA is a metabolic suppression induced by hypothermia. Recent human studies have quantified the metabolic suppression achieved by hypothermia and have predicted a safe duration of HCA of 29 minutes at 15°C. Some technical details in establishing HCA are important. Cooling of the patients might be done with a perfusate at 10°C for a minimum of 30 minutes. Head packing is mandatory for preventing the rising of brain temperature during the arrest time. The cerebral metabolic rate can be evaluated using jugular venous saturation, EEG monitoring or sensory or auditory evoked potentials. Slow rewarming with a gradient less than 10°C between the blood and the body temperature appears to be important. At the end of rewarming blood temperature should not exceed 36.5°C and oxygen delivery might be guaranteed by stable hemodynamic condition and good hematocrit. The retrograde cerebral perfusion (RCP) has been introduced to overcome the limitation of HCA. Its rationale was based on the possibility to flush embolic material from the cerebral circulation, to provide an adequate flow for cerebral metabolism and to maintain brain hypothermia.

Clinical results with RCP are discordant and no advantages seem to be clearly demonstrated over the use of HCA. Currently its clinical role is limited to the treatment of massive intraoperative accidental air embolism.

Antegrade selective cerebral perfusion (SCP) is today the preferred technique for cerebral protection during the circulatory arrest. Different technical issues and protocols are clinically used for antegrade cerebral perfusion. Vessels cannulation can involve all the three arch vessels or only the innominate and the left carotid artery with subclavian artery occlusion. Cannulation can be direct with the advantage to be easy and quick, but it can be obtain also by interposition of a composite graft to reduce the risk of embolization. Monitoring of cerebral perfusion can be done by pressure but information about regional perfusion can be obtain only by near-infrared spectroscopy or trans cranial Doppler of the middle cerebral artery. Also perfusion protocols are not homogeneous. A perfusion flow of 10ml/kg/min at 22°C or a pressure of 50-70 mmHg are suggested in different clinical experience. The use of antegrade selective cerebral perfusion can also offer the possibility to reduce the degree of cooling with a positive impact on the operative and extracorporeal circulation time and a global advantage in terms of coagulation.

A significant impact on cerebral protection has been introduced by axillary artery cannulation that allows arterial perfusion during extracorporeal circulation and antegrade selective cerebral perfusion during the arrest time. Despite all this technical improvements brain damage still remain a potential serious complication of the aortic arch surgery and further studies are mandatory to improve clinical results.



# OPEN SURGERY OF THE AORTIC ARCH

**Roberto Di Bartolomeo**

*S. Orsola-Malpighi Hospital, University of Bologna - Italy*

R. Di Bartolomeo, D. Pacini

During the last decade, surgery of the thoracic aorta has increased substantially because of a growing incidence of aortic pathologies, mainly due to more accurate diagnoses and, also because of a wider spectrum of surgical indications. Even if patient outcome has improved considerably, this surgery is still associated with significant morbidity and mortality especially due to neurological complications. Neurologic injuries are the most feared complications resulting from suspension of cerebral circulation. To prevent these complications, various methods have been widely used.

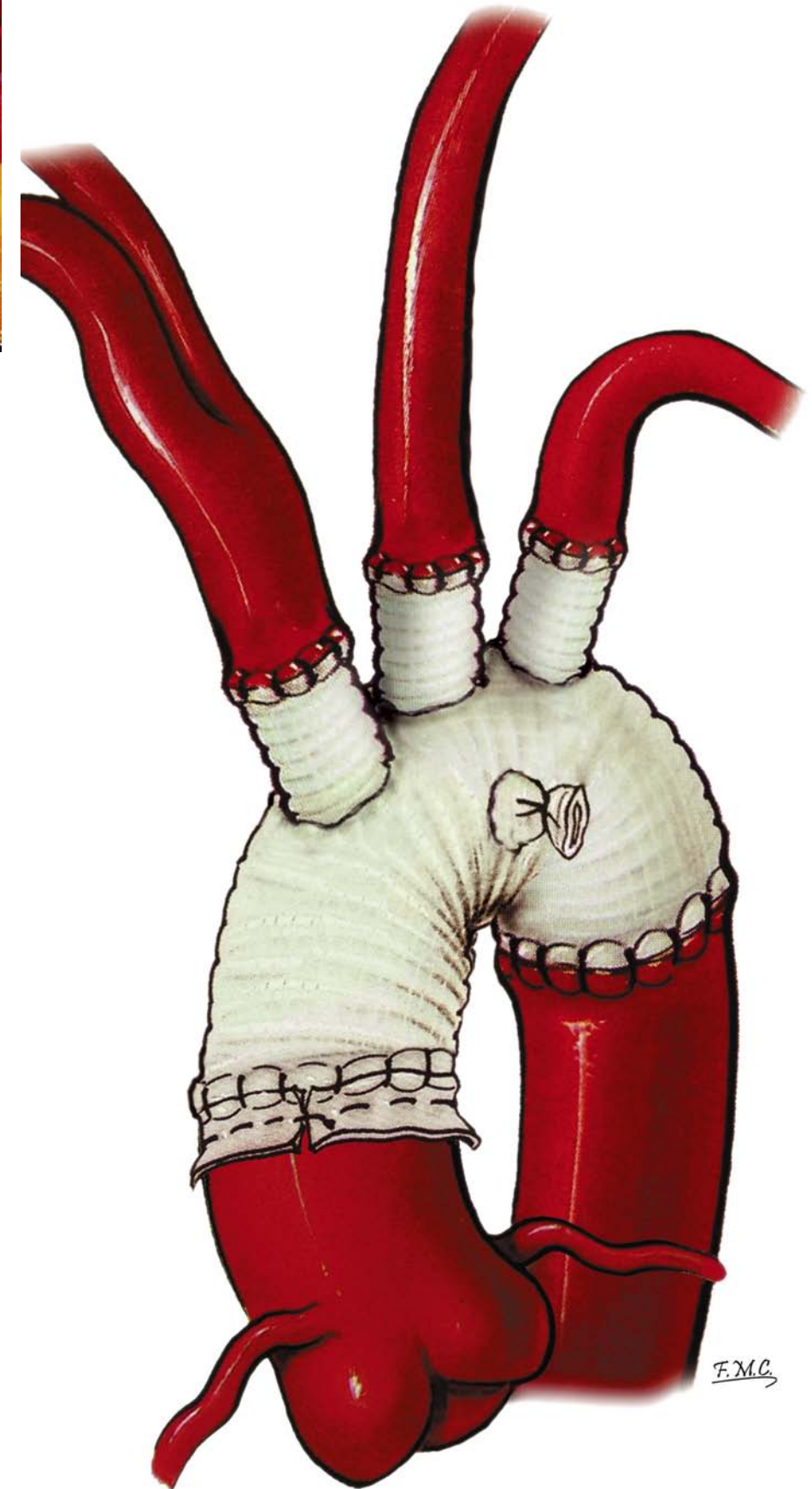
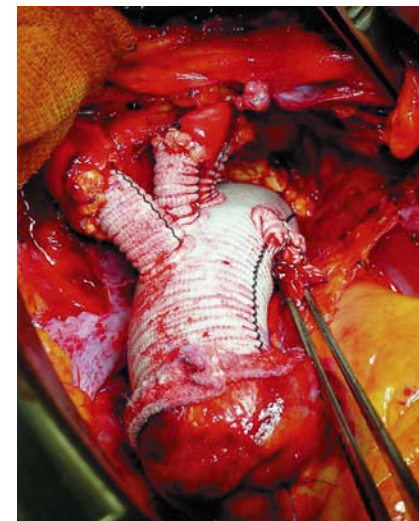
Deep Hypothermia with Circulatory Arrest (DHCA), used in our Institution during aortic arch operations since 1974, is a simple and valid method. This technique presents the disadvantage of a limited "safe time" of circulatory arrest (< 40 minutes at 18°C): in fact incidence of stroke and mortality rate increase for a circulatory arrest time of longer than 45 and 60 minutes respectively. With this technique the incidence of cerebral complications ranged from 7% to 10% (2-4). In our experience permanent neurologic deficit occurred in 5.4% and transient neurologic dysfunction in 6.7%. Furthermore, prolonged CPB time, required to cool and rewarm the patients, increase the risk of coagulative deficits, pulmonary complications and microembolisms.

Retrograde cerebral perfusion associated with DHCA was introduced to prolong the "safe period" of circulatory arrest and good results have been reported even though the mechanisms of the protective effect are not entirely understood. However, this technique does not avoid the problems associated with DHCA. We have had very limited experience with this technique and the results were similar to those obtained with DHCA.

Since November 1996, we have been using Selective Cerebral Perfusion (SCP), as described by Kazui, with very encouraging results. This technique provides moderate hypothermia (26°C), which, at the same time, reduces the problems due to deep hypothermia and prevents ischemic injuries of the abdominal viscera and of the spinal cord. Cerebral perfusion is obtained cannulating the innominate and left common carotid arteries and regulated by a single roller pump separated from systemic circulation. The blood is perfused at the rate of 10 ml/kg per minute.

SCP has considerably prolonged the "safe time" of circulatory arrest allowing more complex and time-consuming aortic arch reconstruction.

In our experience we have seen that with this technique it is possible to treat also diffuse aneurysmal disease of the thoracic aorta (arch, ascending and descending aorta) using only an anterior approach (median sternotomy). Occasionally an additional left anterior thoracotomy at the fourth intercostal space may be necessary to improve the exposure in case of a particular thorax conformation; involvement of the aorta until the diaphragmatic iatus or in case of reoperation with firm pleuric adhesions.





# HYBRID PROCEDURES FOR AORTIC ARCH ANEURYSMS: MARSEILLE EXPERIENCE

**Patrice Bergeron**

*Saint Joseph Hospital, Marseille - France*

P. Bergeron, V. Piret, P. Coulon, M. Boukhris, G. Tshiombo, J. Gay

**Purpose:** We present our experience of the hybrid management of thoracic aortic aneurysms (TAA) involving the aortic arch in high risk patients (HRP) with mid-term results.

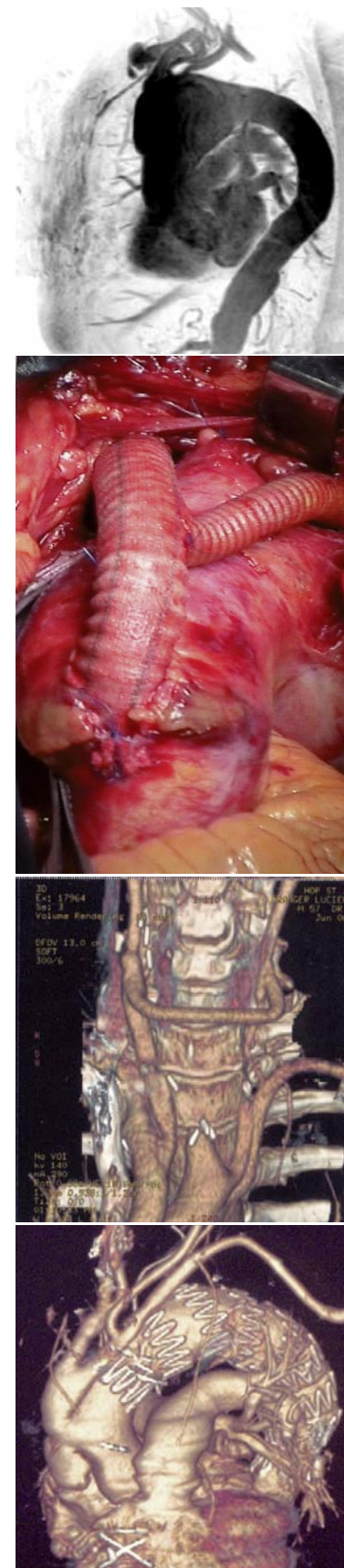
**Methods:** From May 1999 to May 2006, we treated 81 patients with thoracic aortic endografts, of who 32 required hybrid interventions for aortic diseases involving the arch. Seventeen patients were treated for aortic arch aneurysm and a hemi-arch transposition was required in 6 and a total arch transposition in 11.

**Results:** The early death rate amongst 17 patients who received the complete hybrid treatment was 11.7%: we encountered two catheter-related deaths, from iliac rupture in one male patient and from left ventricle perforation in one female patient. We had no early neurological adverse events except one case of unilateral reversible lower limb deficit. We observed 2 cases of ischemia of the left upper limb, which were treated by carotido-subclavian bypass in one case and subclavian artery stenting in the second case.

During a mean follow-up of 19.8+/-17.6 months, we had 2 deaths at 1 and 3 months from cardiac and respiratory failure respectively. The mid-term survival rate was 13/17=76.5%.

One type 2 endoleak from a patent left subclavian artery was treated by coil embolization. No other endoleaks were observed during the follow-up of these patients. No stent related adverse event were reported. All aneurysmal sacs were excluded.

**Conclusions:** HRP suffering from aortic arch aneurysms may benefit from the staged hybrid surgical & endovascular strategy. Aortic endografting after surgical transposition is a challenging feasible technique that offers good mid-term results, and accessible to non cardiac surgeons. Catheterisation maneuvers must be carefully driven in order to avoid fatal complications.



# RESULTS OF ENDOGRAFTING OF THE AORTIC ARCH IN DIFFERENT LANDING ZONES

**Roberto Chiesa**

*Vita-Salute San Raffaele University, Milano - Italy*

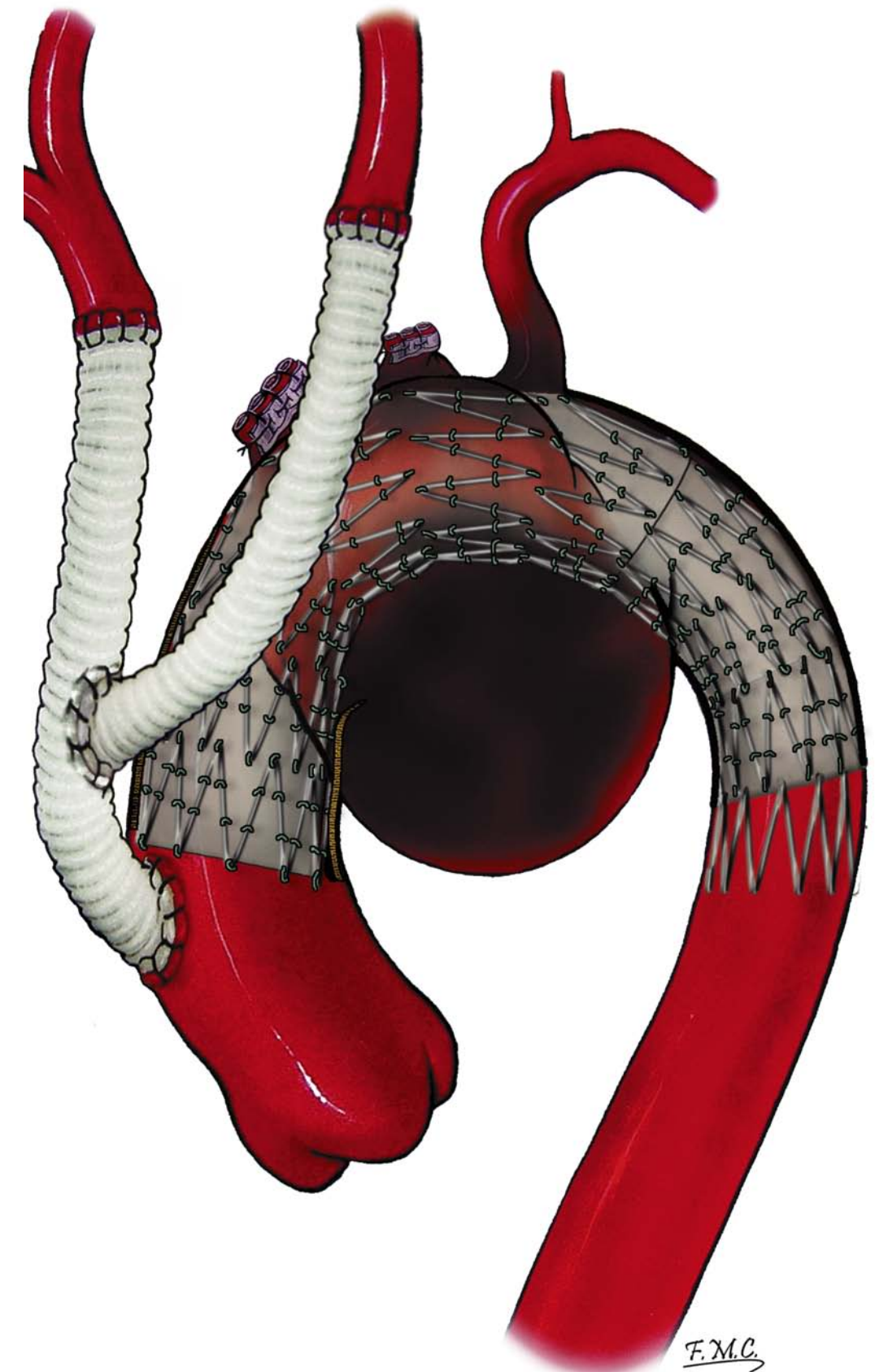
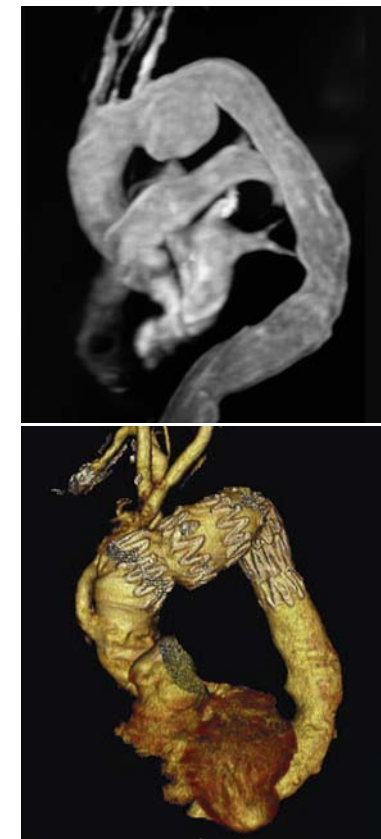G. Melissano, E. Civilini, L. Bertoglio, F.M. Calliari, F. Setacci, R. Chiesa

**Introduction:** Endovascular approach to the aortic arch is an appealing solution for selected patients. Aim of this study is to compare the technical and clinical success recorded in the different anatomical settings of endografting for aortic arch disease.

**Methods:** Between June 1999 and June 2006, among 161 patients treated at our Institution for thoracic aorta disease with a stent-graft, the aortic arch was involved in 56 cases. According to the classification proposed by Ishimaru, aortic “zone 0” was involved in 11 cases, “zone 1” in 11 cases and “zone 2” in 34 cases. A hybrid surgical procedure of supraortic debranching and revascularization was performed in 31 cases to obtain an adequate proximal aortic landing zone.

**Results:** “Zone 0”. Proximal neck length:  $43 \pm 6$  mm. Initial clinical success 72.7%: 2 deaths (stroke), 1 type Ia endoleak. At a mean follow-up of  $15.3 \pm 10$  months the midterm clinical success was 81.8% “Zone 1”. Proximal neck length:  $28 \pm 5$  mm. Initial clinical success 63.6%: 0 deaths, 4 type Ia endoleaks. At a mean follow-up of  $16.5 \pm 16.8$  months the midterm clinical success was 72.7% “Zone 2”. Proximal neck length:  $30 \pm 5$  mm. Initial clinical success 82.4%: 2 deaths (1 cardiac arrest, 1 multiorgan embolization), 3 type Ia endoleaks, 1 case of open conversion. Two cases of delayed transitory paraplegia were observed. At a mean follow-up of  $25.1 \pm 16.6$  months the midterm clinical success was 88.2%

**Conclusions:** Total debranching of the arch for “zone 0” aneurysms allowed to obtain a longer proximal aortic landing zone with lower incidence of endoleak, however a higher risk of cerebrovascular accident was observed. The relatively high incidence of adverse events in “zone 1” could be associated to a shorter proximal neck, therefore this landing zone is reserved for patients unfit for sternotomy. In case of a low flow endoleak, discovered after a satisfactorily positioned endograft in the arch, the rate of spontaneous resolution within the first 6 months is high.



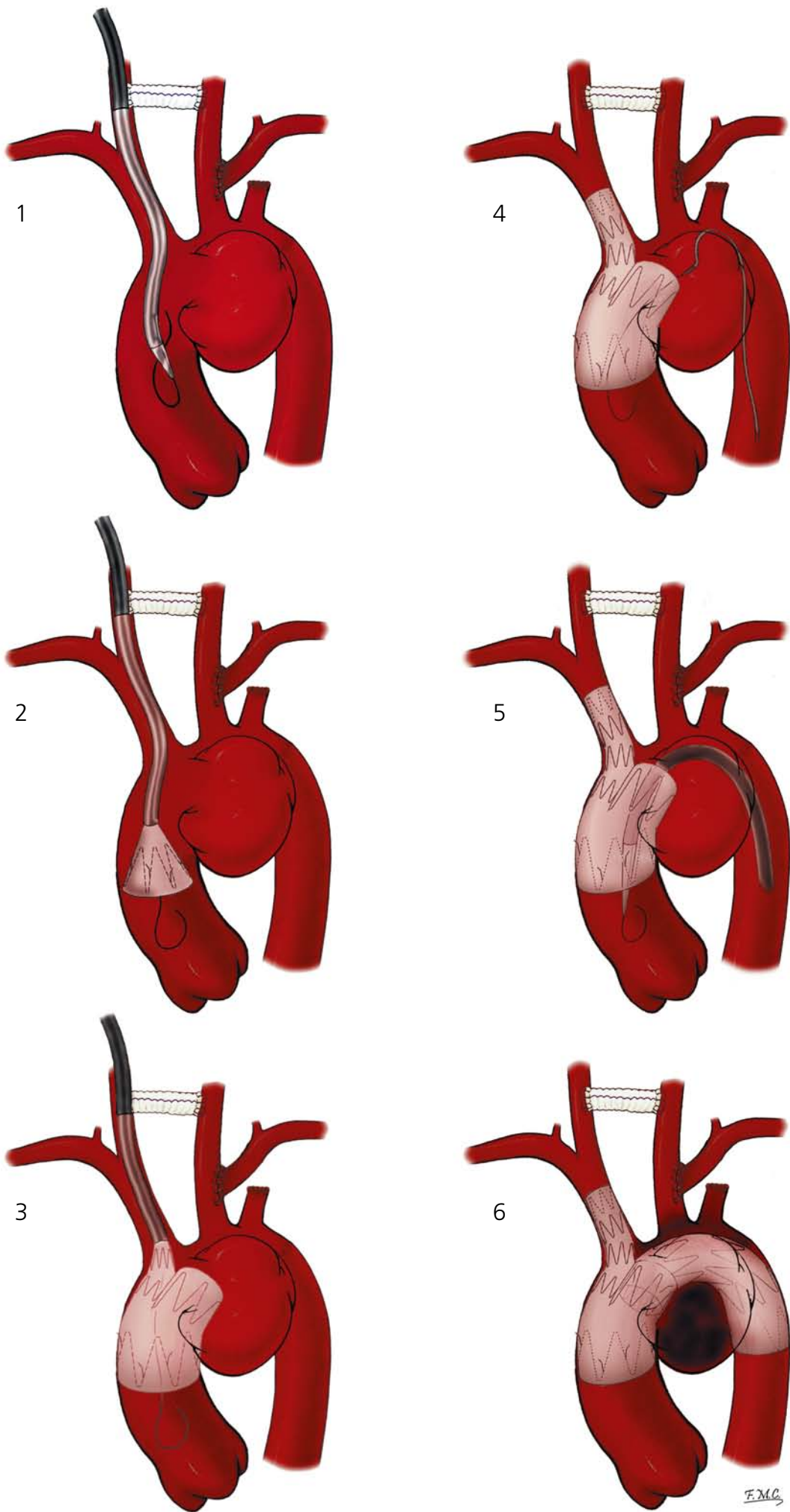


# ENDOVASCULAR REPAIR OF ANEURYSMS INVOLVING THE PROXIMAL AORTIC ARCH

Timothy A.M. Chuter  
University of California San Francisco - USA

Options for aortic arch repair include: open surgery under hypothermic circulatory arrest, endovascular exclusion with bypass from the ascending aorta or femoral artery, branched stent-graft implantation, and combinations of the above. Each has particular advantages and disadvantages, but the most feared complication, stroke, is common to all. Open surgery arrests flow to the brain, and aortic clamping dislodges luminal debris, as does endovascular manipulation.

Our current approach was the product of in-vitro experiments using a perfused rubber model of the aortic arch. We use a bifurcated ascending aortic stent-graft to channel blood to the innominate artery for distribution to the brachiocephalic circulation through extracavitary bypass grafts, and to the descending thoracic aorta for distribution to the lower half of the body. By performing the surgical bypasses first, and deploying the stent-graft through the innominate artery, we keep endovascular manipulations to a minimum, while ensuring continuing cerebral perfusion. We deploy both components of the stent-graft during brief, self-limited periods of adenosine-induced cardiac arrest.





SCIENTIFIC ABSTRACTS

SESSION IV - The Thoraco-Abdominal Aorta

*President:* Giovanni Deriu  
*Chairmen:* Alain Branchereau, Jon Largiadèr  
*Discussants:* Xavier Barral, Giuseppe Bianchi, Guido Regina

ELECTIVE SURGICAL MANAGEMENT OF DESCENDING THORACIC AORTIC ANEURYSMS IN THE ENDOVASCULAR ERA	Edouard Kieffer
ENDOVASCULAR TREATMENT FOR DESCENDING THORACIC ANEURYSMS	Luigi Inglese
OPEN SURGERY FOR TYPE I AND II THORACOABDOMINAL AORTIC ANEURYSMS WITH THE BRANCHED COSELLI GRAFT	Joseph S. Coselli
HYBRID APPROACH TO THORACOABDOMINAL AORTIC ANEURYSMS IN PATIENTS WITH PRIOR AORTIC SURGERY	Germano Melissano
ENDOVASCULAR REPAIR OF THORACOABDOMINAL AORTIC ANEURYSMS	Timothy A.M. Chuter
ENDOVASCULAR TREATMENT OF THORACOABDOMINAL AORTIC ANEURYSMS WITH BRANCHED ENDOGRAFTS: CLEVELAND EXPERIENCE	Roy K. Greenberg

# ELECTIVE SURGICAL MANAGEMENT OF DESCENDING THORACIC AORTIC ANEURYSMS IN THE ENDOVASCULAR ERA

Edouard Kieffer

Department of Vascular Surgery, Pitié-Salpêtrière University Hospital, Paris - France

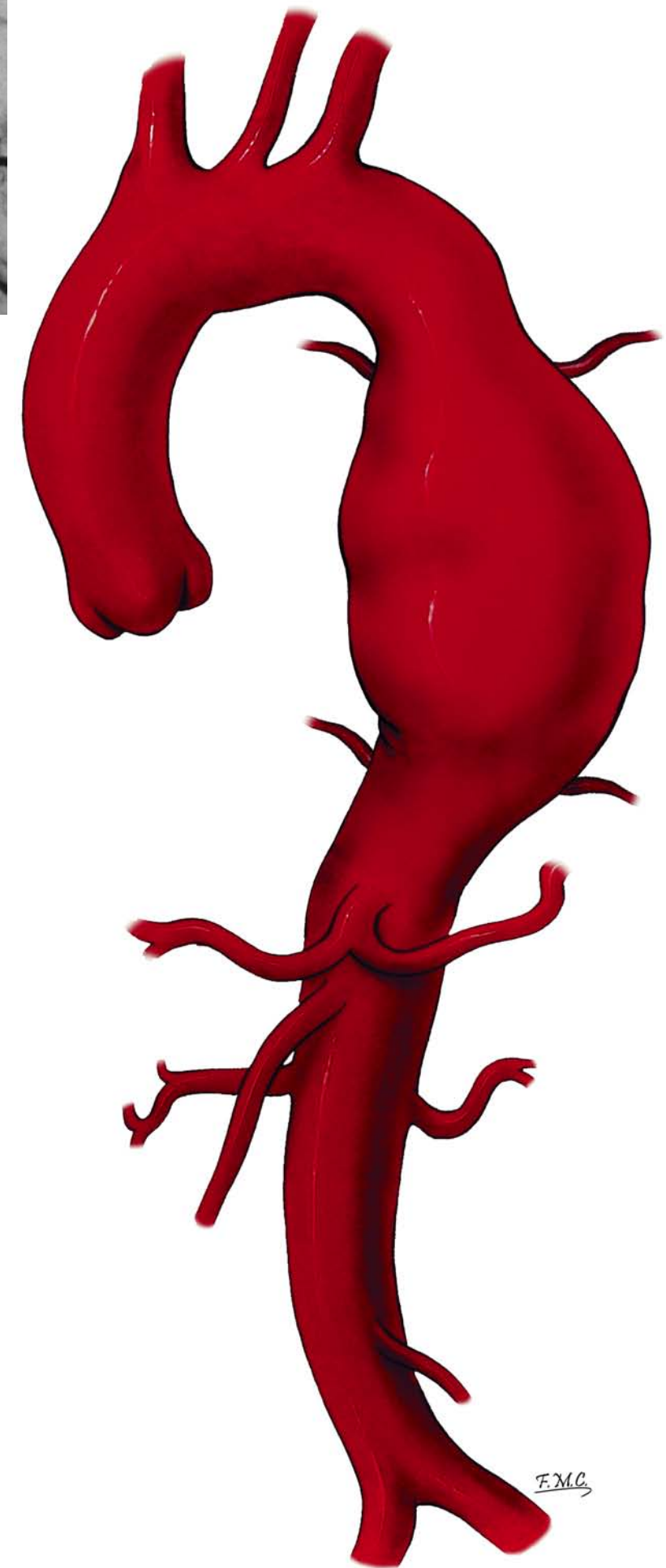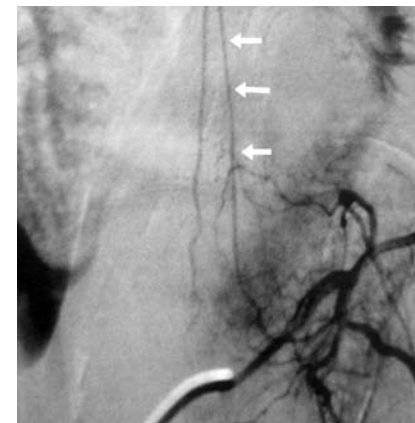
Despite the advent and success of endovascular procedures (that were initiated in our department in 1997), we feel that there is still room for open surgery in the management of descending thoracic aortic aneurysms.

For the last 10 years we have selected our elective patients for one technique or the other on the basis of (1) general fitness, (2) anatomy of aneurysm and (3) preoperative spinal cord arteriography. Poor risk patients with favourable anatomy and spinal cord arteries distant from the expected landing zone were offered endovascular treatment (group 1, 52 patients). Poor risk patients with unfavourable anatomy and/or spinal cord arteries arising from the landing zone and all good risk patients (due to uncertainties concerning the long-term results of endovascular treatment) were offered open surgery (group 2, 121 patients, including 77 good and 44 poor risk patients). Patients in group 1 were significantly older, had significantly more COPD and renal insufficiency and less aneurysms involving the entire descending thoracic aorta than patients in group 2. Surgical management involved the use of distal aortic perfusion with partial CPB in 78 patients and deep hypothermic circulatory arrest in 43 patients (these techniques will be described in detail during the presentation).

Postoperative mortality was 15.4% in group 1 vs 5% in group 2 ( $p < 0.02$ ). Paraplegia/paraparesia rate was 0 in group 1 versus 7.4% in group 2 ( $p = 0.04$ ). Stroke rate was 15.4% in group 1 vs 4.1% in group 2 ( $p = 0.01$ ).

While in group 2 the main cause of postoperative mortality (4/6 patients) was multiorgan failure, in group 1 it was technical problems (5/8 patients): perforation of left ventricle, perforation of the aorta, embolic stroke, acute migration and kinking of the stent-graft, retrograde aortic dissection. Postoperative cardiac complications rates did not differ significantly between the two groups. Respiratory and renal complications were significantly more frequent in group 2. Conversion rate was 3.8% in group 1.

We conclude that contemporary results of elective open surgery for descending thoracic aortic aneurysms are satisfying in terms of mortality. In our experience higher mortality rate of stent-grafting is explained by specific technical problems that have to be overcome if indications for stent-grafting are to be expanded. Higher spinal cord injury rate after open surgery is explained by selection of patients based on spinal cord arteriography. It is balanced by a significantly higher stroke rate after endovascular treatment.





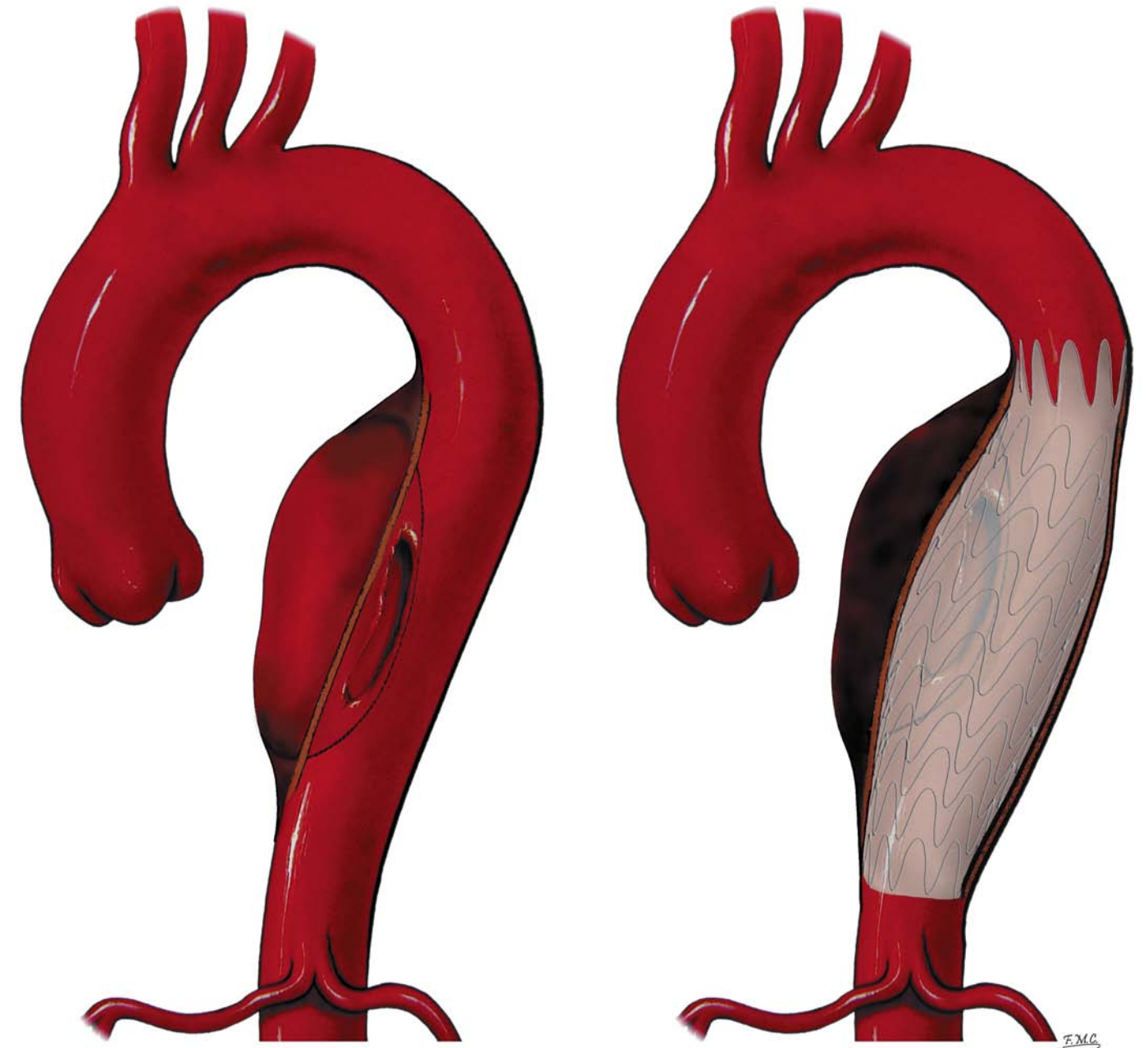
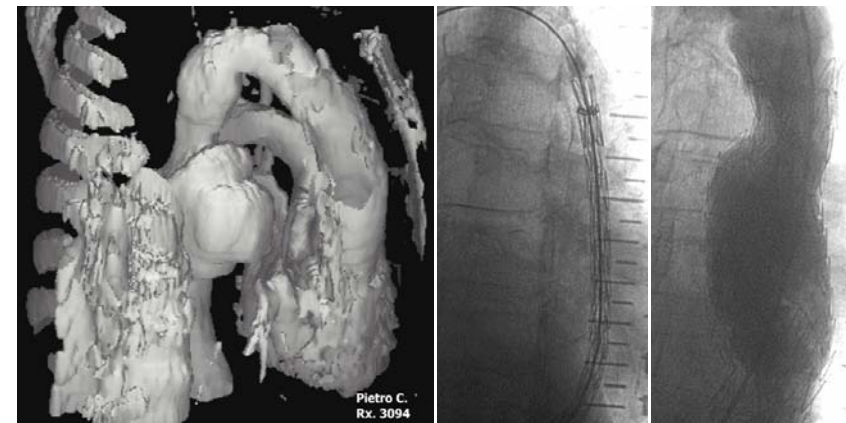
# ENDOVASCULAR TREATMENT FOR DESCENDING THORACIC ANEURYSMS

Luigi Inglese

I.R.C.C.S. Policlinic San Donato, Milano - Italy

Descending thoracic aorta is anatomically defined as the aortic segment distal to the left subclavian artery. Many diseases can affect it: mainly atherosclerotic in origin: aneurysms, penetrating aortic ulcers, intramural haematoma, traumatic ruptures (pseudo aneurysms) and communications between aorta and bronchial or esophageal cavities. Surgery has been the only therapy for these pathologies until the early 90' when endovascular grafts were first successfully implanted. Surgery of descending aorta although does not require extracorporeal circulation, implies a moderate death risk mainly in pts with severe comorbidities and complications, first of all paraplegia that can be reduced with the clamp and go technique. Since its first performance it was apparent that EVG repair necessitating epidural or local anesthesia, no clamping, less acute cut-off of blood supply to the spine, reduced mortality from 5 –7 % recorded with open surgery to 1-2% and complications from ~ 8% to 1%. EVG treatment of atherosclerotic aneurysm requires a landing zone proximal to the aneurysm of at least 2 cm; this requires covering of the left subclavian artery with possible transposition or by-pass when previous setting of anatomical compensation of intracerebral posterior circulation need to be preserved. The risky penetrating aortic ulcers are frequently affecting the descending aorta and should be treated due to the severe prognosis of their possible rupture. The intramural haematoma which can be present in association with dissections or aneurysms, requires a more conservative attitude, considering the possibility of its regression; and the consideration that it is difficult to identify the source of the leak which leads to the contained extravasation of blood into aortic wall. Acute ruptures of atherosclerotic descending aortic aneurysm, when anatomically feasible, are an excellent indication to EVAR. The rupture in surviving pts. is usually contained by the pleura and/or mediastinum and avoiding thoracotomy it has been proved to be very helpful in reducing the severe mortality which carries this presentation when treated with open surgery. Post traumatic injuries causing pseudo-aneurysm are mainly limited to the posterior aortic arch but infrequently (~ 5%) can affect the descending aorta. More frequently the entry tear of a type B aortic dissection can be located in the descending aorta (35%); besides the complicated cases (visceral malperfusion or expanding aortic aneurysm when endovascular treatment is indicated) EVG treatment is advocated from many AA also in not complicated cases quoting the ominous outcome in the long-follow up. Although more and more anecdotal reports are present in the literature of successful treatment of broncho-esophageal aortic fistulae, concern exist about long term outcome of these patients. Last but not least indication for EVG in descending aortic aneurysm is the completion of so called "Elephant trunk" surgery connecting the distal trunk with a healthy segment of distal aorta. Miscellaneous, but important is the possibility of EVG repair of complications of previous surgical or endovascular interventions presenting in the FU with endoleaks or pseudo-aneurysms.

Conclusion: In the stage of endovascular treatment of descending aorta, thoracic aortic aneurysms have become the pathology where EVG is the first option because of the reduced mortality and morbidity in comparison with open traditional surgery. We still need data from long-term follow-up to clarify the role of endovascular surgery in these patients.



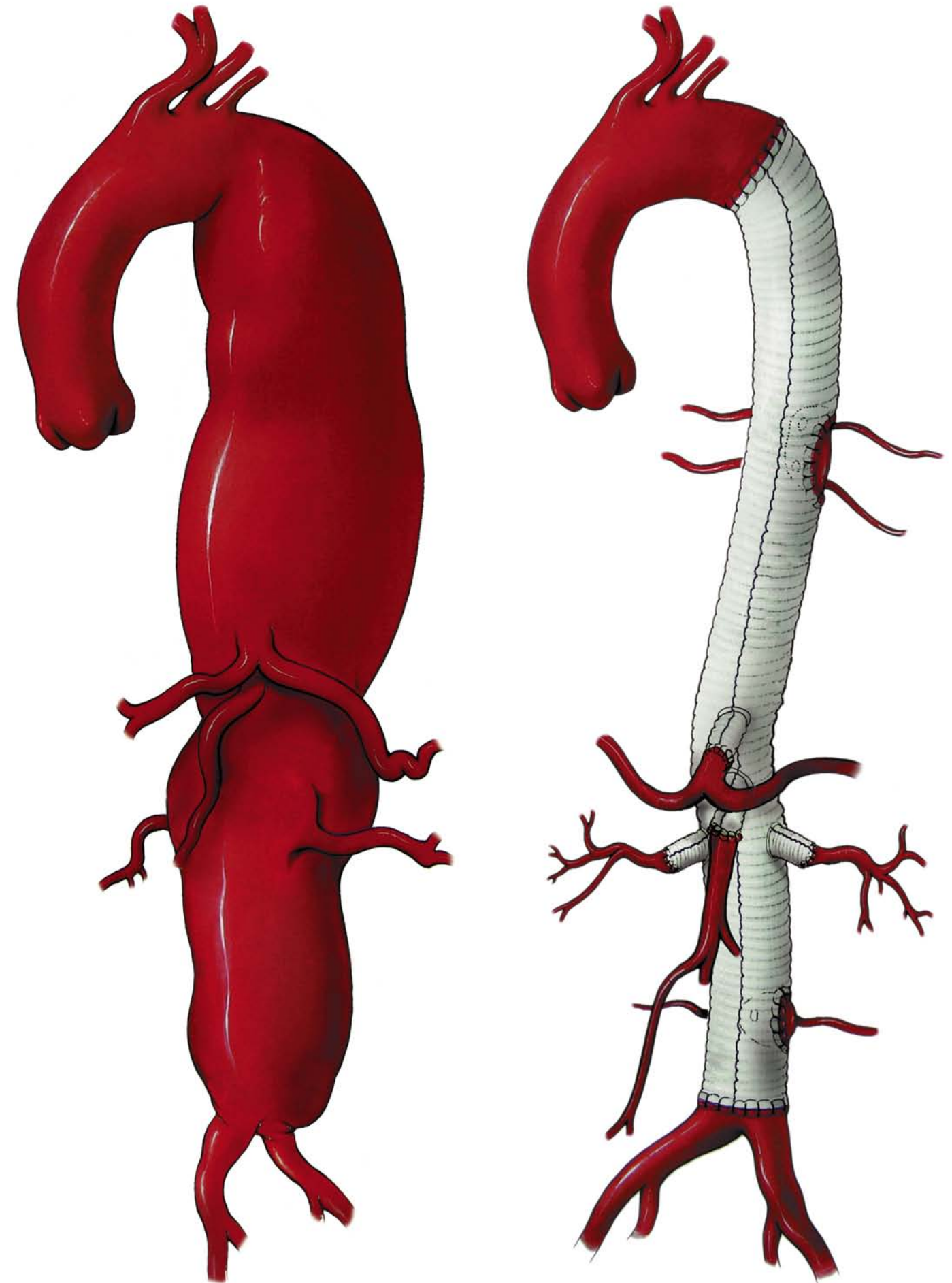
# OPEN SURGERY FOR TYPE I AND II THORACOABDOMINAL AORTIC ANEURYSMS WITH THE BRANCHED COSELLI GRAFT

**Joseph S. Coselli**

*Baylor College of Medicine, and Texas Heart Institute at St. Luke's Episcopal Hospital,  
Houston - TX - USA*

J.S. Coselli, S.A. LeMaire

Aneurysmal dilation of residual aorta after thoracoabdominal aortic aneurysm repair is a well-described complication. The Carrel reimplantation patch for the visceral vessels is a common location of recurrent aneurysm formation. Patients with connective tissue disorders, such as Marfan syndrome, or significant separation of the orifices of the visceral vessels are at highest risk for this problem. In attempt to minimize residual aortic tissue, a pre-fabricated, gelatin impregnated, woven polyester graft with four individual visceral arterial branches has been developed for thoracoabdominal aortic reconstruction (Vascutek Terumo, Scotland). The graft has two 10-mm branches, one each for the celiac and superior mesenteric arteries, and two 8-mm branches for the renal arteries. In addition to reducing the amount of residual aortic tissue, the branched graft enables sequential restoration of visceral blood flow and, by facilitating tension-free anastomoses, may also improve hemostasis and prevent late pseudoaneurysm formation. Although early results are excellent, long-term follow-up studies will be required to determine whether this graft decreases the incidence of reoperation for recurrent aneurysm formation.





# HYBRID APPROACH TO THORACOABDOMINAL AORTIC ANEURYSMS IN PATIENTS WITH PRIOR AORTIC SURGERY

**Germano Melissano**

*Vita-Salute San Raffaele University, Milano - Italy*

R. Chiesa, Y. Tshomba, G. Melissano, E.M. Marone, L. Bertoglio, F. Setacci, F.M. Calliari

**Objective.** Thoracoabdominal aortic aneurysm (TAAA) hybrid approach consisting of visceral aortic debranching with retrograde revascularization of the splanchnic and renal arteries and aneurysm exclusion employing stent-grafts may be considered particularly appealing in high-risk patients especially with prior aortic surgery. The aim of this study is to analyze the data prospectively recorded of a series of high-risk patients with prior aortic surgery underwent at our Institute TAAA hybrid repair and to compare the outcomes with a similar group of patients underwent TAAA open repair.

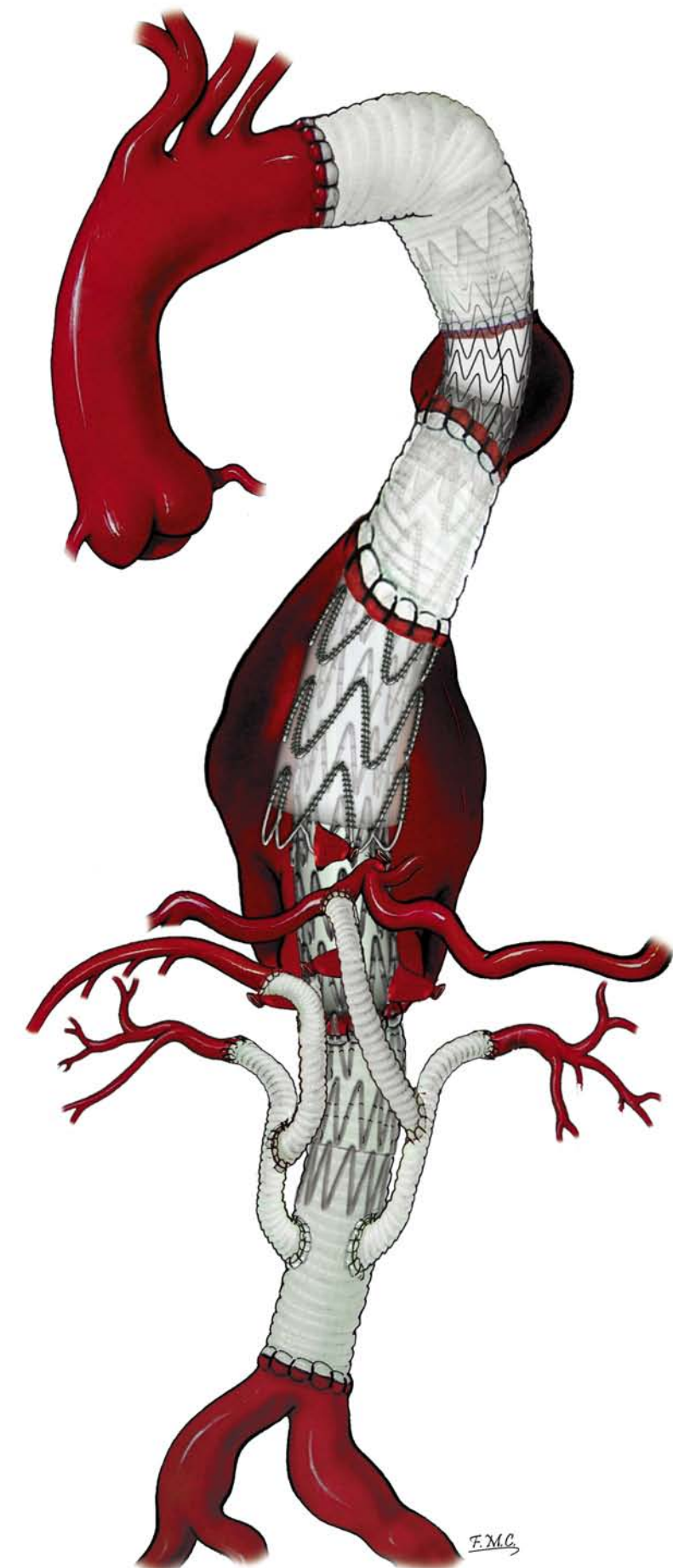
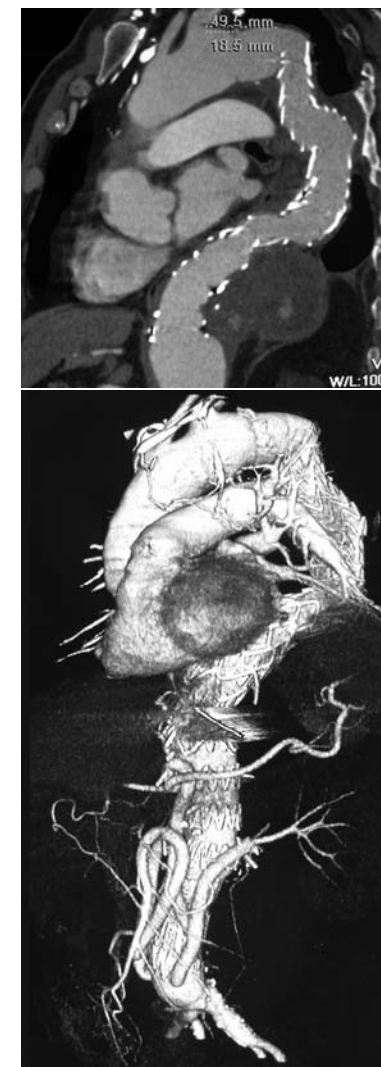
**Methods.** Between 2001 and 2006, 14 patients (median age 69.6 years, range: 35 to 82 years, 12 males) with history of prior aortic surgery at high risk for open repair underwent TAAA (7 type I, 2 type II, 2 type IV, and 3 aneurysms of the visceral aortic patch) one-stage "hybrid" repair (hybrid group). In all the cases we accomplished: 1. partial or total visceral aortic debranching via a previous visceral arteries retrograde revascularization with synthetic grafts (single bypass, customized "Y", bifurcated or trifurcated grafts), 2. aortic endovascular repair with one from three different commercially produced stent-grafts (Cook, W.L. Gore And Assoc, Medtronic).

We analysed the results and contrasted the outcomes of hybrid group to a similar group of 29 patients (median age 65.3 years, range: 58 to 79 years, 25 males) having history of prior aortic surgery underwent TAAA (10 type I, 5 type II, 4 type III, 7 type IV, and 3 aneurysms of the visceral aortic patch) open repair (conventional group).

**Results.** Hybrid group: overall 35 visceral bypasses were completed and TAAA stent-graft repair was successfully performed in all cases. No intraoperative mortality was reported. Perioperative mortality was 21.4% and morbidity 35.7% (3 cases of renal failure, one case of respiratory failure and one case of delayed transient paraplegia). At a median follow-up of 14.9 months (range, 11 days to 59.4 months) we did not observe any endoleak or stent-graft migration. One patient died for visceral grafts thrombosis at 38th postoperative day.

**Conventional group:** no intraoperative mortality was reported. Perioperative mortality was 17.2% and morbidity 44.8 % (7 cases of respiratory failure, 1 case of coagulopathy, 2 cases of renal failure, and 3 cases of paraplegia). At a median follow-up of 5.4 years (range: 1.7 \_ 7.9 years), we did not report significant aortic repair-related complications except for 3 (10.3%) asymptomatic dilatations of visceral aortic patch < 5 cm undergoing radiological surveillance.

**Conclusion.** Hybrid TAAA repair is technically feasible in selected cases. In our subset of high-risk patients with prior aortic surgery, perioperative morbidity and mortality have been considerable and TAAA hybrid repair did not lead to a significant outcomes improvements compared to TAAA open repair in a similar group of patients. Larger series are required for a statistical analysis and longer follow-up is needed to evaluate durability of TAAA hybrid repair.





# ENDOVASCULAR REPAIR OF THORACOABDOMINAL AORTIC ANEURYSMS

Timothy A.M. Chuter

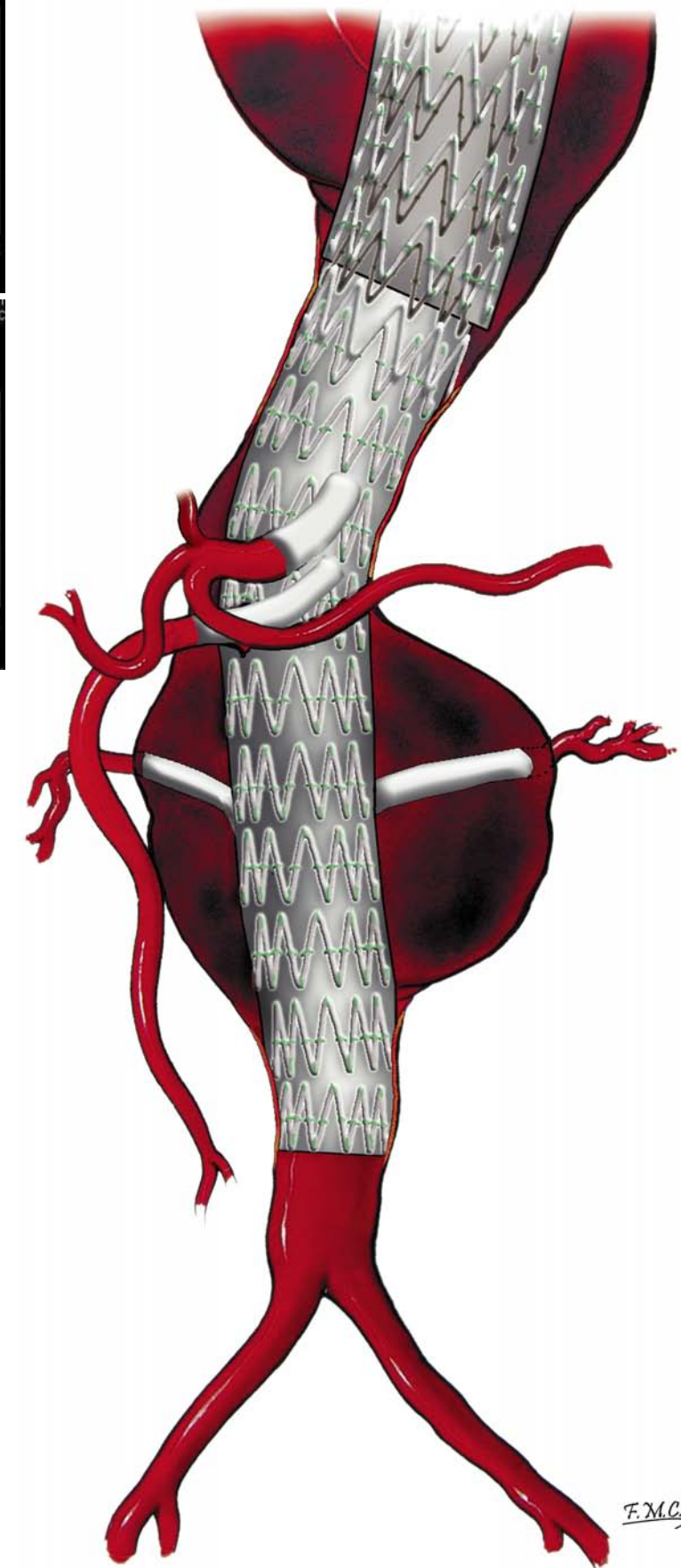
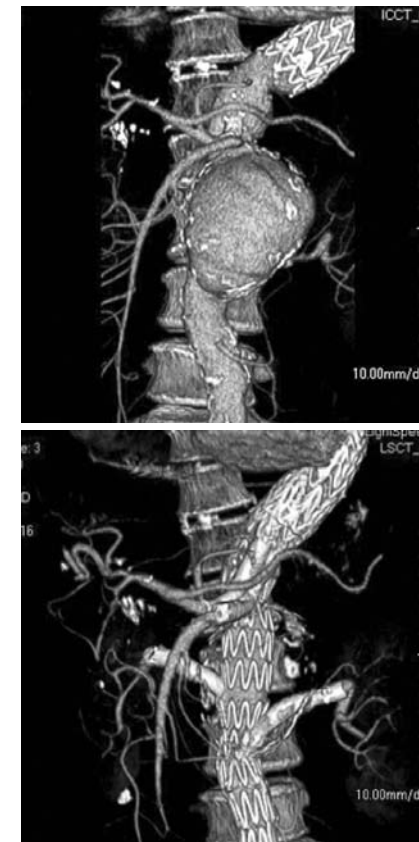University of California San Francisco - USA

Endovascular repair of thoracoabdominal aneurysms (TAAA) would have replaced surgical repair a long time ago were it not for one challenge; how to exclude the aneurysm from the circulation without also excluding flow to its branches. Implantation of a simple tubular stent-graft is not an option, unless vital arterial branches to the intra-abdominal organs have already been provided with an alternative source of blood through extra-anatomic bypass.

The technology of branched stent-graft insertion has evolved over the past 5 years to include: constraining wires to hold the stent-graft in a state of partial deployment, markers to aid in orientation, indwelling catheters and wires to aid in trans-graft catheterization, and a wide variety of attachment sites on the primary aortic stent-graft to create secure, hemostatic intercomponent connections. These attachment sites fall into two main groups, fenestrations and cuffs.

A fenestration is, at its simplest, just a hole in the wall of the primary stent-graft. Nitinol rings may be added to re-inforce the fenestration, but there is no zone of contact between the rim of the fenestration and the branch, just a discrete ring no deeper than the graft is thick.

A cuff, on the other hand, has a margin of fabric, which creates an overlap zone between the primary stent-graft and the branch stent-graft (covered stent). In that regard, a cuff resembles the attachment site for the contralateral limb of a typical modular bifurcated stent-graft. Cuffs can extend outwards or inwards, upwards or downwards, from the wall of the primary stent-graft. They can be short or long, straight or curved, depending on the location and orientation of the corresponding target artery.



# ENDOVASCULAR TREATMENT OF THORACOABDOMINAL AORTIC ANEURYSMS WITH BRANCHED ENDOGRAFTS: CLEVELAND EXPERIENCE

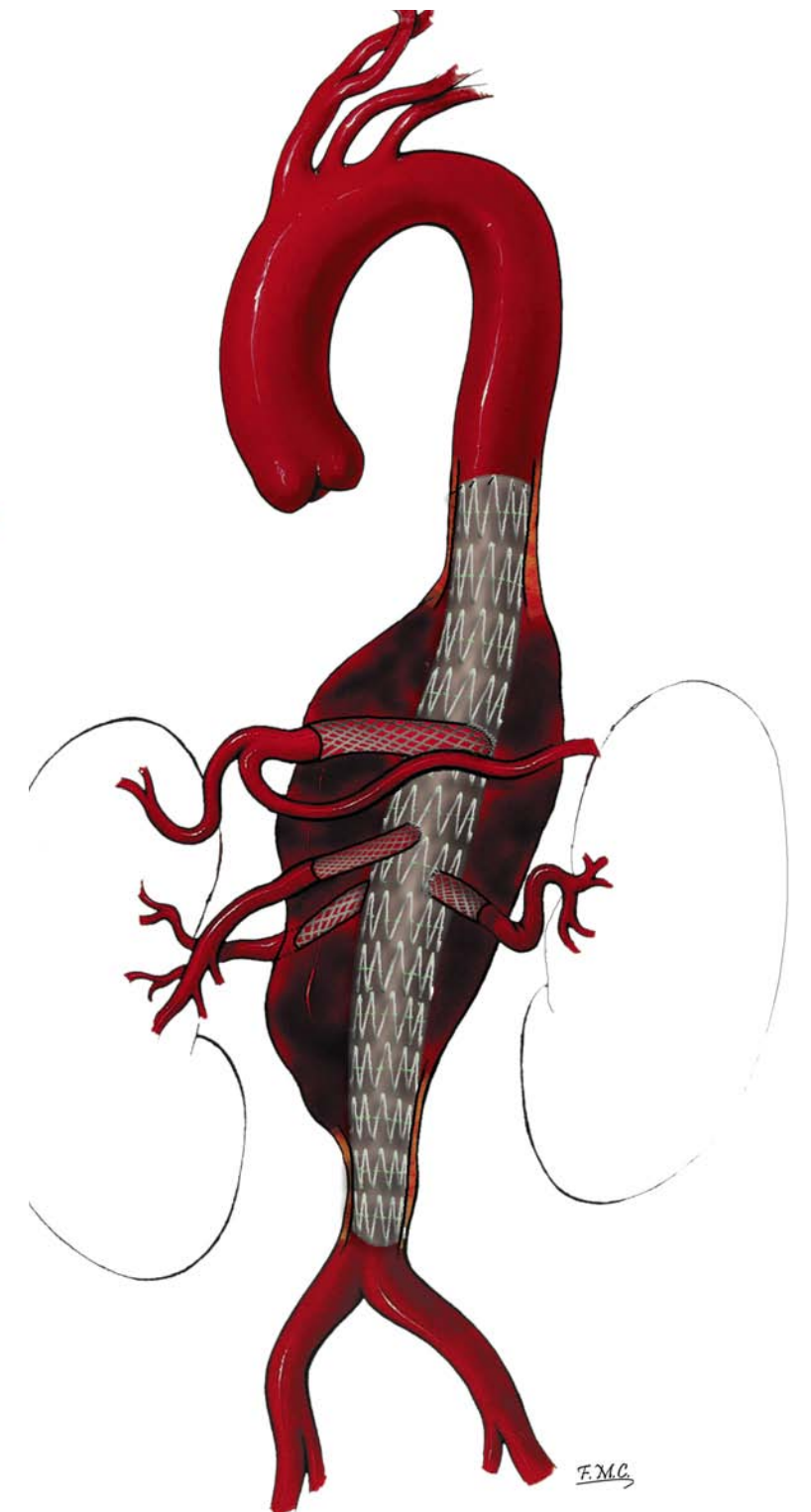
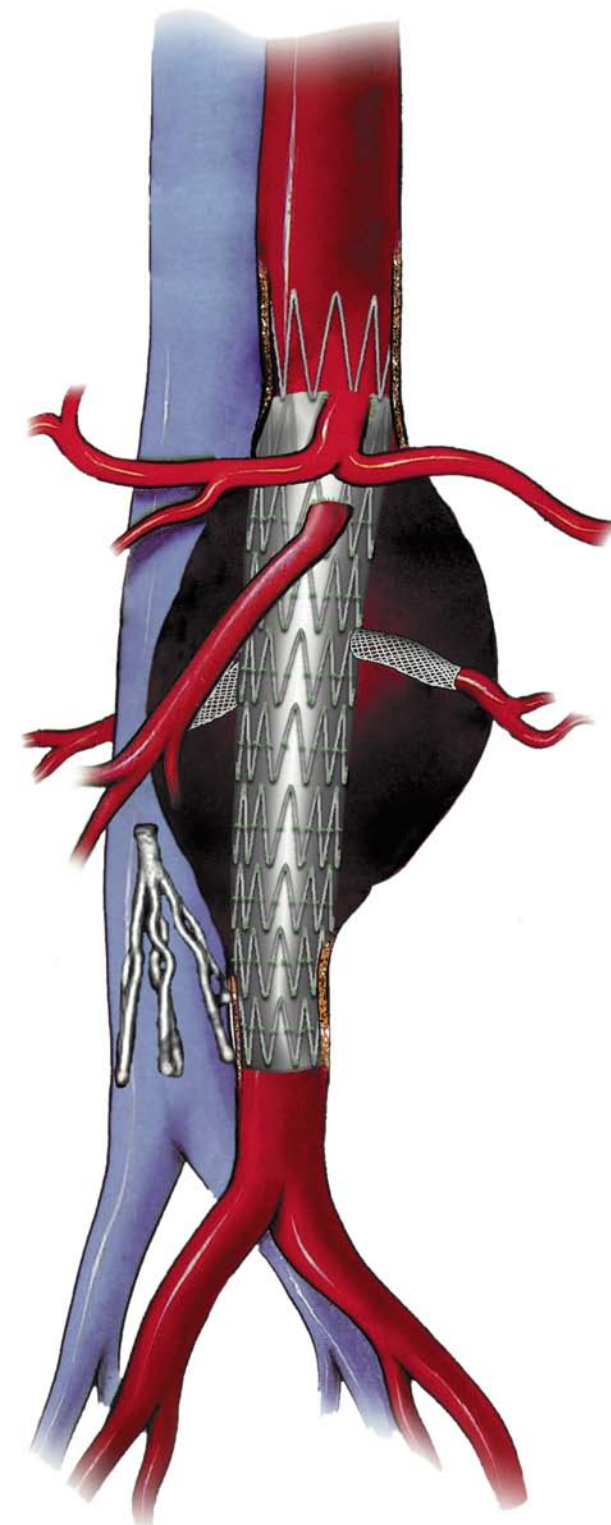
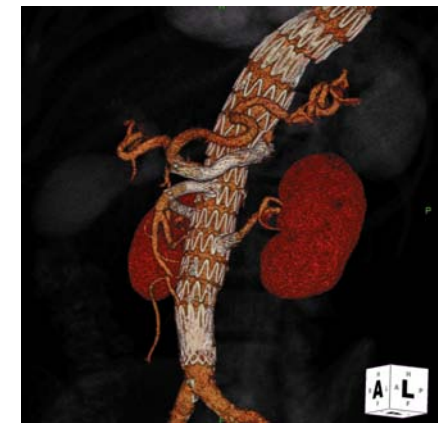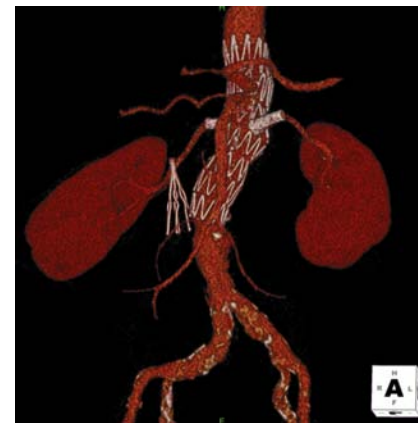
Roy K. Greenberg

Cleveland Clinic Foundation - OH - USA

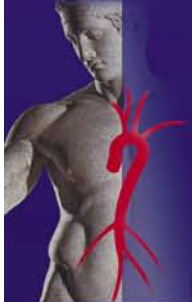The management of thoracoabdominal aneurysms may be revolutionized by the development of versatile endovascular devices capable of excluding these complex aneurysms and preventing rupture. However, currently such designs are complex, requiring a detailed understanding of the anatomy derived from cross-sectional imaging studies, the ability to manipulate the images on a 3D workstation, endovascular techniques relating to aortic stentgrafting and the management of visceral vessels, and careful attention to follow-up. The specific designs of the devices utilized relate to the extent of the aneurysmal disease, morphology of the aorta in the region of branches, the length and diameter of the target branch as well as the tortuosity of the surrounding vasculature. Two conceptual designs have been utilized:

- 1) reinforced fenestrations - the use of a conventional fenestration which is reinforced with a nitinol ring. This is coupled with a balloon-expandable stentgraft.
- 2) Directional branches - a side arm sewn to the graft in a specific manner that is coupled with a self-expanding stentgraft.

The video will demonstrate examples of each type of branch, the techniques for deployment and some basic problem solving issues.







'06

SCIENTIFIC ABSTRACTS

SESSION V - AAA Open Surgery

*President:* Carlo Spartera  
*Chairmen:* Livio Gabrielli, Jean-Georges Kretz  
*Discussants:* Angelo Argenterì, Stefano Bonardelli, Bruno Gossetti

OPEN SURGICAL TREATMENT OF ABDOMINAL AORTIC ANEURYSM	Carlo Setacci
OPEN SURGICAL TREATMENT OF TYPE IV THORACOABDOMINAL AORTIC ANEURYSMS	Joseph S. Coselli
OPEN SURGICAL TREATMENT FOR INFLAMMATORY AAA	Andrea Stella
OPEN SURGICAL TREATMENT OF AORTO-ENTERIC FISTULAS	Giancarlo Bracale
PARARENAL AORTIC ANEURYSMS: A TEN-YEAR EXPERIENCE USING OPEN SURGERY	Fabien Koskas
OPEN SURGICAL TREATMENT FOR ILIAC AND HYPOGASTRIC ANEURYSMS	Carlo Pratesi

# OPEN SURGICAL TREATMENT OF ABDOMINAL AORTIC ANEURYSM

**Carlo Setacci**

*University of Siena - Italy*

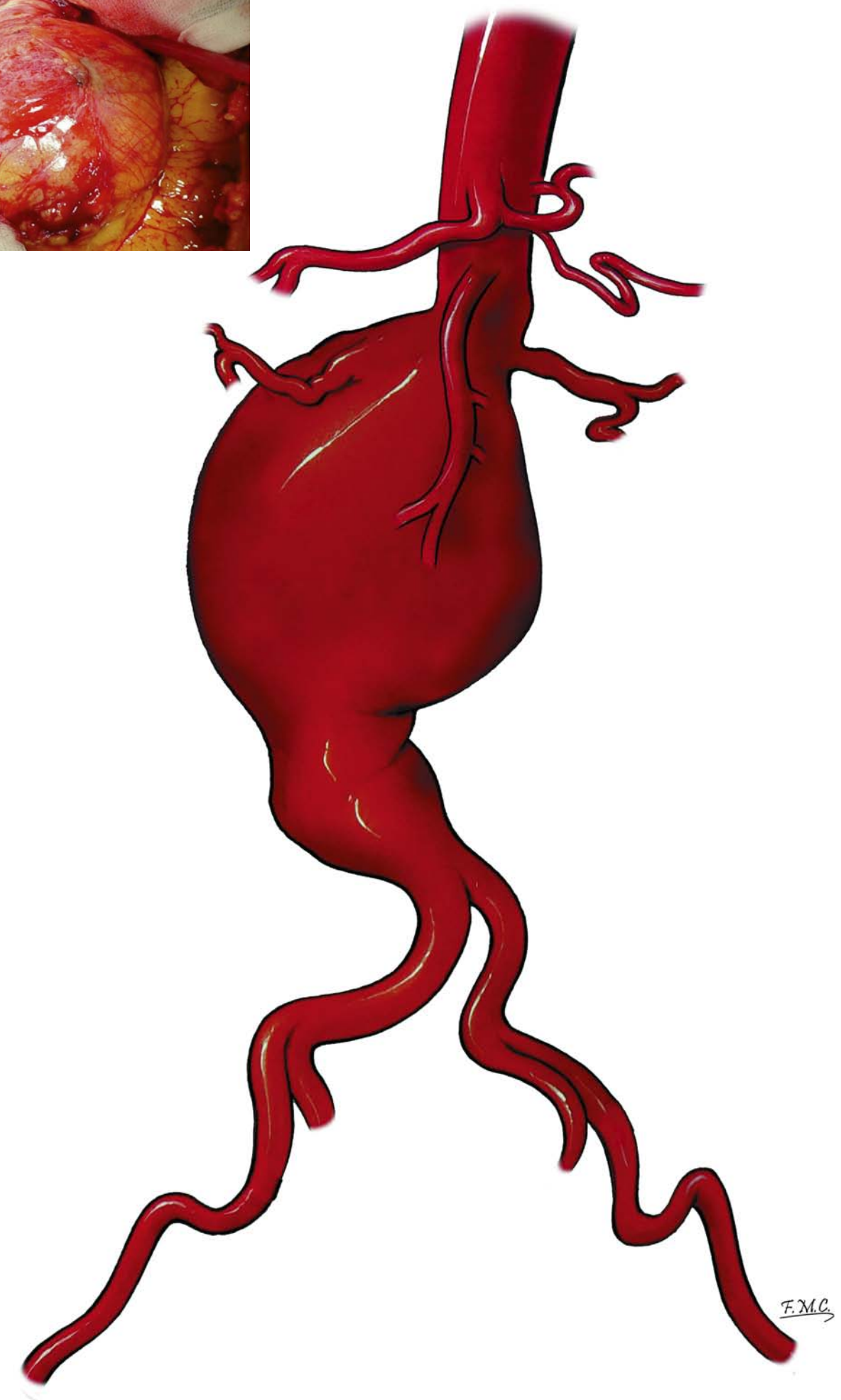
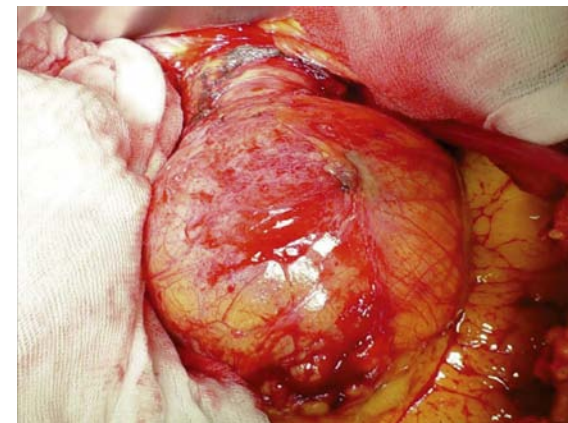
C. Setacci, G. de Donato, E. Chisci

The increasing availability of endovascular grafts has substantially changed the elective management of abdominal aortic aneurysm (AAA). As more patients with favorable anatomy undergo endovascular graft AAA repair (EVAR), AAA repair via an open approach is being performed less often and mainly in patients with complex unfavorable anatomy. As a matter of fact endovascular stent grafting is not universally applicable to all patients because of a variety of anatomic constraints: aneurysm necks larger than 30 mm in diameter and less than 15 mm in length provide less than optimal proximal fixation; aneurysm neck angulation greater than 60° and the presence of accessory renal arteries also make proximal fixation challenging; aneurysmal iliac disease can create problems with distal fixation and pelvic ischemia, and iliac occlusive disease makes vascular access problematic. These anatomic constraints often disqualify patients from consideration of endovascular stent grafting as a treatment option, and then they are offered to elective open repair, but these same anatomic constraints also increase the complexity of this open AAA surgery.

During the period from January 2004 to June 2006, 251 consecutive patients were treated for AAA in our department. Of these, 129 patients (51.3%; 97 men, 32 women) underwent endovascular repair, and 122 patients (48.7%, 102 men, 20 women) open repair. Reasons for exclusion from EVAR included short aneurysm neck (62, 51%), inadequate access because of small iliac arteries (44, 36%), wide aneurysm neck (39, 32%), presence of bilateral common iliac aneurysms extending to the hypogastric artery (38, 31%), excessive neck angulation (14, 14%), extensive mural thrombus in the aneurysm neck (14, 12%), extreme tortuosity of the iliac arteries (56, 46%), accessory renal arteries originating from the AAA (8, 6%), and age < 60 years (46, 37%).

Moreover the increased complexity of aneurysm open repair in the EVAR era, may have implications for resident and fellow education and training. The young vascular surgeons are faced with a declining incidence of straightforward open aneurysm repairs and an increase in the complexity of available cases. In fact, because most infrarenal AAAs are treated with endovascular devices, vascular surgeons will be faced with more complex AAA (such as juxtarenal or coexisting iliac aneurysm) in the operative field rather than the routine infrarenal aortic disease. This may make it harder for them to gain the experience in simple open aneurysm repairs that is essential before progression to more complex aneurysm surgery. In conclusion at the present time patients with AAA and favorable anatomy are increasingly undergoing EVAR. Accordingly, traditional open repair is being used more often in patients with unfavorable aortoiliac or AAA anatomy, and, in addition, many of these patients also have serious medical comorbid conditions. Then open repair of abdominal aneurysms is a more technically challenging procedure today than it was before the advent of endovascular stent grafts.

Despite the increased complexity of open repair, this technique remains a safe and durable procedure, even in emergency situations and anatomically challenging patients.





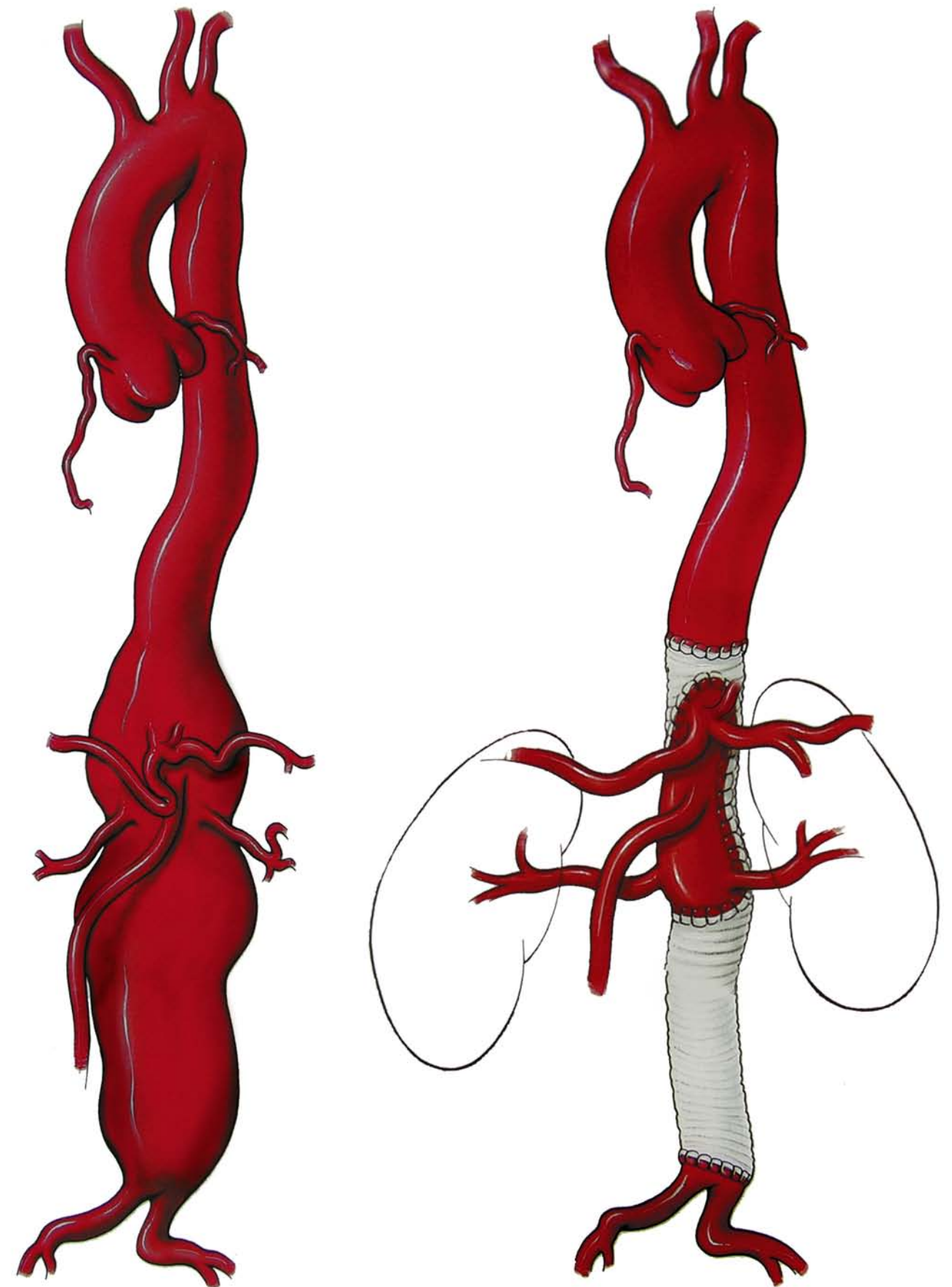
# OPEN SURGICAL TREATMENT OF TYPE IV THORACOABDOMINAL AORTIC ANEURYSMS

**Joseph S. Coselli**

*Baylor College of Medicine, and Texas Heart Institute at St. Luke's Episcopal Hospital,  
Houston - TX - USA*

J.S. Coselli, S.A. LeMaire

Crawford type IV thoracoabdominal aortic aneurysms involve most or all of the abdominal aorta, often extending from the diaphragm to the aortoiliac bifurcation. Recent endovascular innovations have led to new treatment strategies - including the use of fenestrated endografts, branched endografts, and hybrid procedures - for repairing these aneurysms. Careful assessment of the safety and efficacy of these alternative approaches will require comparison with standard open surgical repair. Since 1986, we have performed 2286 consecutive open thoracoabdominal aortic operations, 427 (18.7%) of which were type IV repairs. Adjuncts to prevent ischemic complications included low-dose heparinization, mild passive hypothermia, and cold renal artery perfusion. The 30-day mortality rate following type IV thoracoabdominal aortic repair was 3.0% (13 patients). Postoperative acute renal failure requiring hemodialysis occurred in 23 patients (5.4%). Six patients (1.4%) developed paraplegia or paraparesis. In conclusion, current management strategies enable patients to undergo conventional open type IV thoracoabdominal aortic repair with excellent early survival and acceptable morbidity. We anticipate that this data, along with other contemporary series, will serve as a basis for comparison as endovascular approaches continue to evolve.



# OPEN SURGICAL TREATMENT FOR INFLAMMATORY AAA

**Andrea Stella**

*S. Orsola-Malpighi Hospital, University of Bologna - Italy*

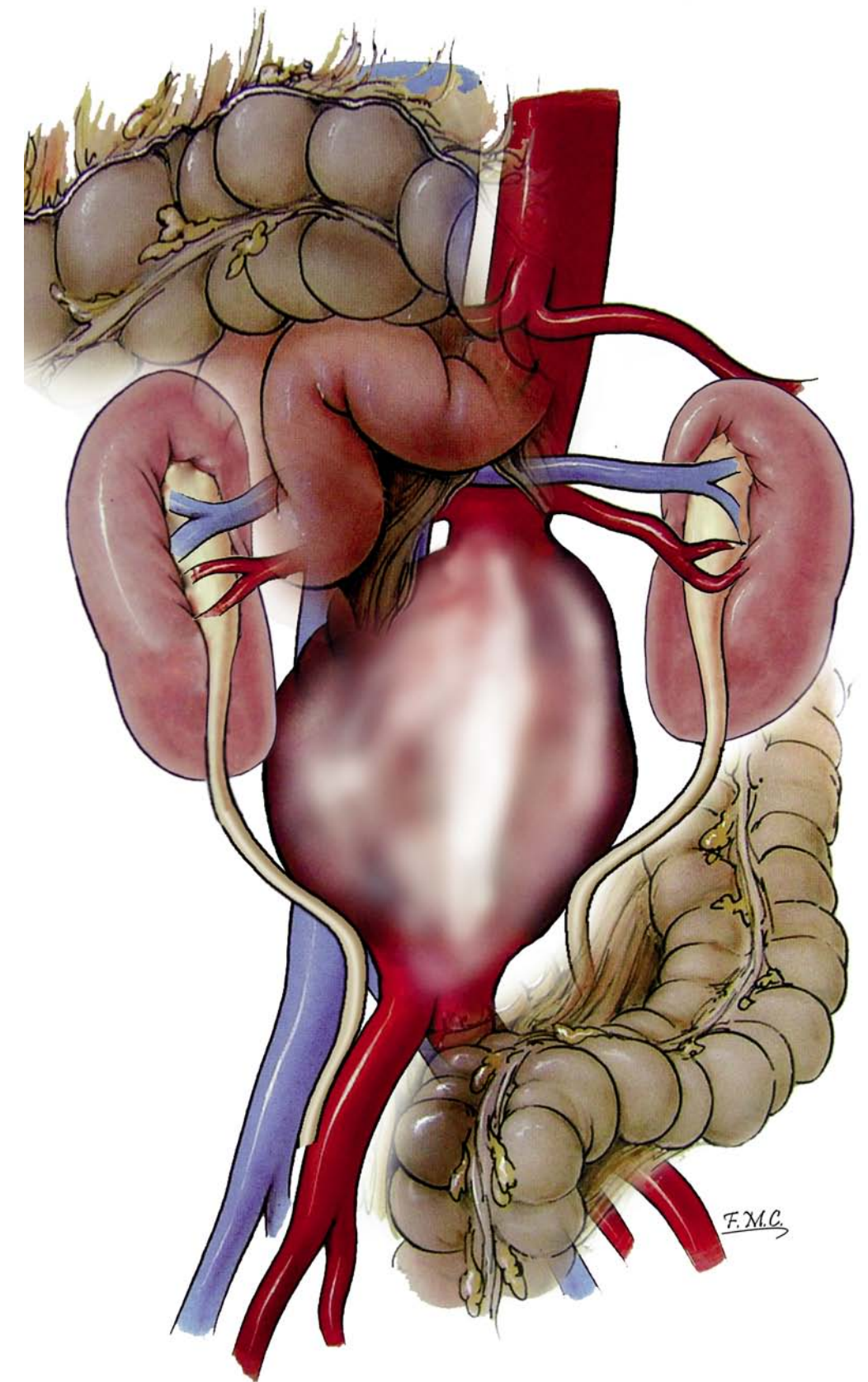
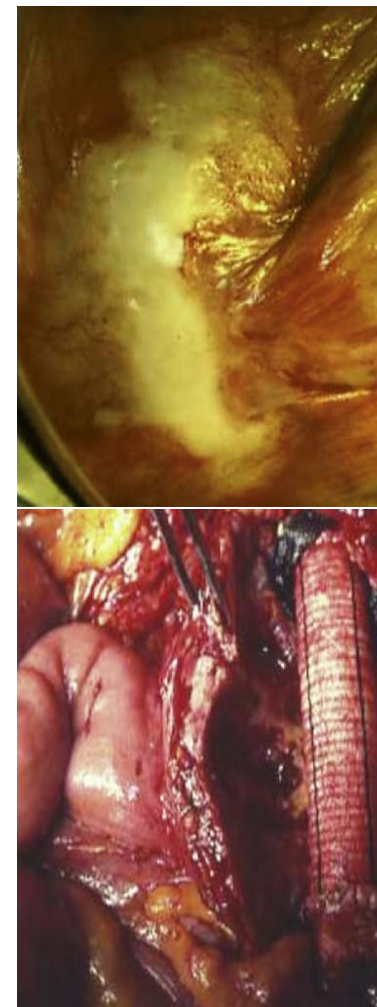In 1935 James first described a peri-aortic inflammatory process in a patient with abdominal aortic aneurysm (AAA). The inflammatory reaction led to entrapment and occlusion of both ureters resulting in kidney failure and death. Since then a number of reports have described cases of AAA with peri-aortic inflammation. In 1972 Walker et al. defined this feature as “inflammatory aneurysm”.

Inflammatory abdominal aortic aneurysm (IAAA) is a well-defined clinical and pathologic entity with an incidence ranging from 2% to 18.1% of all cases of AAA. The triad of abdominal or back pain, weight loss and elevated erythrocyte sedimentation rate in a patient with AAA is highly suggestive of a IAAA. These variant of aneurysm have a predilection to occur in males with a mean age 5-10 years younger than the patients with atherosclerotic aneurysms. Macroscopically the lesion presents a whitish, thickened aortic wall (> 0.5 cm thick) adhering to adjacent tissues and organs (duodenum, sigmoid colon, ureters, inferior vena cava, left renal vein, left gonadal vein, small bowel, pancreas). Thickening of the vessel wall is caused by centrifugal development of a parietal fibro-inflammatory process whose aetiology and mechanisms of onset remain unsettled (there is evidence for the role of genetic factors in the development of IAAA).

The abdominal CT scan is the most reliable radiographic study to detect aneurismal wall thickening, perianeurysmal soft tissue changes and entrapment of adjoining structures; the accuracy of high-resolution ultrasound is reported to be less than that of abdominal CT scan while the urography is of historical interest only. Magnetic resonance imaging may be preferred as it avoids ionizing radiations and is less nephrotoxic. Nuclear medicine techniques can delineate increased uptake in the inflammatory processes in the aortic wall and surrounding tissues and can monitor the activity in the follow up.

Thickening of the aortic wall does not seem to reduce the risk of aneurysm rupture so that surgery remains the treatment of choice. Surgical management of IAAA is technically difficult due to the presence of the parietal inflammatory process. The relations between the aorta and proximal structures are impaired, hampering isolation of the aneurysm and increasing the risk of iatrogenic damage to periaortic structures with a consequent rise in morbidity and mortality. Despite the technical difficulties associated with IAAA, data from the literature supports an operative approach to management whenever possible with modified operative techniques (limited dissection of the aneurysm wall, above renal arteries aortic clamp, left antero-lateral approach to the sac). Controversy exists regarding abdominal approach (trans-peritoneal or retro-peritoneal) and ureterolysis during repair of IAAA. We do trans-peritoneal route and rarely do ureterolysis. With these surgical approach, the operative mortality-morbidity and late survival of IAAAs were comparable to the non-inflammatory AAA.

The post-operative evolution of the periaortic fibro-inflammatory process can be monitored with CT angiography. A review of the literature revealed that complete postoperative regression of periaortic fibrosis was observed in 23-84.5% of the IAAA studied, partial regression in 6.2%-66.7%, no regression in 0-38% and progression in 3.1-4% of the patients. In view of the technical difficulty of open IAAA repair, endovascular aneurysm repair is an attractive option. A number of case reports and series in the literature show good early results in terms of patient survival, early morbidity and aneurysm exclusion but infrequently longer-term regression of perianeurysmal fibrosis. Than open repair remains the treatment of choice of IAAA with entrapment of perianeurysmal structures.





# OPEN SURGICAL TREATMENT OF AORTO-ENTERIC FISTULAS

**Giancarlo Bracale**

*University Federico II, Napoli - Italy*

GC. Bracale, M. Porcellini, L. del Guercio, F. Carbone, UM. Bracale, A. Russo

Primary and secondary aorto-enteric fistulas (AEFs) remain one of most challenging vascular complications to treat. The incidence of primary AEF ranges from 0,1% to 0,8%, and secondary from 0,4% to 4%. Recently, AEFs secondary to endovascular procedures are increasingly reported.

The most frequent presenting sign of AEF is upper gastrointestinal bleeding.

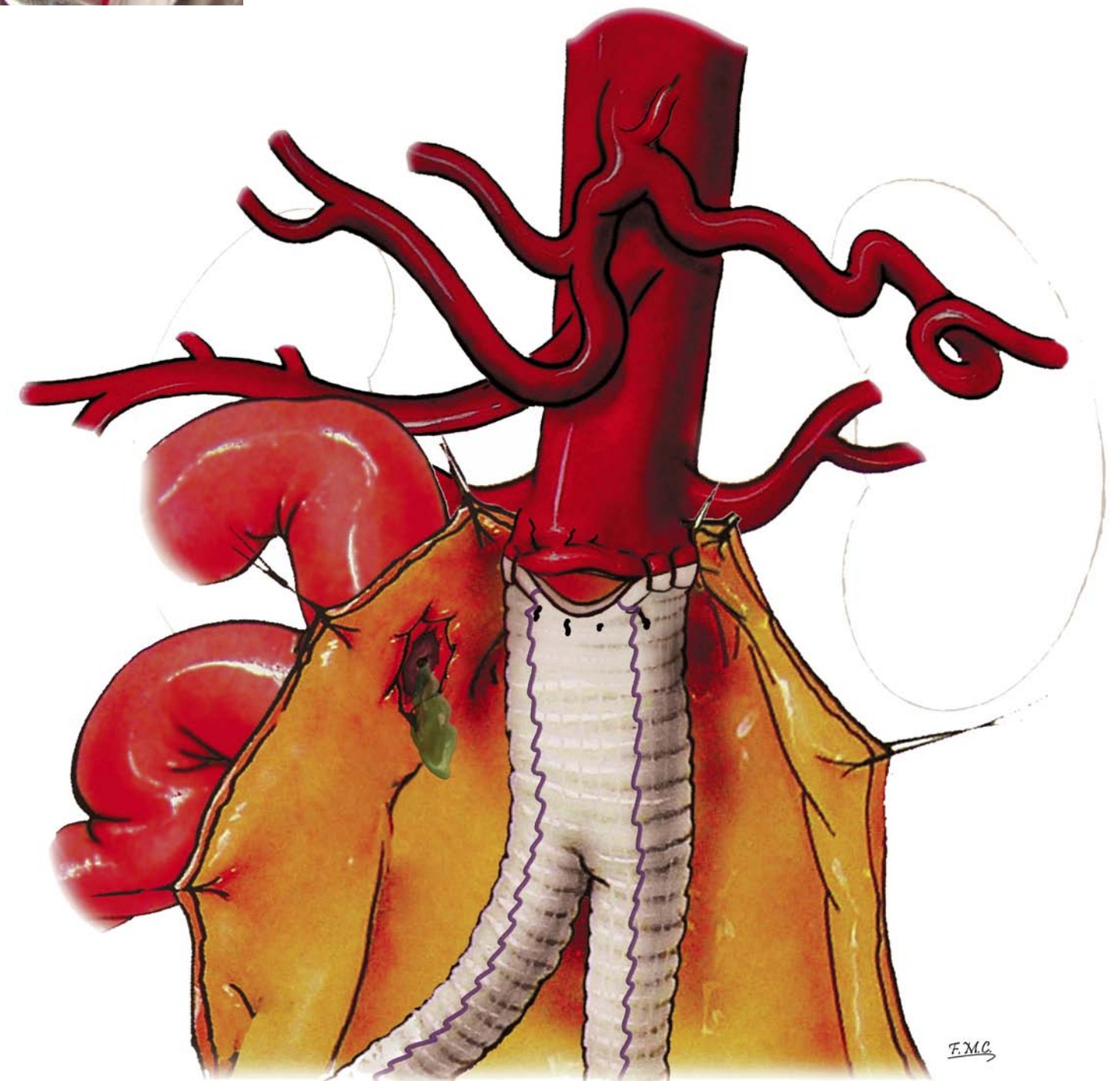
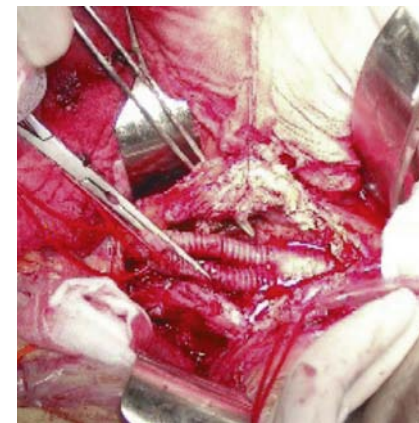
Clinical suspicion is essential in the diagnostic approach to AEF and the most commonly used diagnostic techniques are endoscopy and TC.

The mortality rate after surgical treatment of secondary AEFs is from 14% to 70%; the use of endovascular repair has been described, with a high recurrence rate of infection or AEF.

**Patients and methods.** From 1986 to 2005 15 patients (14 M, 1 F), with average age of 68.6 (58-79) years, affected with AEF were observed and treated. There were 2 (13.3%) primary and 13 (86.7%) secondary AEFs. The primary fistulas were caused by AAA rupture; secondary AEFs developed after abdominal aortic surgery, after a mean time interval since the primitive aortic procedure of 43 months. In 12 (80%) cases fistula involved the duodenum, in two the small bowel (13.3%), in one the sigmoid colon (6.6%). In cases of primary AEFs digestive bleeding was followed by back pain and hemorrhagic shock; in cases of secondary AEFs by sepsis and retroperitoneal abscess, and ruptured para-anastomotic aneurysm. Two patients (13.3%) underwent endovascular repair (aortouniiliac endografting and femorofemoral bypass) and 13 (86.7%) open repair, including graft excision, bowel suture or bowel resection in all, and aortic stump closure and axillo-femoral bypass in two, new in situ arterial prosthesis in eight, and in situ arterial homograft replacement in three.

**Results.** The 30-day mortality rate in the endovascular repair patients was nil, and in the open repair group was 38.4% (5 of 13). Reinfection or recurrent AEF occurred in three (20%) patients, including one treated by endovascular procedure after 14 (3-27) months. No signs of reinfection or new AEF occurred in 5 (33.3%) patients (mean follow-up 33.2 (7-51) months).

**Conclusions.** The widely accepted treatment is still open surgery with debridement followed by in situ replacement of a graft or extra-anatomical reconstruction; mortality remains high (38.4% in our series), but improved outcomes are reported in contemporary series in absence of preoperative hemodynamic instability. Because of a high recurrence rate of infection or AEF, endovascular sealing of AEF should be seen as a bridge to open surgery.





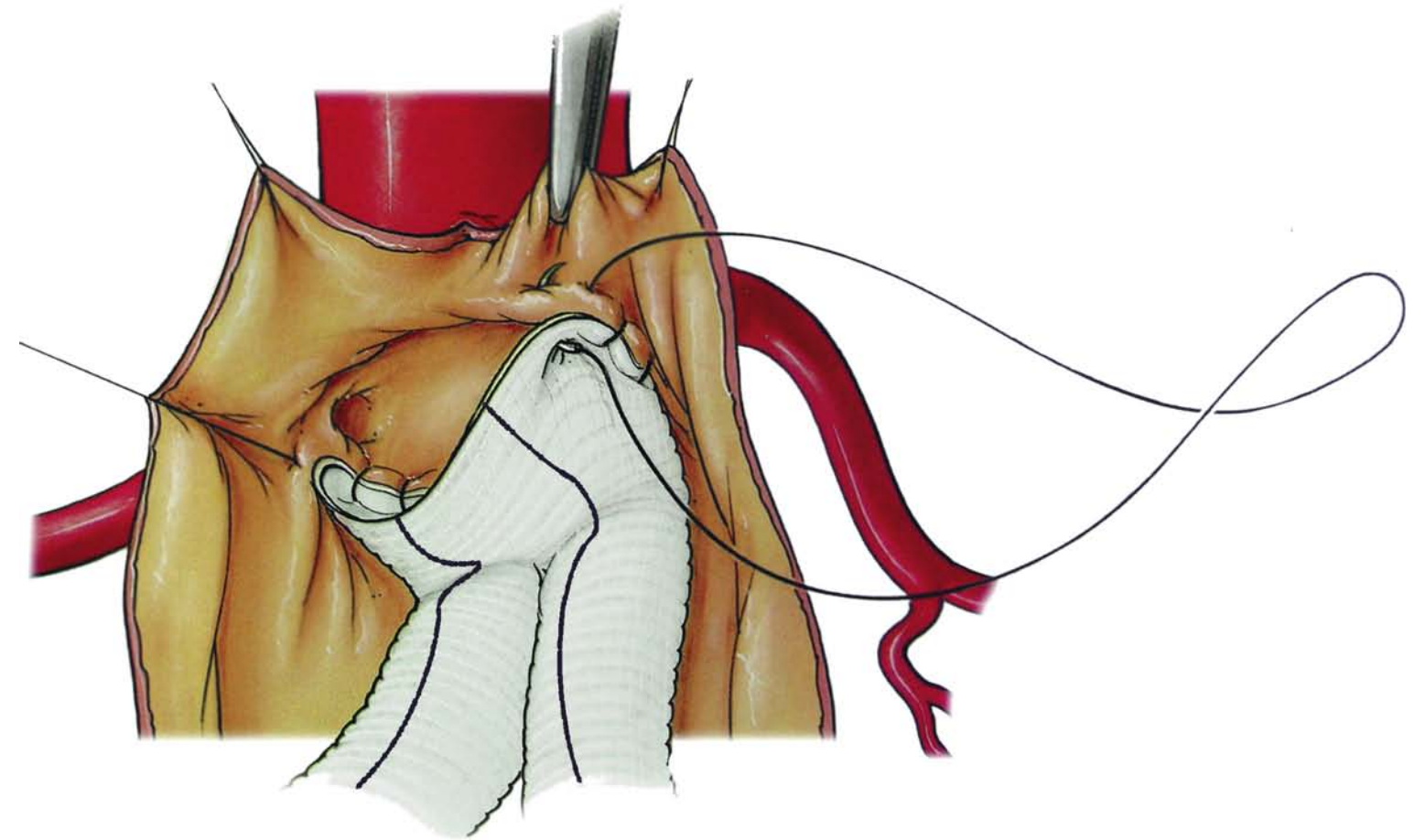
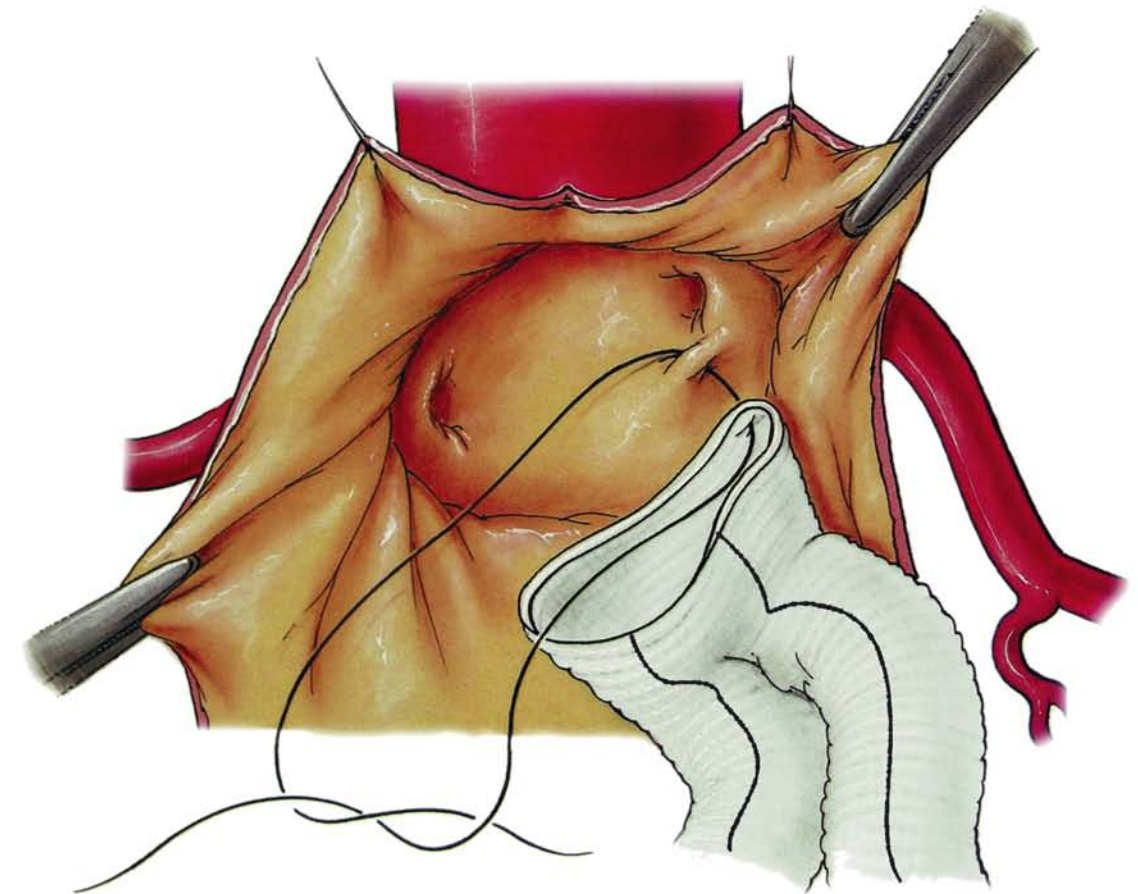
# PARARENAL AORTIC ANEURYSMS: A TEN-YEAR EXPERIENCE USING OPEN SURGERY

**Fabien Koskas**

*CHU Pitié-Salpêtrière, Paris - France*

F. Koskas, A. Sepideh, B. Rhissassi, A. Tofigh, E. Kieffer

From January 1994 to December 2004 84 patients were operated in our service upon for a pararenal aortic aneurysm (PRAAA). 68 were juxtarenal (JRAAA) while 16 were supra-renal (SRAAA). Among these, eleven were operated upon in emergency, five were inflammatory and one was a mycotic aneurysm. Visceral occlusive or aneurismal disease was present in 37 cases. Short and long term results are given and compared to our parallel cohort of patients with infrarenal AAA. Techniques and predictors of morbidity and death are discussed.





# OPEN SURGICAL TREATMENT FOR ILIAC AND HYPOGASTRIC ANEURYSMS

Carlo Pratesi  
University of Firenze - Italy

Nearly all iliac artery aneurysms (IAAs) occur in the setting of coexisting abdominal aortic aneurysms (AAAs). Isolated IAAs are rare, having a prevalence of approximately 0.4% to 1.9% of all aneurysmal disease. The incidence of this disease in the population is estimated to be 0.03% in a recent large autopsy series. IAAs are typically found in men (ratio 7:1 male/female) and the prevalence of IAAs increases with the age, with a peak of incidence in the 7th to 8th decade.

The pathogenesis of isolated IAAs is not well known. Atherosclerosis seems to be the major cause, with mechanisms (proteolytic degradation of wall connective tissue, inflammation, biochemical wall stress and molecular genetics) similar to those determining the formation and development of AAAs. Far more rare are IAAs due to infection, trauma, arteritis, connective tissue diseases and pregnancy.

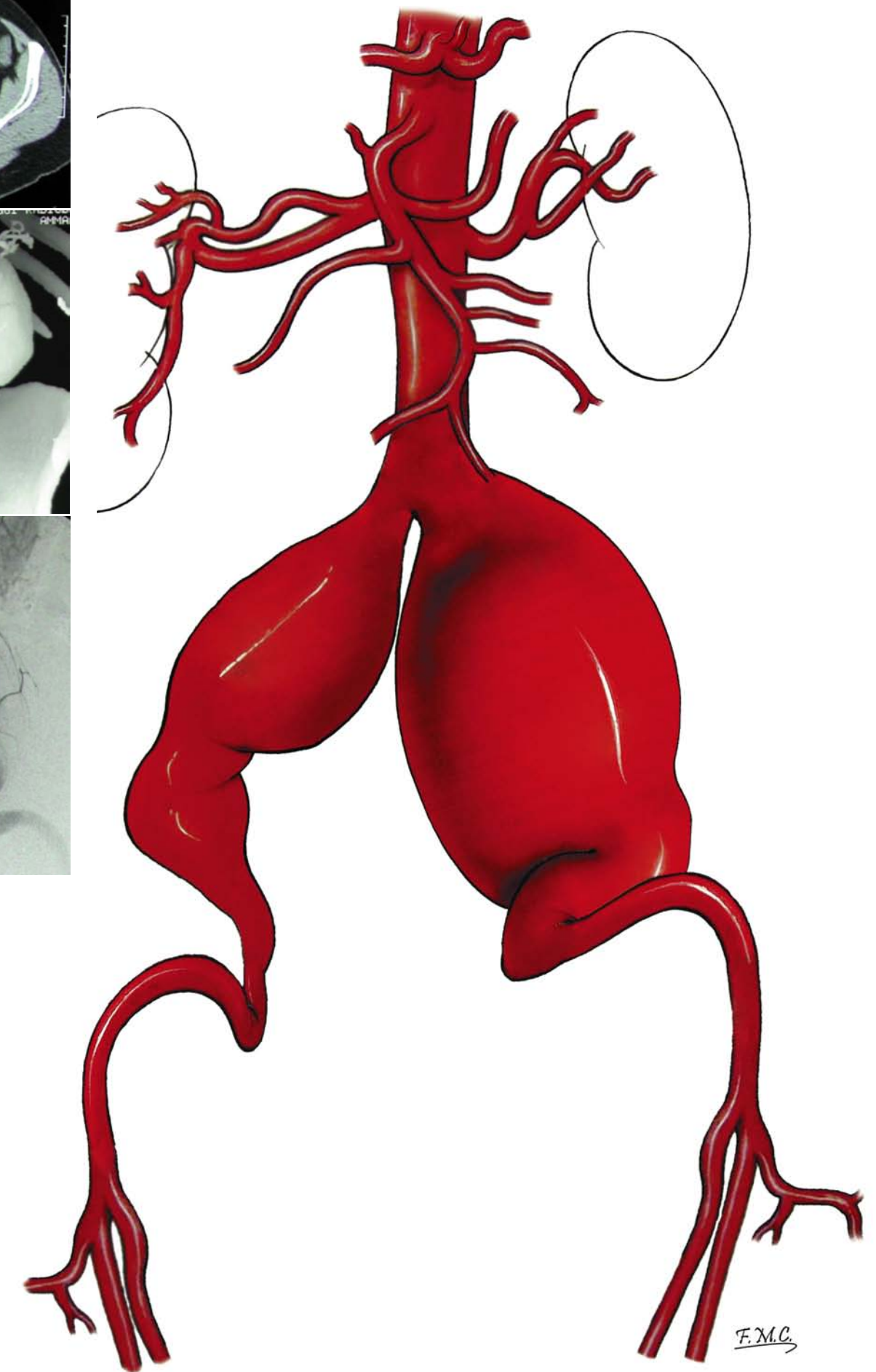
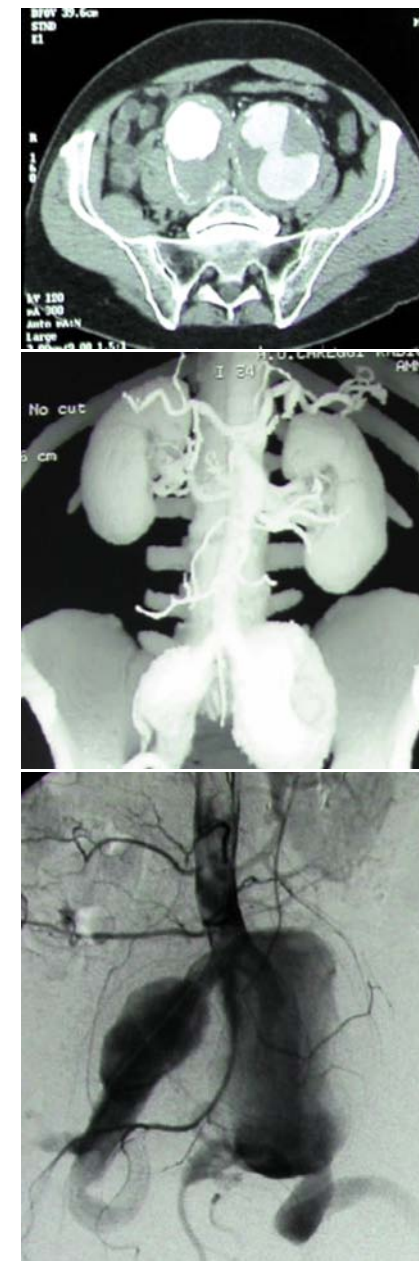
Most IAAs are asymptomatic and their diagnosis is often coincidental as a result of investigation for other conditions. However, many patients present with rupture, distal embolization, thrombosis and symptoms resulting from compression or erosion of surrounding anatomical structures (hydronephrosis and pyelonephritis for ureteral obstruction, pain on defecation for rectal compression and peripheral dysesthesias for nerve compression).

Natural history of IAAs remains largely unknown; it is probably characterized by a continuous sac expansion and rupture. Aneurysms of the internal iliac arteries seem to be a major tendency for rupture (about 40%). Like AAAs, size appears to be the most important rupture determinant. Ruptured IAAs are associated with high operative mortality (from 33% to 50%). Based on the available data, symptomatic IAAs and those larger than 3.5 cm should be corrected in elective operation in order to avoid the high risk of rupture.

In patients with indication for aneurysmal repair, therapeutic plan is made on the basis of: patient's general conditions; number of aneurysms and eventual bilaterality; size of aneurysmal sac; involvement of aorta and surrounding anatomical structures. According to morphological characteristics of the aneurysms of the iliac arteries, Sandhu and Pipinos identified five categories of IAAs: isolated common iliac artery aneurysms (CIAAs) (class A); isolated CIAAs with involvement of iliac bifurcation (class B); CIAAs with involvement of the internal iliac arteries (class C); isolated internal iliac artery aneurysms (IIAAs) (class D); CIAAs with involvement of aortic bifurcation or bilateral CIAAs or combined CIAAs and AAA (class E).

Endovascular treatment of IAAs is feasible when good proximal and distal landing zones are suitable. However, surgical treatment with open excision, ligation or endoaneurysmorrhaphy continues to be considered the treatment of choice for elective repair of IAAs. Mortality rate of open surgical management of IAAs is about of 5%, a rate higher than that registered in the open repair of AAAs. Also the rate of perioperative complications is extremely high (a mean value of 16% in several series). This was probably due to the pelvic localization of many IAAs, to the extremely complexity of the lesions and to the involvement of surrounding anatomical structures.

We report our experience with the open surgical treatment for iliac and hypogastric aneurysms.





SCIENTIFIC ABSTRACTS

SESSION VI - AAA Endovascular Surgery

*President:* Domenico Palombo  
*Chairmen:* Giorgio Biasi, Martin Malina  
*Discussants:* Giovanni Lorenzi, Adamastor H. Pereira, Francesco Speziale, Francesco Spinelli

EVAR WITH AORTO-MONO-ILIAC GRAFTS	Vicente Riambau
THE VASCULAR INNOVATION ENDOGRAFT IS EFFECTIVE AND DURABLE EVEN IN HIGHLY COMPLEX ANATOMY AND CHALLENGING AAAs	Takao Ohki
ENDOVASCULAR REPAIR OF RUPTURED AAA: HOW WE DO IT	Jean-Pierre Becquemin
FENESTRATED ENDOGRAFTS	Richard McWilliams
ENDOVASCULAR TREATMENT OF AORTO-ILIAC ANEURYSMS WITH THE HELICAL BRANCH ENDOGRAFT	Stéphan Haulon
LATE ENDOVASCULAR REOPERATIONS AFTER EVAR FAILURE	Piergiorgio Cao
LATE OPEN CONVERSIONS AFTER EVAR FAILURE	Dieter RaitHEL



# EVAR WITH AORTO-MONO-ILIAC GRAFTS

Vicente Riambau  
Hospital Clinic, University of Barcelona - Spain  
V. Riambau, I. Murillo, R. Hobo\*  
\*EUROSTAR database centre

Background: Endograft design could influence on EVAR’s outcome. However, this particular issue had not been deeply studied. Two major endograft designs have been suggested from the beginning of the EVAR history: bifurcated (BF) and aortomonoiliac (AUI).

AUI endograft should be associated with femoro-femoral regular graft and therefore potential vascular complications like thrombosis, graft infection or pseudoaneurysm formation have been described. However, BF endograft are not always applicable. Some anatomical difficulties like tortuous iliacs, iliac obstructions or narrowing of the distal aorta do not make BF endografting suitable for a safe and effective AAA endovascular exclusion.

Coming from single center or multicenter experiences, there are some reports in the literature with acceptable early results with AUI endografts. It could be interesting to go deeply just beyond some early and partial sensations.

Objective: In consequence, in order to know what happened in a mid-long term follow-up period with this particular configuration comparing with BF endografts we analyze a cohort of the aggregate data available from EUROSTAR database.

Patients and Methods: 5627 patients from the EUROSTAR database were reviewed. Old generation endograft were excluded. The baseline characteristics and outcomes of 5274 BF endograft and 353 AUI were compared. AUI patients were significantly older and than BF. Patients unfit for open repair were more frequent in AUI group (33.0% vs 21.8%,  $p<0.0001$ ). Distal aortic diameter was significantly smaller in AUI patients (25.9mm vs 29.8,  $p<0.0001$ ). Occlusion of common iliac arteries was predominantly found in AUI patients.

Results: 30-day mortality was higher in AUI group (8.5% vs 2.8%,  $p<0.0001$ ). Annual mortality was 7.3% for BF devices and 14.1% for AUI devices ( $p<0.0001$ ) (Table 1). No other significant differences were observed in terms of endoleak rate, graft migration, graft patency (Table 2), transfemoral and abdominal reinterventions, aneurysm rupture, graft infection and pseudoaneurysm formation.

Conclusions: AUI endografts performed quiet similar than BF endografts. Only differences in early and cumulative mortality were found. These findings support a safe behaviour of BF but their high use in poor medical patients penalize their outcome in terms of morality.

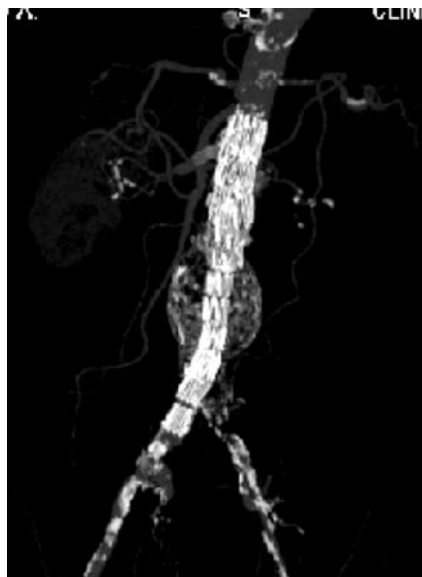


Table 1. All-cause mortality rates after EVAR for patients with bifurcated

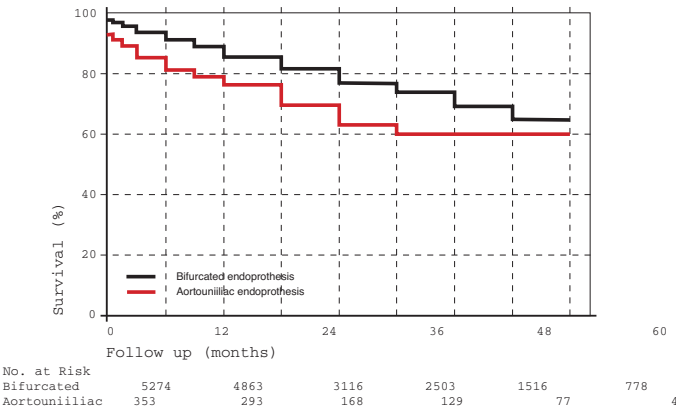
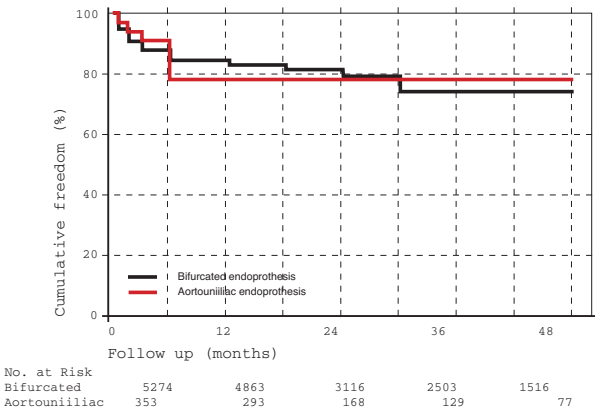


Table 2. Graft patency (freedom from thrombosis)



# THE VASCULAR INNOVATION ENDOGRAFT IS EFFECTIVE AND DURABLE EVEN IN HIGHLY COMPLEX ANATOMY AND CHALLENGING AAAs

Takao Ohki

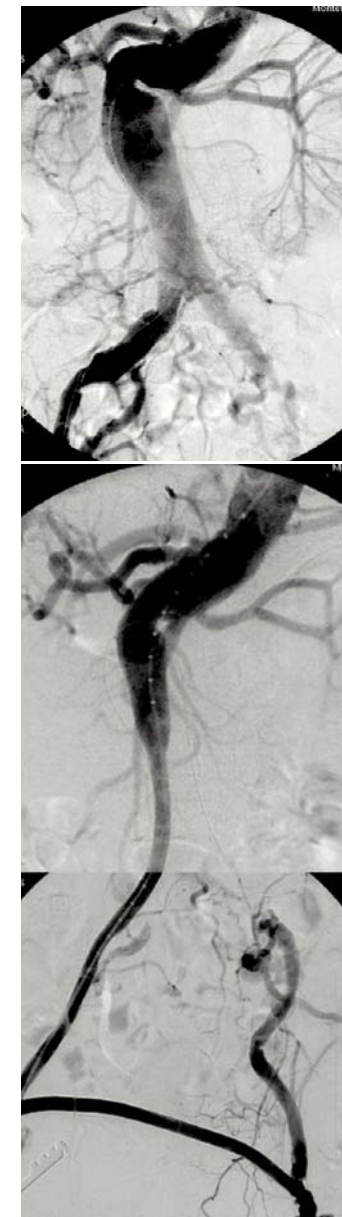Jikei University School of Medicine, Tokyo - Japan

**Objective:** Proximal neck dilatation (PND) and/or endograft migration with the subsequent development of type I endoleak is a significant cause of late endograft failure following endovascular aneurysm repair (EVAR). The occurrence of such failure is pronounced in difficult AAAs with adverse anatomy. While there are numerous reports examining PND in patients receiving endograft that utilize self-expanding stent (SES) for proximal fixation, there are no such reports for patients treated with endografts that use balloon-expanding stent (BES). The purpose of this study is to investigate PND and endograft migration following EVAR with BES endograft (Vascular Innovation Endograft, VIE) in patients that were not candidates for bifurcated SES endografts due to challenging anatomy.

**Methods:** We retrospectively reviewed all charts as well as all serial CT scans available of patients who underwent EVAR with a VIE (Aorto-uni-femoral PTFE graft with proximal Palmaz stent) between 1997 and 2002. Only patients with longer than 12 months follow up were analyzed. Neck diameter was measured at the level of the lowest renal artery and at 5 mm below it. PMD was defined as neck enlargement of  $>2.5$  mm. To assess endograft migration, the distance between the SMA and the cranial end of the VIE was measured. Stent migration was defined as a change of  $>5$  mm.

**Results:** A total of 77 patients received this device during the study period. The main reason why these patients were deemed untreatable with standard endografts was due to the presence of short and/or angulated proximal neck as well as diseased/small access vessels. The technical success rate was 99% despite challenging anatomy. One year, two years and three years survival was 62.8%, 53.8% and 38.4%, respectively. Complete serial CT scans were available in 41 of the 48 patients who survived 12 months or longer following the operation. The mean follow up period for these patients was 31 months (range from 12-66 months). The maximum aneurysm diameter was either unchanged or decreased in 35 patients (85%). The immediate post-op proximal neck diameter was 19-29 mm (median=24 mm). This was unchanged at the latest follow-up. None of the patients had significant PND. The cranial end of the VIE was located in the area between 14 mm proximal and 36 mm distal to the SMA (median of 6 mm). None of the patients developed significant endograft migration.

**Conclusions:** Neither PND or endograft migration were observed with the VIE despite challenging anatomy. The nature of the SESs may be responsible for the observed neck dilatation and device migration following EVAR with SES endografts. This study suggests that BES such as the VIE may be a better fixation method for EVAR.





# ENDOVASCULAR REPAIR OF RUPTURED AAA: HOW WE DO IT

**Jean-Pierre Becquemin**

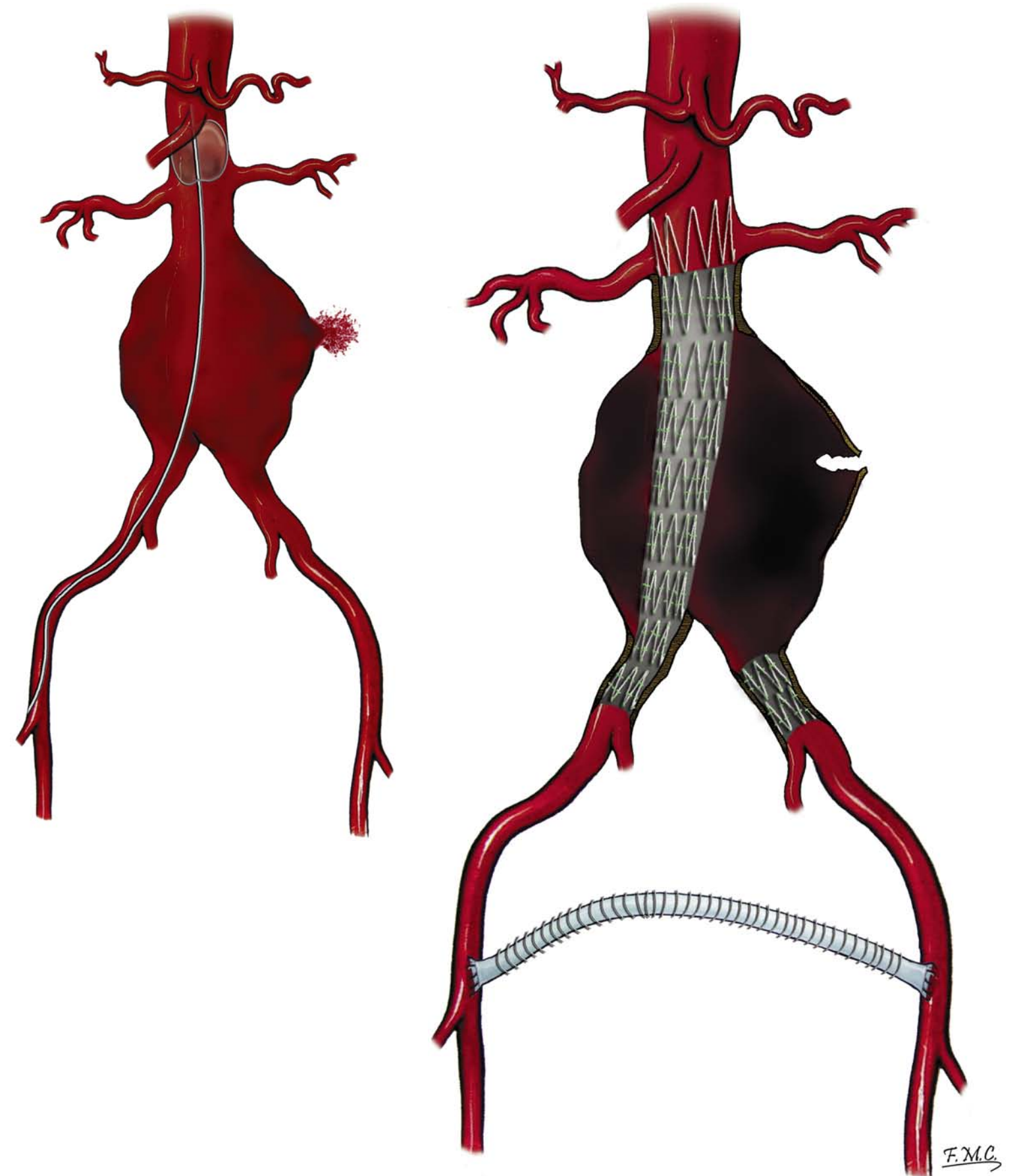
*Henri Mondor Hospital, APIHP Paris, University Paris XII, Creteil - France*

JP. Becquemin, P. Desgranges, E. Allaire, J. Marzelle, H. Kobeiter

We started the endovascular approach for ruptured aneurysms in 2001. Since then, the total mortality rate of ruptured aneurysm in our institution has declined for the first time during the last 25 years. Patients who received a stent-graft had 30 % mortality as compared to 60% in patients treated conventionally. Patients with suspected aneurysm rupture are collected by the emergent mobile medical unit ( SAMU). G-suits dress and lines are set up in the vehicle. Upon arrival at the hospital, abdominal Duplex-scan is performed in the resuscitation room and patient's haemodynamic parameters and his past history are assessed. Instable patients are placed in the OR for an arteriogram. Stable patients have a CT-scan. If the infra-renal neck is suitable then the stent graft will be placed right away. Short (< 1,5 mm) and severely angulated neck < 7 mm, heavy calcified and severely angulated external iliac arteries are rejected for an endovascular approach ( 50 %). We preferentially use aortouniliac graft to stop the bleeding as quickly as possible except in very favourable anatomical conditions where bifurcated grafts are chosen. We also avoid massive transfusion and we accept a relatively low blood pressure in order to avoid excessive intra-abdominal bleeding. If the patient is not too painful and restless we start the procedure under local anaesthesia. General anaesthesia is given once the aortouniliac graft is in place and the surgical team is ready to perform the femoro-femoral bypass. Horizontal groin incisions are performed on both sides. The control angio catheter is placed on the side contra lateral to the one chosen for the graft. Renal arteries are located and the graft is deployed the usual way. An occluder is placed in the contra lateral common iliac artery. Then the cross over femoro-femoral graft is performed. We generally place the graft subcutaneously. Great care is taken to avoid the coverage of the hypogastric artery. However when the aneurysm involves the common iliac artery the loss of the hypogastric artery is unavoidable. In case of haemodynamic instability, we place a balloon in the aorta above the renal arteries. From the groin a long introducer sheath is pushed on the stiff wire up to the renal arteries level. Then the balloon is properly placed and inflated. The sheath maintains the balloon in place which otherwise may drift into the aneurysm under the blood pressure. Once the graft is deployed the sheath allows the retrieval of the balloon.

Post-operatively vital parameters are surveyed the usual way. We use liberally intra bladder pressure measurement to detect as early as possible the development of a compartmental syndrome. When this happens, we evacuate the haematoma through a retroperitoneal incision. Colonoscopy is also performed at ease in case of persistence of abdominal pain, diarrhea, or lactate increases. A new Ct-scan is obtained routinely a few days following the intervention or earlier if needed to check the graft, the haematoma and to search for the persistence of leak.

In summary: endovascular repair of rupture aneurysm is a major technical improvement which disserves the attention of the whole vascular community. Experienced team with endovascular techniques is however mandatory.

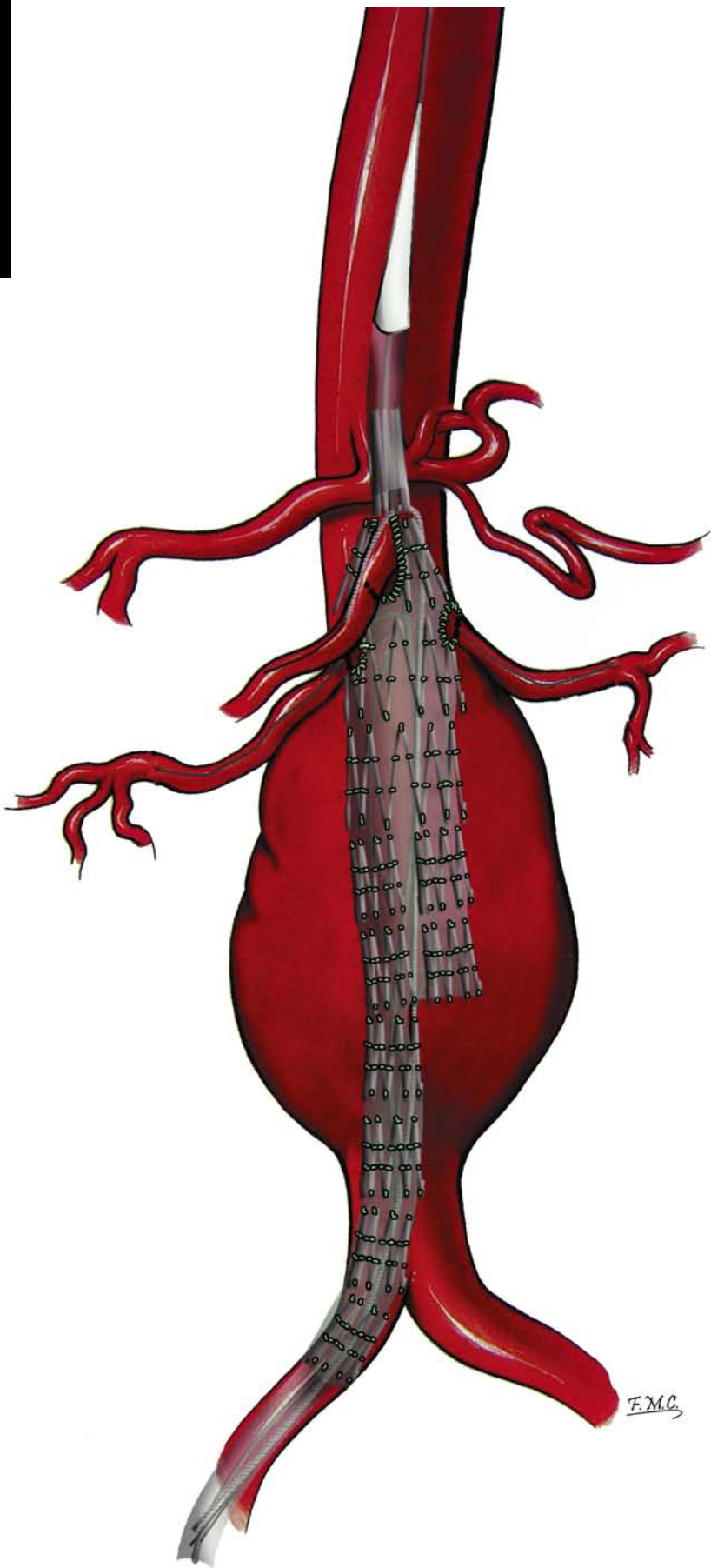
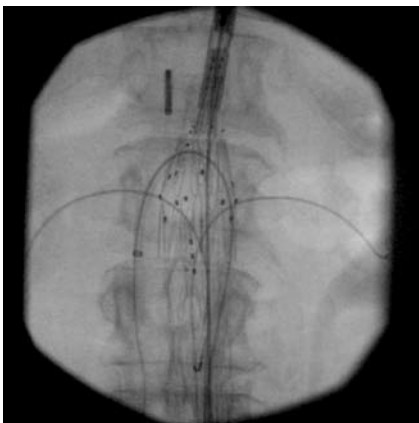


# FENESTRATED ENDOGRAFTS

**Richard McWilliams**  
*Royal Liverpool University Hospital - United Kingdom*

New challenges and new opportunities have accompanied the development of fenestrated endografts. Case selection and graft planning are key components of this new technology. Device deployment and adjunctive visceral artery stenting must be accurate and careful to secure immediate and longer term success. Post-operative surveillance demands attention to additional areas because of the increased modularity and visceral artery stents.

The purpose of this presentation is primarily to discuss and illustrate with video clips the steps involved in graft deployment. I will try to illustrate how decisions during deployment can influence the intermediate term outcome and how some problems can be anticipated and avoided.

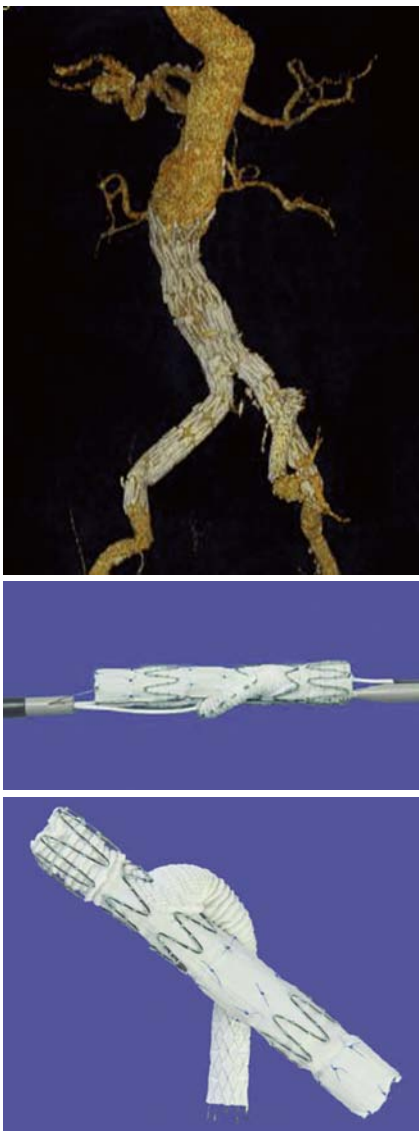




# ENDOVASCULAR TREATMENT OF AORTO-ILIAC ANEURYSMS WITH THE HELICAL BRANCH ENDOGRAFT

Stéphan Haulon  
Hôpital Cardiologique, CHRU de Lille - France

**Procedure description**  
Both common femoral arteries are exposed. The delivery system is advanced over a stiff wire into the iliac axis ipsilateral to the target internal iliac artery (IIA). The distal end of the branch (visualized by 3 longitudinal markers) is positioned medial and posterior, approximately 5mm above the internal iliac artery. The outer sheath of the delivery system is withdrawn to expose the branch limb, leaving the distal end constrained within the sheath in the external iliac artery. The preloaded wire is advanced into the distal aorta and snared from the contralateral femoral artery. This provides through-and-through access from the contralateral groin to the ipsilateral groin. A 10F or 11F sheath is advanced over this wire from the contralateral groin, over the aortic bifurcation, into the proximal segment of the device and finally into the helical sidebranch. An angled catheter (vertebral or cobra) is introduced into this sheath to selectively catheterize the internal iliac artery with a guidewire. The guidewire is then exchanged for a stiffer wire. The mating component (self expanding or balloon expandable stentgraft) is advanced over the stiff wire into the desired position. The mating device is oversized by 5-10% with respect to the target internal iliac artery. Once the mating graft is deployed and appropriately ballooned, the remainder of the external iliac limb is deployed. The component is then mated to the remainder of a Zenith graft with a specific extension.



# LATE ENDOVASCULAR REOPERATIONS AFTER EVAR FAILURE

**Piergiorgio Cao**

*University of Perugia - Italy*

G. Parlani, E. Cieri, G. Iacono, C. Coscarella, F. Verzini, P. Cao

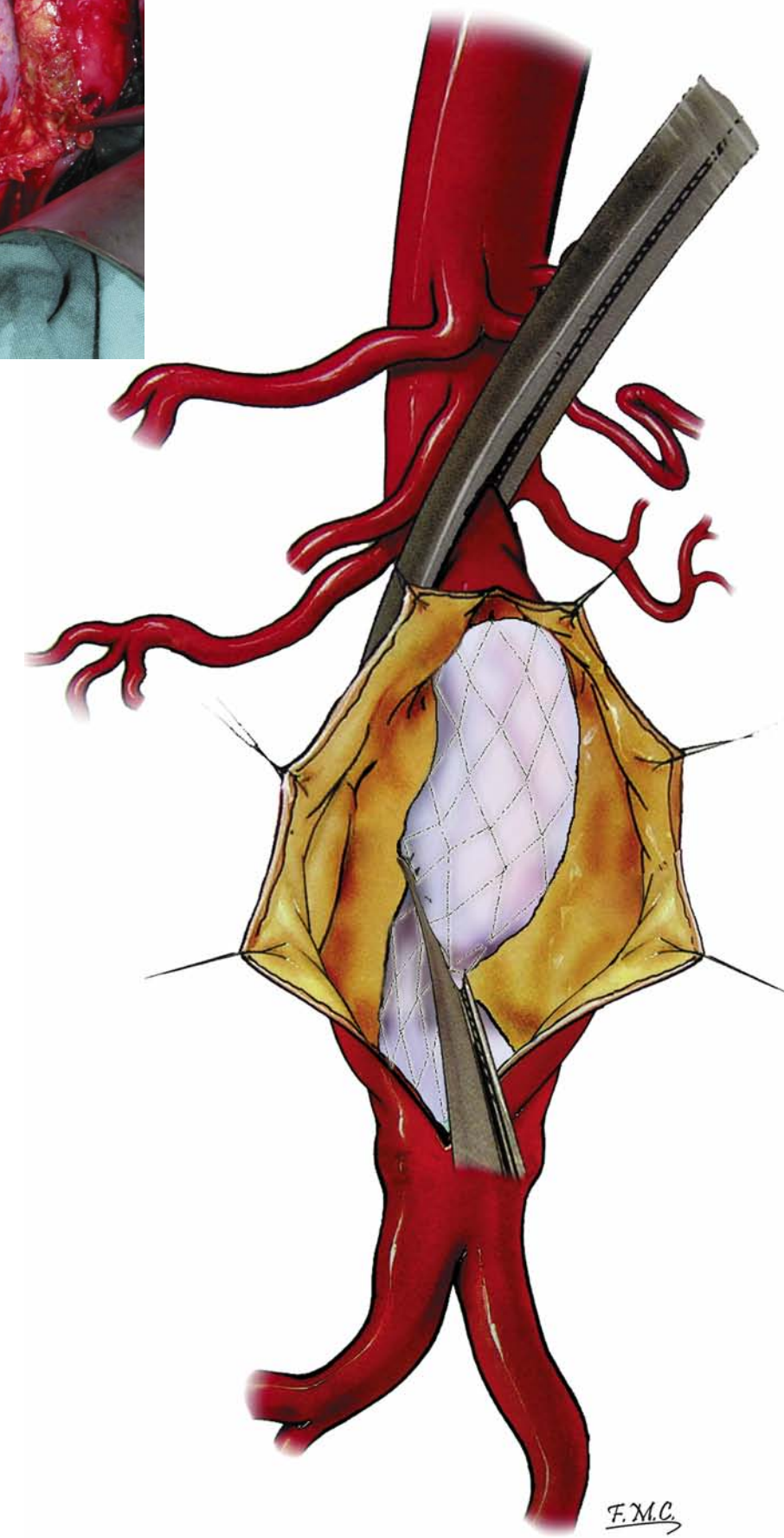
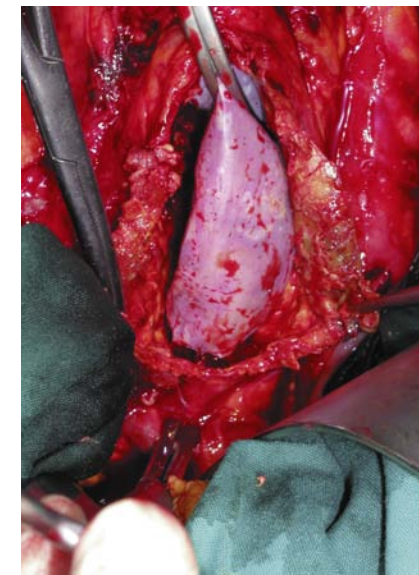
**Objective.** Randomized trials showed that EVAR compared to open repair provides similar results but with high rate of secondary procedures and reduced late effectiveness and durability. The present study examines how the need of reinterventions influences the prognosis of patients undergoing EVAR.

**Methods.** A 9-year single centre experience of 675 primary successful EVAR procedures with commercially available endograft was reviewed for the occurrence of reinterventions. All patients underwent Computed Tomography scan at 1 month, 1 year and annually thereafter. The data were prospectively collected on all the patients. The medium follow-up was 38 months (range 1-105). None of the patients were lost to follow-up. Reintervention was considered any secondary procedure either open or endovascular performed after successful EVAR. Reintervention failure was defined any need of subsequent reintervention, conversion to open repair, persistence of AAA growth after the secondary procedure, or AAA rupture.

**Results.** A total of 107 patients (16%) required one or more reintervention after EVAR for a variety of late problems, including AAA rupture (N=2), Type I endoleak (N=10), persistent aneurysm growth (N=30), graft migration (N=33), short landing zone (N=14) or vessel/branch occlusion (N=18). Overall, 24 conversions to open repair, 66 endovascular reinterventions (22 proximal cuffs, 20 distal cuffs, 2 catheter based embolizations, 5 sac embolizations, 2 iliac angioplasties, 1 renal stent and 14 AortoUniliac [AUI] + cross-over bypass) and 17 surgical procedures not involving endograft explantation (9 cross-over bypass, 2 splenorenal by-pass, 1 axillo-bifemoral bypass, 3 graft limb thrombectomies, and 1 limb amputation, 1 laparoscopic mesenteric clipping) were performed. Kaplan Meier estimates of 24, 48, 72 and 96 months freedom from reintervention were 90%, 77%, 64% and 54%, respectively.

Reinterventions were successful in 83% (89/107). At a mean follow-up of 26 months (range 1-70) after reintervention, 14 re-reinterventions were performed: 10 conversions to open repair and 2 AUI+ crossover bypass for persistent AAA growth were needed in patients who have undergone a previous catheter-based reintervention (9 proximal and 3 distal cuffs), one open graft limb in-situ replacement for infection after conversion to open repair and one Axillo-bifemoral bypass for occlusion of an AUI bypass. In addition, 1 AAA fatal rupture after proximal cuff disconnection with rapid AAA growth and 3 AAA persistent growth were recorded in patients with reinterventions. No perioperative mortality occurred in any of the secondary procedures.

**Conclusions.** Risk of reintervention after EVAR is high but this is associated with low periprocedural mortality and does not increase the overall aneurysm-related-mortality or the failure risk in the long term. In our 9-year experience of 675 EVAR, reinterventions were successful in 83% of patients; in 13% of these there was need for re-reintervention within 26 months of medium follow-up. Nevertheless, limited surgical reinterventions were usually successful in maintaining AAA exclusion and limiting AAA growth, while additional proximal graft extensions did not provide secure fixation in the long term.





# LATE OPEN CONVERSIONS AFTER EVAR FAILURE

**Dieter Raithel**

*Nuremberg Southern Hospital - Germany*

Between August 1994 and November 2005, we operated 1,128 patients with EVAR. We used 13 different devices.

The mortality was 0.4%. In total, we had 3.4% primary and 4.6% secondary conversions (n= 90). The conversion rate was drastically reduced in the last years, due to an improved technique and better devices available.

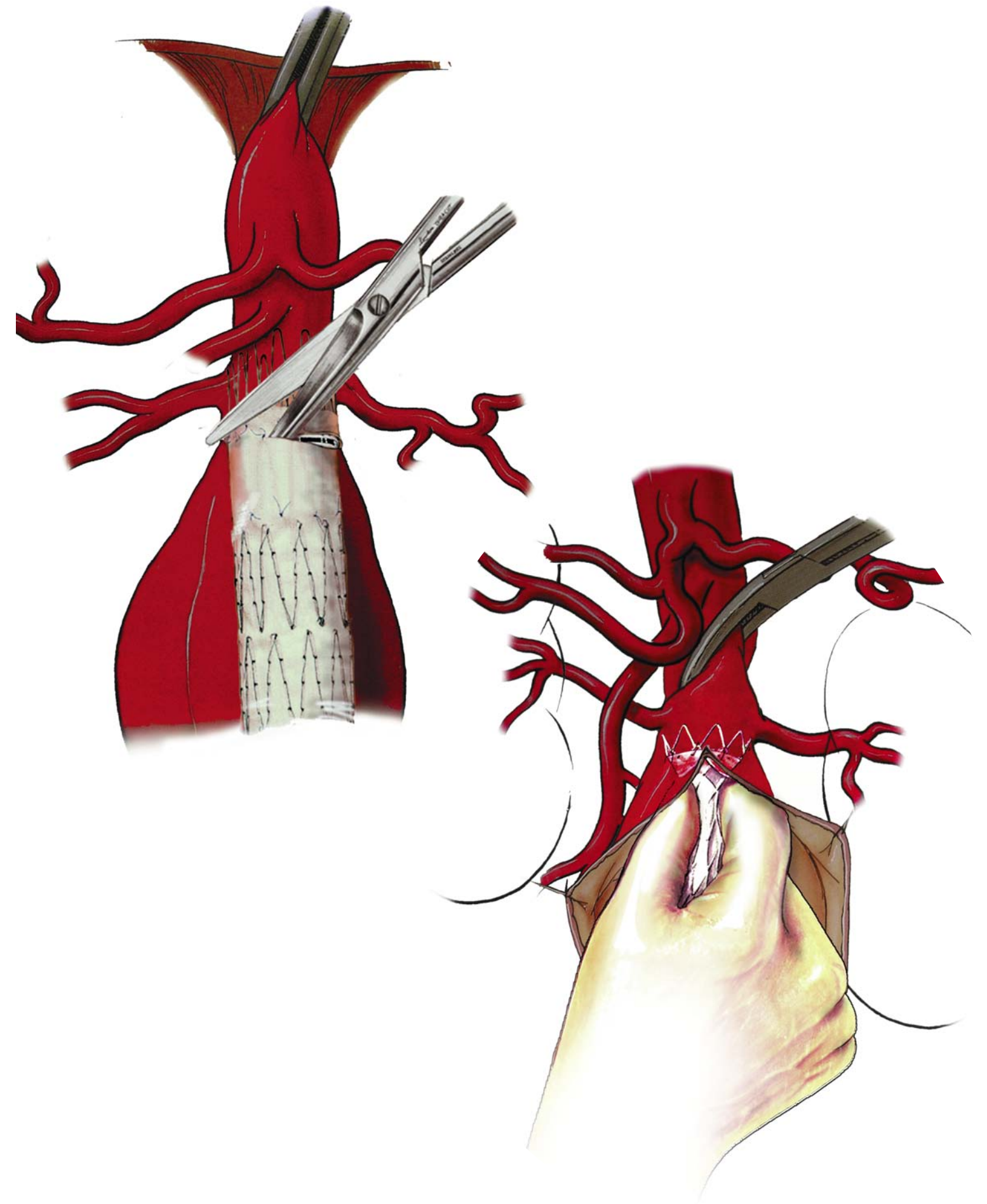
The conversion rate with bifurcated grafts was lower (6.1%). Especially unibody grafts had a very low conversion rate of 3.3%.

The technique of surgical conversion depends on the type and position of the stent-grafts. In grafts with transrenal fixation, a suprarenal clamping or, better, subdiaphragmal control of the aorta is important. Infrarenal clamping is only possible in grafts with distal migration and long neck and grafts without bare stents.

In nearly 77% , a tube graft after removal of the stent-graft was possible.

Of 90 conversions, the mortality in 13 emergency conversions was 14.4%, however we lost no patient in 49 elective conversions.

Morbidity and mortality can be kept at a low level by well-considered operative planning. We have achieved good results with conversions using the high proximal aortic clamping.





'06

## MEDICINE THROUGH TIME

by Prof. Angelo Argenterì



# AMBOISE PARÉ (1510 - 1590)

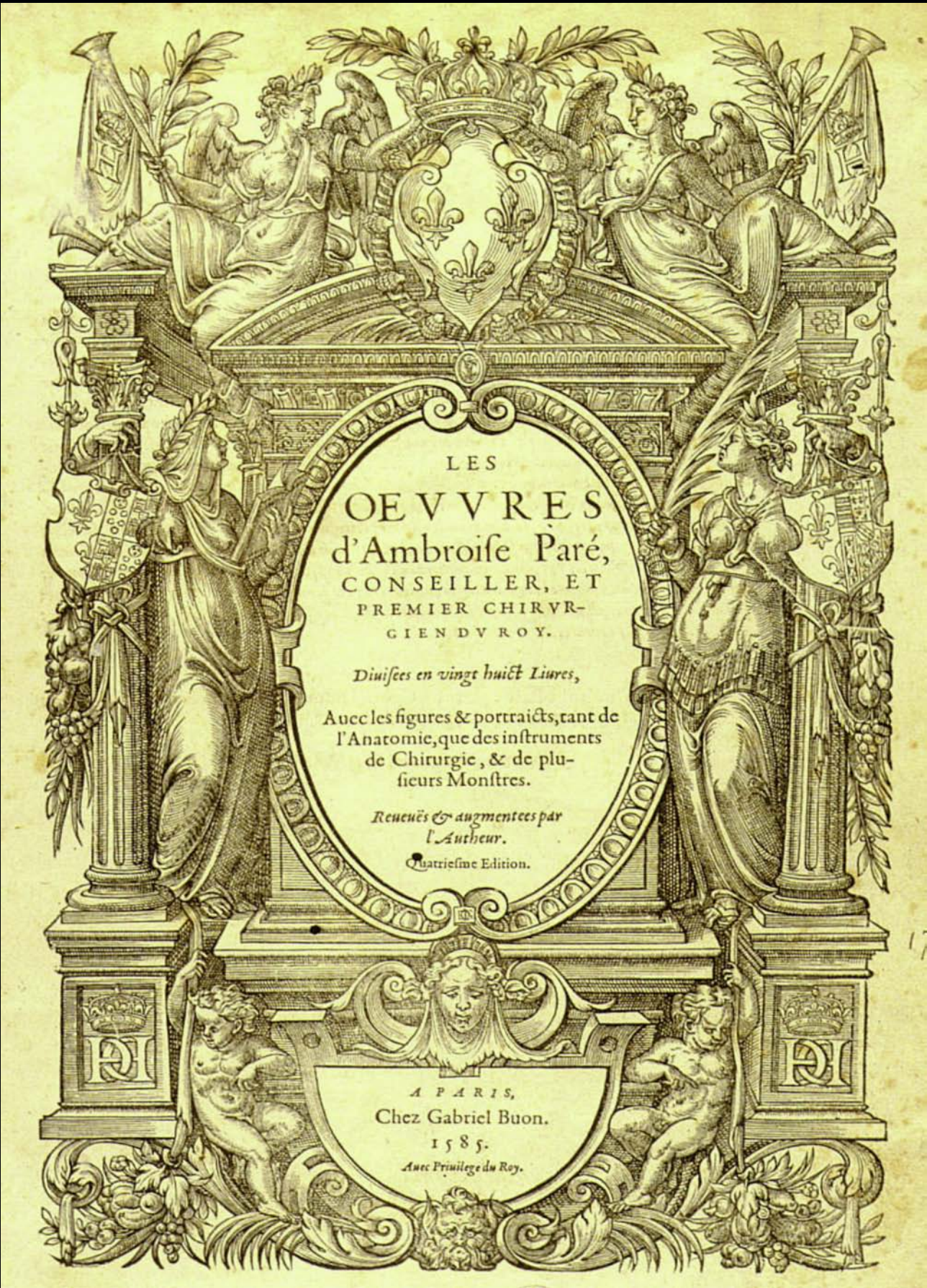


In 1552, Henry II of France moved with 40,000 men in order to free Metz: the French city that was in fact besieged by Charles V, Emperor of the sacred Roman Empire. A new deadly arm, named *baton à feu* (arquebuse), has recently made its appearance on the battlefield, and the besieged French soldiers are its victims. There is an urgent necessity to have an able surgeon and, to accomplish this, the French clandestinely infiltrate an excellent surgeon, Amboise Paré, into the city.

Paré immediately proves his ability and genius; a blow of an arquebuse has broken the leg of an official of the Count of Rhoan. Until that moment, the ligation of the femoral artery during an amputation of the limb was obtained by means of cauterization with a hot branding iron, with the imaginable consequences. Paré amputates the thigh, and to stop the flow of blood, uses a sturdy silk tourniquet for the first time. Destiny

makes fun of us; Amboise Paré is present to help the besieged French while another famous surgeon is brought in for the besiegers, Flemish born Andrea van Wesel (Vesalio) that, after the publication of his masterpiece, *De humanis corporis fabbrica*, left his chair of Surgery and Anatomy of Padova, preferring the comforts of the court. The two giants will meet again after a few years.

In 1559, Henry II of France must combat the power of the protestants within his reign; therefore he tries to align to his cause the catholic king, Philip II of Spain. In order to seal the alliance, he grants the hand of his daughter, princess Elisabeth, to the Spanish monarch. During the wedding festivities, Henry II wants to participate personally in the tournament: his turn comes and he charges the Duke of Montgomery, but the duke's lance, with a violent impact, pokes a hole in his helm disrupting his left eye. Chapelin, the royal physician, calls Paré to come immediately from Paris. While Emperor Philip II of Spain, recently become son-in-law of Henry II, urgently calls his personal doctor Vesalio from Spain. The two meet by the bed of the dying Henry II; at that moment, Paré reveals his intuitive genius. He asks Catherine de' Medici, wife of the king, that four men condemned to death be immediately executed and their bodies brought forthwith. Paré sharpens the point of a lance and plunges it into the eye of the first corpse trying to reproduce the mechanics of the lesion caused to the king. The attempt on the fourth corpse is judged to have produced a wound identical to that caused to the king. He thereby opens the skullcap and he examines the cerebral damage and concludes that the king's situation is a desperate one. In fact, Henry II dies after nine days





and it is Vesalio that performs the autopsy “... the left part of the skull was full of a liquid that seeped and seemed as it were necrotic gangrene... between the dura and the bone was clotted blood... the brain had pushed against the occipital bone and was crushed...”

Paré, the low ranking surgeon, became, as a result of his competence, the preferred surgeon of four kings of France; Henry II and his children, Francis II, Charles IX, and Henry III.

Paré can be identified as the stem cell of vascular surgery; besides having utilized the first type of ligation for amputations and designed artificial limbs for amputees, he described the pathology of aortic aneurysms based on infection with syphilis.

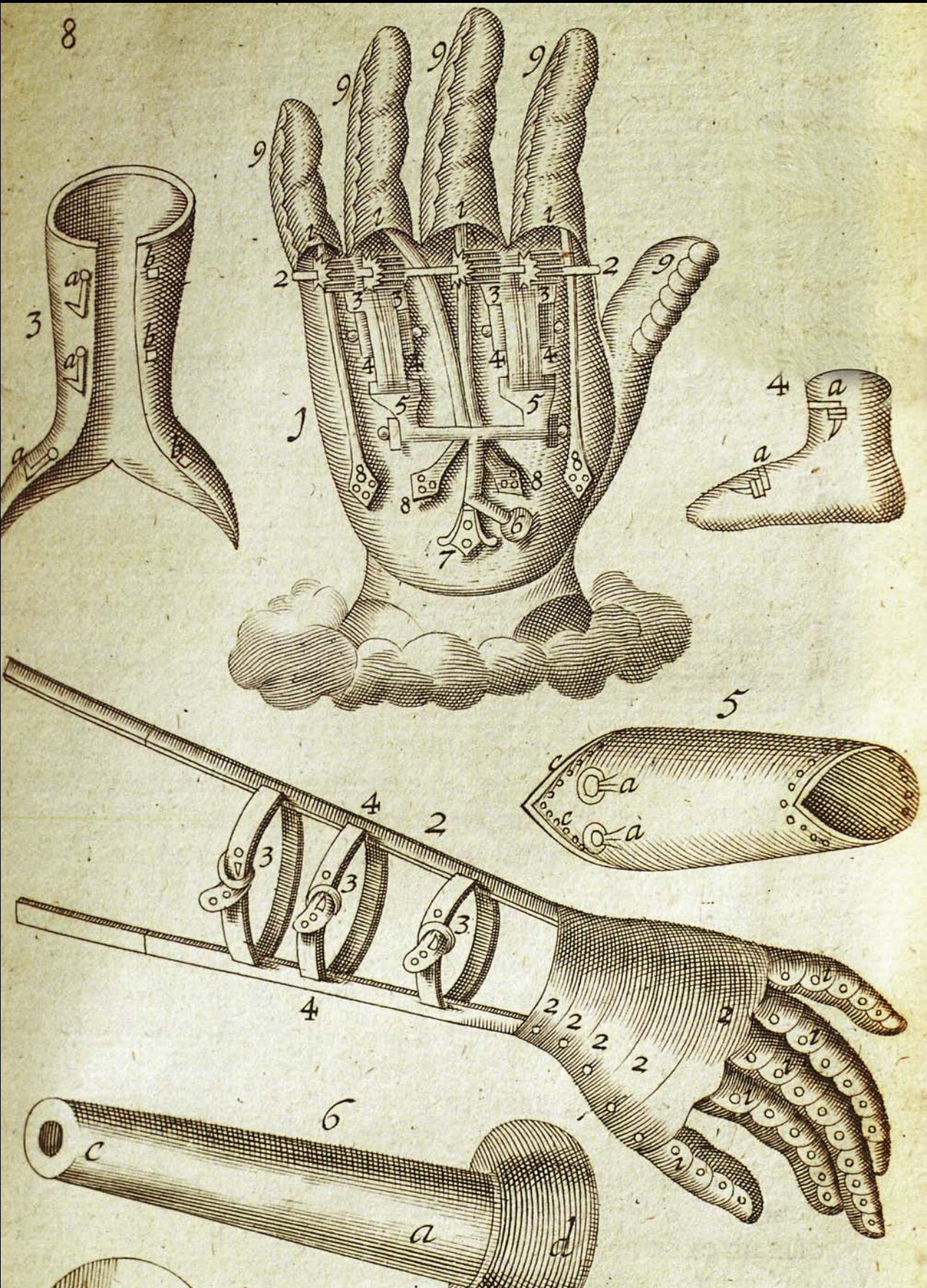
The disease of the moment for Paré was syphilis, coined *morbo gallicus* o *mal franzese*. Each nation, at the time, refused to be responsible for this disease and so, in naming it, passed on the legacy to others. To the French, it was the *mal de Naples*, for the Portuguese *morbus castillanus*, for the Dutch *vaiolus hispanicus*, and *morbus allemannus* for the Poles. The Turks, in a fundamentalist manner try to globalize the disease calling it *male cristiano*.

In 1530, Gerolamo Fracastoro (1478-1553) coined the term syphilis. The anatomist, Gabriele Falloppio (1523-1562) identified the transmission of the disease by *coitus cum femina impura* specifying four modes of transmission: *concubitu*, *cubatione*, *lactatione*, *suctione*.

At that time, the therapy of syphilis was based on infusions of guaiacum wood and mercury administered externally, or even better, by using its vapors. Patients

were immersed in liquid with only their heads emerging and exposed to mercurial vapors. The arrival of intense salivation, up to 1000-1500 ml a day, in addition to the stomatite caused by the mercury, signalled the efficacy of the therapy. Given the high frequency of aortic aneurysms in individuals with syphilis, one can put forward the theory that the appearance of aneurysms in these patients was not due to the syphilis infection but the result of exposure to the mercury vapors.

Paré gave the first description in 1572 in his *Livre des Apostèmes*. This book, like all of his writings, is in French and not in Latin as requested by his colleagues of the Brotherhood of Saint Cosmas in order to imitate academics, but Paré was not fluent in Latin and his renowned career allowed him to write: “Aneurysm involving the inner vessels are incurable, and frequently occur in those who have had the pox (syphilis) and have been subjected on several occasion to a sweat cure. As a result, the blood becomes greatly heated and subtilises, causing the contents of the artery to seek to escape, thus producing a dilatation of the artery, at times big as a fist. The reason why such aneurysm become great and their wall bony lies in the fact that the boiling hot blood first causes the tunic of the artery to dilate and to enlarge. Finally it ruptures, taking unto itself substance from the adjacent parts to reform its wall, and accordingly there is formed a large or small tumor, in proportion to the capacity of the region involved. Little by little, the wall of the tumor dry out and harden, like a vessel which has become cartilaginous, indeed bony, because of a material and efficient cause, just as stones are produced in the kidneys and bladder. For the peccant humor in the blood dries out and is solidified by extreme heat,





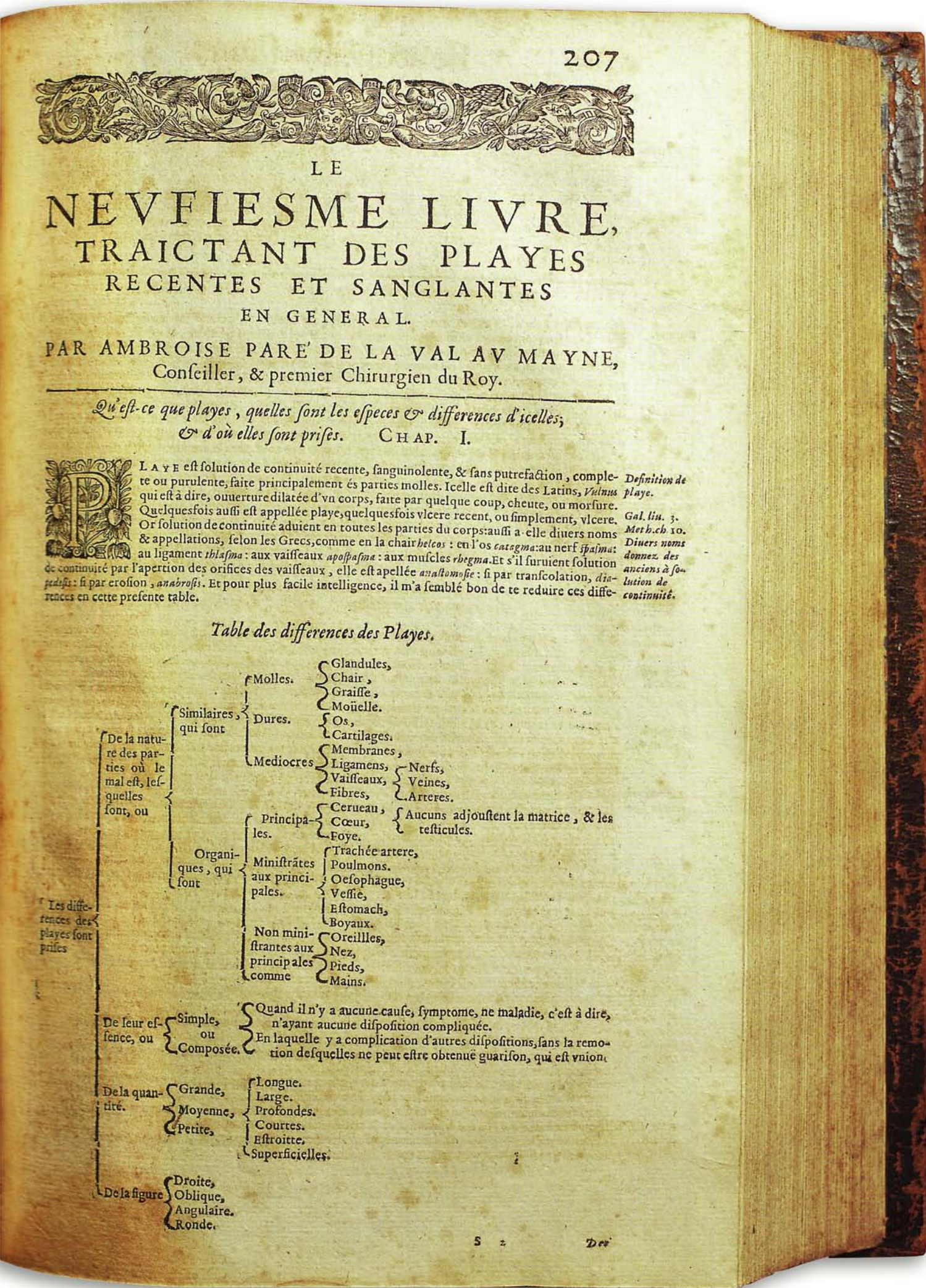
causing it to adhere to the tunic of the artery and the region involved. Thus it hardens and becomes bony. And that by God's great foresight aiming to construct a rampart, a strong barrier, lest the hot boiling blood, teeming in spirits, flow forth from the tunic of the artery, dilated into an aneurysm".

Paré has left us his description for the treatment of peripheral aneurysms by using a bandage compress infused with an astrigent liquid; in this way, one can determine if it is a cutaneous inflammation with the appearance of reactive tissue around the aneurysm that contrasts its expansion and rupture. Given this information, and given that the high frequency of wounds from cuts during combat points to false aneurysms caused by trauma: "I advised (the patient), as he valued his life, not to have it opened; but on the contrary to use the

ointment of bolo, and compresses dipped in the juice of mulberries and houseleeks mixed with fresh cheese, and other cooling and astringent things, and apply a plaster to prevent its rupture, with a thin platre of lesd, and to wear short sleeves, so that his pourpoint might serve as ligature to compress the tumor with. Also to avoid everything that might render the blood more liquid, and even to abstain from singing with too loud voice at St. André, as he was accustomed to do".

- Argenterì A.  
Il chirurgo dei quattro re di Francia  
Vascular Update 8: 7–12; 2000

- Malgaigne JF.  
Oeuvres complètes d'Amboise Paré  
Livre V: Des tumeurs en general. Cap. XXX: 371–5;  
Paris 1840





# GIOVANNI BATTISTA MORGAGNI

## (1682-1771)

“*Hic est locus ubi mors gaudet succurrere vitae*”. It is the phrase written on the walls of numerous autopsy rooms: from the observation of the diseased organ in *corpore vili* it is possible to understand the clinical picture of the disease *in vivo*. The process, customary for us, is a turn towards a new path on which the XVIII century medical culture walks. The author, the Forlì born Giovanni Battista Morgagni, worked as an anatomist at the Bologna University first, and subsequently at the Padova University.

Morgagni was part of a magical moment of medical history, full of comets and all from the same school: he was a student of Antonio Maria Fini (1666-1723) nicknamed Valsalva (from a small village near Imola), who himself was a student of Marcello Malpighi’s (1628-1694), was a teacher of Antonio Scarpa (1747-1832) who in turn was the teacher of Bartolomeo Panizza (1785-1867) and Luigi Porta (1800-1875). Morgagni developed a new approach to disease: the anatomical view of pathology in which symptoms are the externalization of a suffering body state. Morgagni synthesized in a figurative and effective way his new theory, “symptoms are the screams of suffering organs”. Clinical symptoms were, for the first time, tied to alterations of specific organs abandoning the prevalent foggy theory by which they were instead expressions of disequilibrium of humours. Pathological anatomy as a science was born. He began a new era of comprehension of pathological processes; Morgagni initiated the idea that disease was caused by pathological changes in organs, which later, the Frenchmen, Xavier Bichat and René Laennec, identified as changes in tissues, and later, German Rudolf Virchow, went even further by creating the study of cellular pathology. In 1761, Morgagni published his great work making pathological anatomy a science *De sedibus et causis*

*morborum per anatomen indagatis*. The treatise was arranged as seventy letters written to a virtual young student describing over 700 clinical cases and was subdivided into five books based on their content and dedicated to each of the medical societies with which Morgagni was affiliated. The first book regarding the diseases of the head was dedicated to the *Cesarea Accademia dei Curiosi*; the second, on the diseases of the chest to the Royal Society of London; the third, on the diseases of the stomach to the Royal Society of Science in France; the fourth, on pathologies of surgical interest to the Imperial Academy of Science in St. Petersburg; and the fifth, a supplement, was dedicated to the Royal Academy of Science in Berlin. Although the work was addressed mostly to physicians, Morgagni, in a novel way for that period, equipped it with four different indices; the first enumerates the symptoms by which the reader can then determine the pathology, the second gives autopsy data that can then determine symptoms associated with the disease, the third is a list of subjects, whereas the fourth lists cases worthy of notoriety. The cases described in the treatise were not all from the observations of Morgagni but, some, were part of the cases described by his teacher Valsalva. Morgagni explained that the expression, aneurysm, could be used to describe also ectasis, knowing that ectasis really couldn’t be labelled as aneurysms but he did so in respect of his teacher, “He (Valsalva) called this disease aneurysm, and I too shall use this term together with dilatation out of my respect for a man who has shed more light and doctrine on aneurysm than anyone else”. *De sedibus* is a goldmine for vascular surgeons; there are numerous cases of aortic aneurysms and they are symbolic cases. Morgagni, himself, dwelt on the necessity to discuss this pathology, “Now I must speak of the aneurysm inside





the chest that with their size compress the lungs, disturb the flow of blood through the lungs and often burgen the diaphragm with their weight, so that in many guises they produce respiratory lesions. The main ones are those of the heart and the aorta".

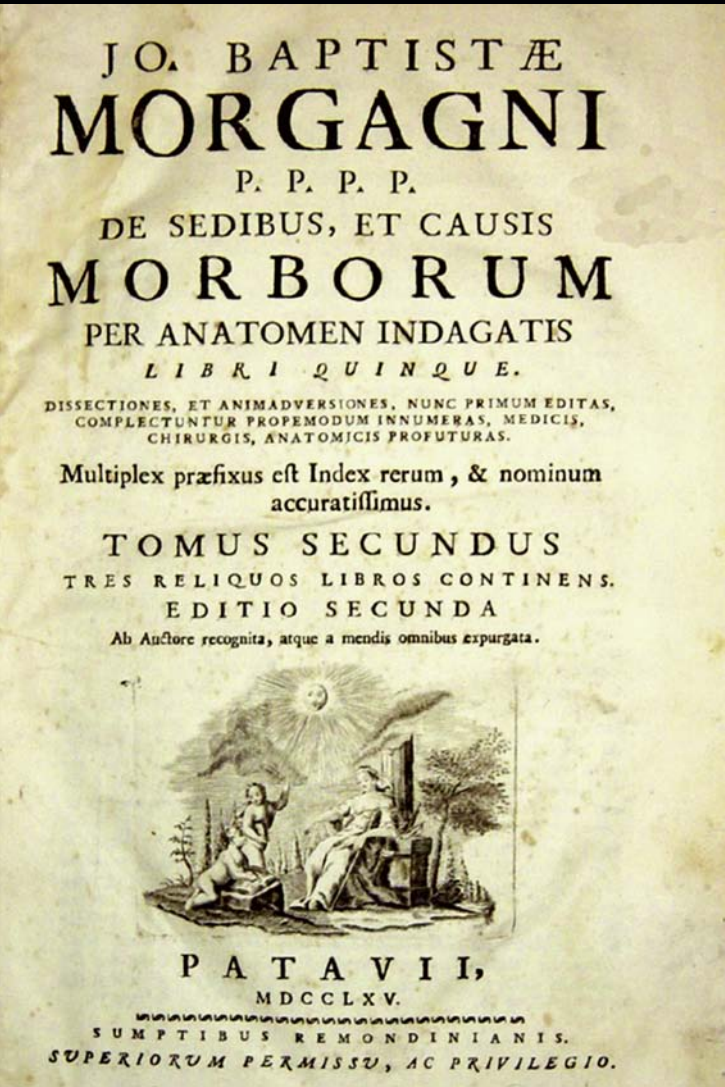
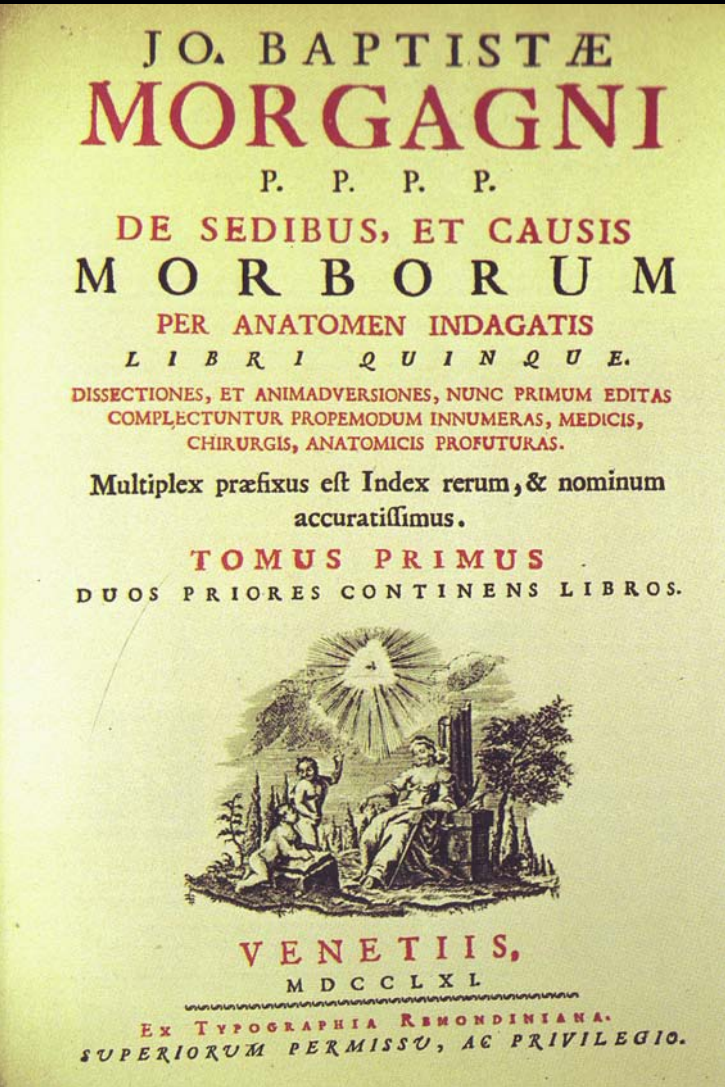
An aneurysm, during its fissuration stage, is described in the second book; "A man of about 50 years of age began to complain of difficulty in breathing that was only possible in gasps. He experienced sudden episodes of pressure in the precordial region, with lack of breath followed by severe pains in the flanks. The neck arteries pulsed furiously. Then, after producing bloody sputum several days before dying, he passed away in the throes of heavily disturbed breathing". Describing the autopsy, "The aorta, near the heart, dilated like an aneurysm, with the wall covered here and there by bony plaques".

In another autopsy case, he describes the compression of the thoracic duct by an abdominal-thoracic aneurysm, "The aorta, along the entire segment extending from the heart to the diaphragm was dilated in the form of an enormous aneurysm. Because the chyliiferous vessels originated principally in the intestines held within a space of about two arms or cubits, starting from a point 8 finger under the pylorus, and because they occupied the centre of the mesenterium, this intestinal extension was covered with whitish patches, which, according to the expression of Valsalva, had small irregular cavities, different in shape and size, so that some resembled a lens, while others were twice the size, and still others even smaller. Although he could not make sense of these small cavities, the chyliiferous vessels. He thought, communicated with the others, so that they were full of chyle, which he sampled and reported to taste like milk, except that its taste was salty. Therefore, he suspected that the small cavities were not so apparent, if for no other reason than the thoracic duct, compressed by

such a great aneurysm of the pectoral aorta, left a much too narrow space for the chyle, so that this humor was forced to stop its course through the walls of the intestine and to dilate the small vessels in the form of varices or to open in similar fashion small reservoirs that are less visible in their natural state".

Another case from the second book describes the eruption to the outside of the body after erosion of the ribs from an aneurysm of the ascending aorta. This case was described by Valsalva in 1704 at the *Ospedale degli Incurabili* of Bologna and it was treated with binding the chest to prevent its expansion, "...blood began to appear at a point of the chest, so that the skin seemed about to burst since it was so thin, while the man was completely unaware of the danger he ran. Then he began to remove his bandages to show us his wound. But on seeing the thing, he was impeded from continuing and ordered to stay still and consider solemnly his imminent departure from this mortal life, now inevitable (sic) which occurred the following day due to profuse bleeding that was announced by not expected. Nonetheless, the patient had the presence of mind, as soon as he heard the blood begin to gurgle, not only to present his soul to God but also to take a bowl from the side of the bed, as if collecting blood from another person, and place it under his own opened wound, while a caregiver ran to assist him and take him in his arm, where he died shortly there after".

The observations that Morgagni made of aortic aneurysms permitted him to develop a natural history of this pathology even in patients that were asymptomatic in which the absence of symptoms results in the underestimation of the high probability of morbidity or mortality, "...and the danger not imminent would lead the patient to be misled by a disease he does not notice; but he will change his mind when the situation will have reached a point where it

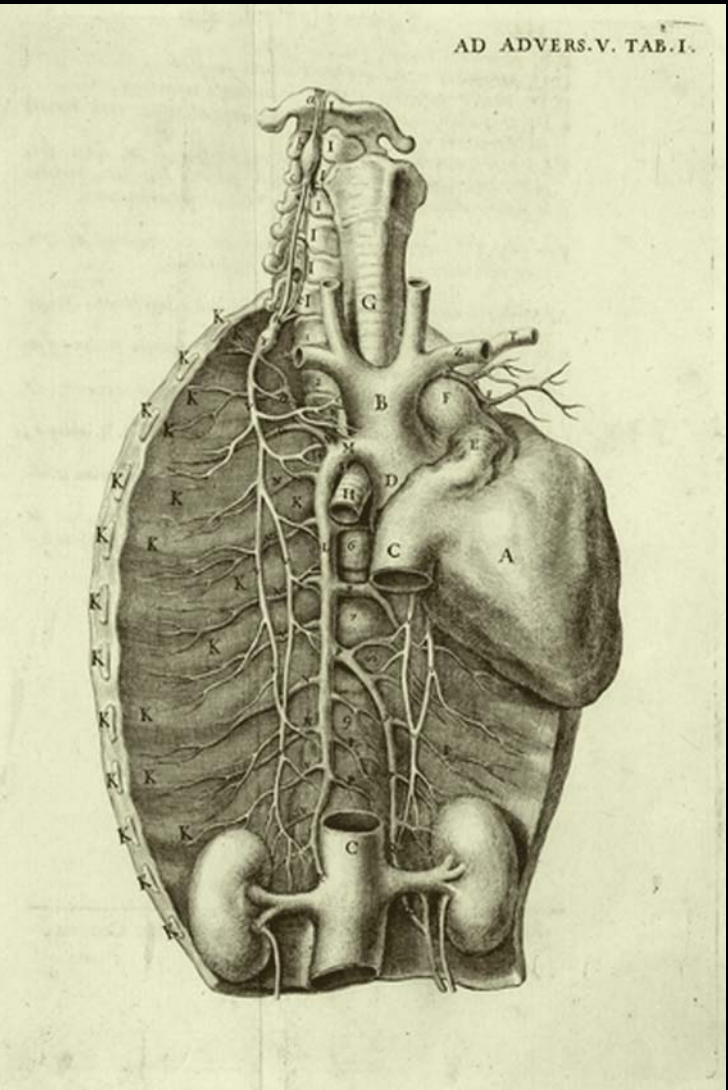
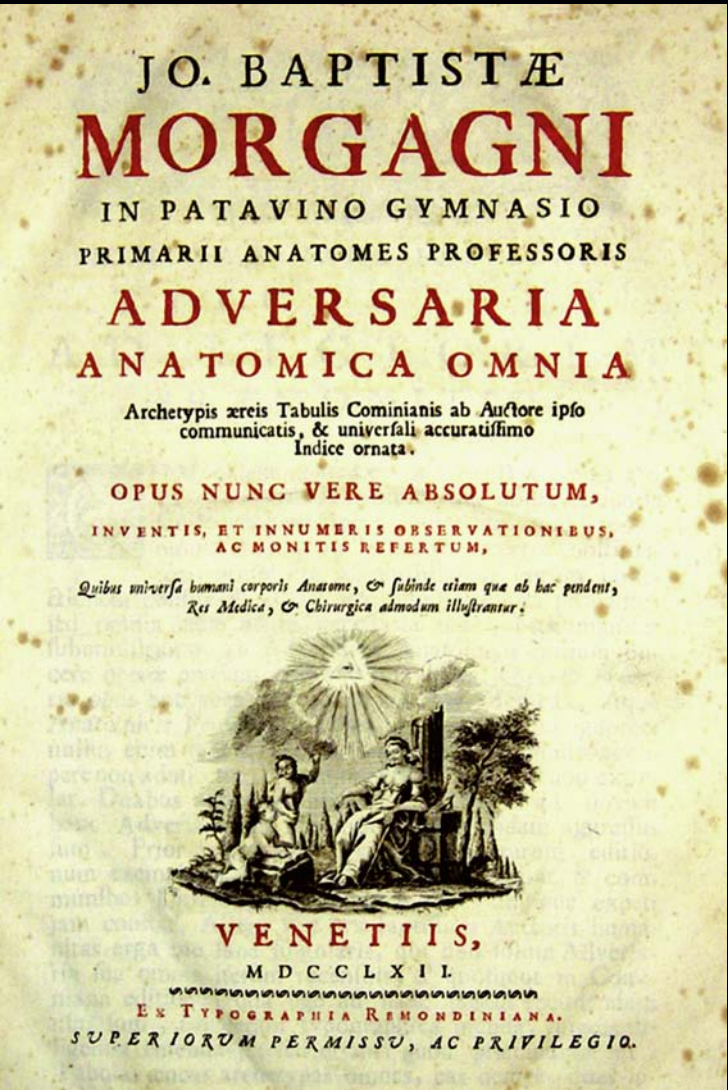




cannot be avoided by any other means, severe and permanence disturbances, or death itself that will constantly threaten his very existence". Morgagni is ahead of his time in describing the difference between fusiform and sacciform aneurysms, "Neither do I doubt that you (the young student the letter is addressed to) would forget that I have divided aneurysms into those with an equal dilation of a vessel in all of its parts and in those that grow like a sac on one side of the vessel...". In another case, Morgagni, through an autopsy, explains the patient's symptoms as a consequence of a thoracic aneurysm compressing the oesophagus, the upper airways and the venous flow: "The artery filated slightly above to form a sac that constituted the tumor, where it was said to be, and impairing the surrounding areas, produced almost all those phenomena of morbidity that can be observed during life. In fact, it compressed the asperartery (trachea) and the larynx, which emanated a very strong voice; the narrowed esophagous and pharynx presented a passage of food that was difficult a first and impeded in the end; lastly, the compression of the major trunk of the jugular vein, the internal jugular vein, impeded the return flow of blood from the upper parts, thus producing redness, pain and slight delirium". In the end, he arrives at a description of a rupture of a dissecting aneurysm of the ascending aorta: "The blood gradually opened a way for one of those spaces (solution of continuity of the intima) and occurred under the external tunica of the artery, which had initially detached, and raised it from the internal tunicae, and then also stretched it until, having ruptured it in one place, extravasated into the pericardium". His observations on thoracic aneurysms in patients affected by syphilis permitted him to confirm the contagious cause of vascular lesions in patients with syphilis; "I have no

doubt that the erosive bodies (reference to the Fracastoria theory of syphilis) which disturb the mind of individuals affected with venereal syphilis do not infrequently stop at the membranes of the arteries, and weaken and corrode them here and there, thus leading to dilatuions, and I certainly have frequently found many erosive manifestation on the tunicae of the aorta". Finally, here is a picturesque autopsy report describing the rupture of a dissecting aneurysm with hemopericardium likely secondary to syphilis or Marfan syndrome in a twenty-eight years old woman: "A strumpet of eight-and-twenty years of age, of a lean habit, having complained for some months, and particularly for the last fifteen days of a certain lassitude and loathing of food, and almost of everything, for this reason made lees use of other aliments and more unmixed wine; to the use of which she had been always too much addicted. A certain debauchee having gone into the house to her, and after a little time having come out, with a confused and disturbed countenance, and she not having appeared for two or three hours later, the neighbours, who had observed these things, entering found her not only dead but cold; lying in bed with such a posture of body, that it could not be doubted what business she had been about when she died, especially as the semen virile was seen to have flowed from the organs of generation".

- **Argenteri A., De Amicis P, Curci R.**  
Aneurismi toraco addominali. Un percorso storico  
G. Ital. Chir. Vasc. 9; 1 - 46: 2002
- **Morgagni G.B.**  
De sedibus et causis morborum per anatomen indagatis. 1761  
Traslated by Benjamin Alexander London 1769
- **Nuland SB.**  
Doctors, the biography of medicine.  
A. Knopf New York 1988 Cap. VI






# THÉOPHILE RENÉ MARIE HYACINTHE LAENNEC (1781-1826)

One of the emblems most often seen in medicine, often inflated as a logo in every medical environment, is the stethoscope. For students of medicine, it becomes the point of arrival as a tangible sign, to flaunt as a member of a sect. The stethoscope’s inventor was a small Briton, Théophile René Marie Hyacinthe Laennec. He arrived in Paris to go to the school of mythical Jean Nicolas Corvisart de Marets (1755-1821) at the Hospital of Charity in *rue des St. Pères*. The hospital was founded by Marie de’ Medici and it was one of the centres of medical culture of the time. Corvisart was one of the major European clinicians of that time, a supporter of a clinically-oriented approach to disease, and was also Emperor Napoleon Bonaparte’s primary physician. He opened the door to semiotic percussion. In 1808 he published *Nouvelle méthode pour reconnaître les maladies internes de la poitrine par percussion de cette cavité*. The intuition was not his, and Corvisart admits it. Leopold Auenbrugger (1722-1809) had published in 1761 a manual where he referred to percussion as a new semiotic manoeuvre without having the support of the medical profession of the time. Auenbrugger had an exceptional ear for music; he was also the author of a book of the music of Salieri (rival of Mozart). From watching his father, who was a brewer, that percussed the casks to determine if the beer was of a good quality, he applied this maneuver to the thoracic semiotic. Corvisart translated the book from Latin to French and began to introduce the technique described almost fifty years previously. Laennec grew in this progressive and stimulating environment. He became friends with Marie François


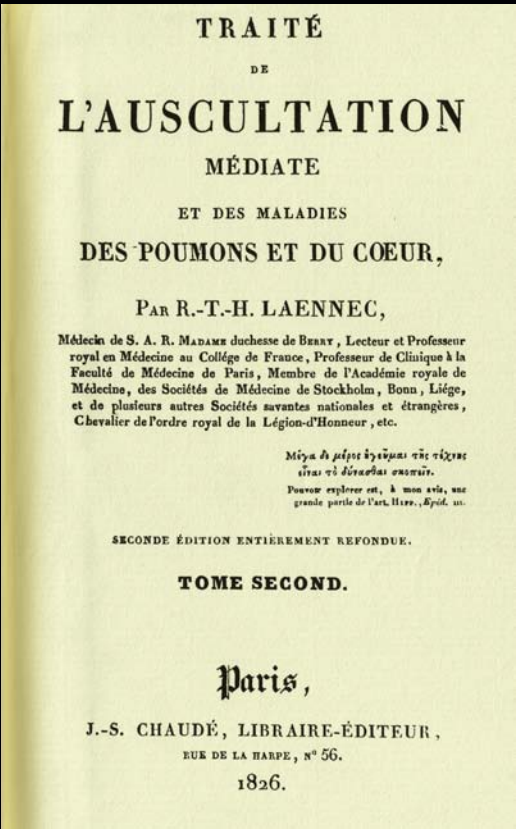
Xavier Bichat (1771-1802), who was dedicating himself to the study of tissue transplant of organs with the description of the function of the peritoneum and the pleurae. It was during this period that Laennec coined the term *kirros* (brown) to define the colour of the liver in alcoholics; from this term came the name of the subsequent disease, cirrhosis. After his degree, he moved to Salpêtrière for a brief period and then to Necker, considered among the most peripheral and less prestigious hospitals. During this period, on September 13, 1816, he had an intuition, as he himself describes, “I was consulted by a young woman with general symptoms of a cardiac disturbance and, in this case, percussion and application of the hands were of little help because of her being obese. Given the fact that, because of the age and sex of the patient, it was not permitted to apply one’s ear directly to the anterior part of the chest, I thought a simple, acoustical instrument could be used in this circumstance. I believed that the amplification of sound is transported through a solid body, such as when one applies their ear to a block of wood where you can hear the crackle of a nail in the other side. Immediately, I rolled up a piece of paper into a cylinder... and was amazed and surprised to discover that I could perceive the heart beat even more clearly than listening just with my ear. At this point, I imagined that this method could be used, not only for the beating of the heart, but of any sort of sound produced by the movement of any internal organ”. Laennec sought out a good wood craftsman, who made the instrument from wood and he baptizes it





as a stethoscope, from the Greek *sthetos* (anterior part of the thorax) and *skopeo* (to observe). Informally, Laennec calls it a *baton or cylindre*. His observations of clinical cases with the use of the stethoscope are innumerable; he was helped by the fact that he was an optimal flautist with an expert ear to recognize every variation in timbre and tone. The cases studied and verified by autopsy were many, and in 1819 he published the fruit of his experience with the treatise, *De l'auscultation médiate et des maladies des poumons et du coeur*. The work, in two volumes with about 800 pages each, was sold with a stethoscope included for three francs extra. Reading the case histories in the book still leaves one marvelling at the precision of the descriptions and the intuition shown by Laennec. The first volume of the book is dedicated to cases involving pathologies of the lung, while the second deals with cardiac cases and pathology of large vessels. From page 680 of the second volume, the book details vascular pathologies, *Exploration des organes de la circulation*. Laennec subdivided and described aortic and carotid murmurs in chapter XXV (*Affections organiques de l'aorte*) by way of utilizing a musical pentagram (he was a proven musician). An exemplary description is given of the dissection of an atheromatic plaque, "...often bony, cartilaginous, and calcified incrustations detach along their circumference following the rupture of the internal tunica. This tearing, which seems to be the most common cause of consecutive false aneurysm, produces below the incrustation a small cavity that fills with fibrin, a decomposed substance with the consistency of friable paste, sometimes mixed with

calcium phosphates. This material has been identified by the name of atheromatous material". The same chapter describes congenital defects of the aorta, reporting a case, observed by Corvisart, of an aortic occlusion in a fourteen years old, "The aorta was obliterated half an inch under the subclavian and extended for several lines; the circulation flowed through the arterial canal that could admits only a catheter, and the anastomoses of the intercostal and mammary arteries were very dilated". Chapter XXVI is dedicated to aortic aneurysms treated from various aspects: *Caractères anatomiques des anevrysmes de l'aorte*, *Des concretions du sang dans les sacs anevrysmatiques*, *Des effects des anevrysmes de l'aorte sur les organes voisins*, *Des signes des anevrysmes de l'aorte*. Laennec defines an aneurysm as "a dilatation of an artery or its communication by a more or less wide opening, with a sort of sac formed usually at the external tunica and sometimes at the adjacent organs. The first case constitutes what the surgeons call a true aneurysm, while the latter is defined a false or consecutive aneurysm". His description of thoracic aneurysms is still very current and was proved by ample clinical and autopsy experience by Laennec: "The dilation often extend from the origin of the aorta to the start of the descending thoracic aorta, and the point of maximum dilation is usually within this space. In some cases the convexity of the curve and the anterior aspect of the vessel seem to be more dilated than the internal wall. When the dilation is located at a point in the descending aorta, it





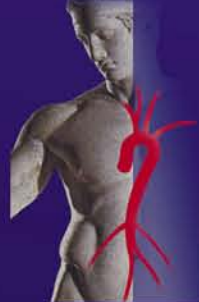presents with the aspect of an oval or fusiform tumor, and its upper and lower parts (proximal and distal) show a progressively smaller dilation as they approach the healthy portions of the aorta. It is not rare to find various dilations on the same course of the aorta. When the dilation is located at the brachiocephalic or the celiac trunk, the origin of these vessels evidently is involved in this dilation. The left subclavian artery, in contrast, maintains almost always its natural caliber, also in the larger aneurysm, without doubt because of the acute angle with which its joins the aorta. The entire dilation extend along entire aorta. It is not rare to find subjects of normal size in which the aorta presents from the saddle to the division of the primary iliac arteries a diameter twice the normal size". Laennec believed that the formation of an aneurysm is not ascribed in a simplistic manner to the "violent pulsation of blood in the vessels" but that it was necessary for the aorta weakened by alterations in the wall. In fact, he disproved the theory of Guillame Dupuytren (1777-1835), the surgeon of the time, who deceived by the smooth aspect within the cavity of thoracic aneurysms, believed that, "the internal membrane (intima) herniated through the rupture of the tunica media and covered the entire surface of the sac, whose external part is constituted of the external tunica". Dupuytren purports the theory as his own, but a Swiss, Albrecht Haller (1708-1777), had elaborated something similar speaking of "aneurysma erniosum" Laennec agreed with the theory of Antonio Scarpa (1747-1832) that supported the necessity of a lesion in the three tunicae for the formation of an aneurysm: "In his excellent work on

aneurysm, Scarpa advances the hypothesis that there is no aneurysm without rupture of the internal and middle tunica and that the sac is formed solely of cellulose (adventitia)". He also describes in an exact manner a dissecting aneurysm, "The descending aorta at about 2 inches from its origin presented at the internal aspects a transversal tear occupying 2 third of its circumference and involving only the intima and the media. The borders of this tear were irregular and gaping. The external tunica was healthy and detached from the media of this tear to the origin of the primary iliac arteries in such a manner that at first glance it appeared that the aorta was divided by a median septum. The detachment was not complete, and it occupied only 2 thirds or the half of the surface of the arterial cylinder and rotated around the cylinder, occupying mainly the posterior aspect. It extended to the celiac trunk and the primary iliac arteries and rose up to the aortic saddle. This detachment formed a sort of oblong sac...the sac was crossed at various points by intercostal and mediatic arteries". Among the complications of thoracic aneurysms, he describes the rupture with the formation of a tracheal aorta fistula with "sudden fatal hemoptisis" and three cases of esophageal aortic fistula with "death by vomiting of blood". He reported four cases of rupture of the pericardium, a case regarding the pulmonary artery and an exceptional case of the rupture of the thoracic duct with "blockage of all the milk vessels". Laennec also identified the mechanical effects of aneurysms of the descending aorta: he described a case of rupture of the rachidian canal, "announced



on the field by the paralysis of the lower extremities and followed by death one day later". In the part dedicated to clinical diagnosis, Laennec underlines the necessity to have early diagnosis: the chapter begins with a phrase that is at the base of diagnosis of the following century, "few disease are as insidious as aneurysm of the aorta. They are recognized only when they manifest outwardly".

- Argenterì A.  
La patologia aortica nell'opera di R.T.H. Laennec  
Giornale Italiano Chirurgia Vascolare vol. 6; 3: 139 - 43; 1999
- Laennec R.T.H.  
Traité de l'auscultation médiate et des maladies des poumons et du cœur.  
Tome second, Chaudé JS Paris 1826 pag. 688 - 728



'06

The Scientific Board of the International Congress Aortic Surgery  
"How to do it" II gratefully acknowledge the following companies  
for their partnership.

- ALBERTO ASPESI & C.
- COLNAGO ERNESTO & C.
- PORSCHE ITALIA
- TEAM GIMOTORSPORTS UNIONBIKE MV AUGUSTA
- TRESOLDI CONCESSIONARIO HONDA
- UNILEVER PRO-ACTIV
- YAMAHA

The Scientific Board of the International Congress Aortic Surgery  
"How to do it" II would like to thank the following companies for  
their generous and continuing support.

- AB MEDICA
- ABBOTT
- B. BRAUN MILANO
- BAXTER
- BOEHRINGER-INGELHEIM
- BOLTON MEDICAL
- BOSTON SCIENTIFIC
- CEA
- COOK MEDICAL
- DISTREX
- EDWARDS LIFESCIENCES ITALIA
- INNOVATIVE MEDICAL TECHNOLOGIES
- INTERVASCULAR A DATASCOPE COMPANY
- JOHNSON & JOHNSON MEDICAL
- MEDTRONIC ITALIA
- SEDA
- SEROM MEDICAL TECHNOLOGY
- SIMAD MEDICAL TECHNOLOGY
- SORIN GROUP
- ST. JUDE MEDICAL
- TYCO HEALTHCARE ITALIA
- VASCUTEK, a TERUMO Company
- W.L. GORE & ASSOCIATI